

**NCCN Clinical Practice Guidelines in Oncology (NCCN Guidelines®)**

# **Anal Carcinoma**

Version 2.2016

**NCCN.org**

**Continue**



National  
Comprehensive  
Cancer  
Network®

# NCCN Guidelines Version 2.2016 Panel Members

## Anal Carcinoma

[NCCN Guidelines Index](#)  
[Anal Carcinoma Table of Contents](#)  
[Discussion](#)

\* **Al B. Benson, III, MD/Chair †**  
Robert H. Lurie Comprehensive Cancer  
Center of Northwestern University

\* **Alan P. Venook, MD/Vice-Chair † ‡**  
UCSF Helen Diller Family  
Comprehensive Cancer Center

**Tanios Bekaii-Saab, MD †**  
The Ohio State University Comprehensive  
Cancer Center - James Cancer Hospital  
and Solove Research Institute

**Emily Chan, MD, PhD †**  
Vanderbilt-Ingram Cancer Center

**Yi-Jen Chen, MD, PhD §**  
City of Hope Comprehensive  
Cancer Center

**Harry S. Cooper, MD ≠**  
Fox Chase Cancer Center

**Paul F. Engstrom, MD †**  
Fox Chase Cancer Center

**Peter C. Enzinger, MD †**  
Dana-Farber/Brigham and Women's  
Cancer Center

**Moon J. Fenton, MD, PhD †**  
St. Jude Children's Research Hospital/  
University of Tennessee Health Science  
Center

**Charles S. Fuchs, MD, MPH †**  
Dana-Farber/Brigham and Women's  
Cancer Center

**Jean L. Grem, MD †**  
Fred & Pamela Buffett Cancer Center

**Axel Grothey, MD †**  
Mayo Clinic Cancer Center

**Howard S. Hochster, MD**  
Yale Cancer Center/Smilow Cancer Hospital

**Steven Hunt, MD †**  
Siteman Cancer Center at Barnes-  
Jewish Hospital and Washington  
University School of Medicine

**Ahmed Kamel, MD ϕ**  
University of Alabama at Birmingham  
Comprehensive Cancer Center

**Natalie Kirilcuk, MD †**  
Stanford Cancer Institute

**Smitha Krishnamurthi, MD † ρ**  
Case Comprehensive Cancer Center/  
University Hospitals Seidman  
Cancer Center and Cleveland  
Clinic Taussig Cancer Institute

**Lucille A. Leong, MD †**  
City of Hope Comprehensive  
Cancer Center

**Edward Lin, MD †**  
Fred Hutchinson Cancer Research Center/  
Seattle Cancer Care Alliance

**Wells A. Messersmith, MD †**  
University of Colorado Cancer Center

**Mary F. Mulcahy, MD ‡ †**  
Robert H. Lurie Comprehensive Cancer  
Center of Northwestern University

**James D. Murphy, MD, MS §**  
UC San Diego Moores Cancer Center

**Steven Nurkin, MD, MS †**  
Roswell Park Cancer Institute

**David P. Ryan, MD †**  
Massachusetts General Hospital  
Cancer Center

\* **Leonard Saltz, MD † ‡ ρ**  
Memorial Sloan Kettering Cancer Center

**Sunil Sharma, MD †**  
Huntsman Cancer Institute  
at the University of Utah

**John M. Skibber, MD †**  
The University of Texas  
MD Anderson Cancer Center

**Constantinos T. Sofocleous, MD, PhD ϕ**  
Memorial Sloan Kettering Cancer Center

**Elena M. Stoffel, MD, MPH ≠**  
University of Michigan  
Comprehensive Cancer Center

**Eden Stotsky-Himelfarb, BSN, RN ¥**  
The Sidney Kimmel Comprehensive  
Cancer Center at Johns Hopkins

**Christopher G. Willett, MD §**  
Duke Cancer Institute

**NCCN**  
**Deborah Freedman-Cass, PhD**  
**Kristina M. Gregory, RN, MSN, OCN**

**Continue**

† Medical oncology	ρ Internal medicine
§ Radiotherapy/Radiation oncology	ϕ Diagnostic/Interventional radiology
† Surgery/Surgical oncology	≠ Gastroenterology
≠ Pathology	¥ Patient advocate
‡ Hematology/Hematology oncology	*Discussion Section Writing Committee

[NCCN Guidelines Panel Disclosures](#)



### [NCCN Anal Carcinoma Panel Members](#)

### [Summary of the Guidelines Updates](#)

### [Workup and Treatment - Anal Canal Cancer \(ANAL-1\)](#)

### [Workup and Treatment - Anal Margin Lesion \(ANAL-2\)](#)

### [Follow-up Therapy and Surveillance \(ANAL-3\)](#)

### [Principles of Chemotherapy \(ANAL-A\)](#)

### [Principles of Radiation Therapy \(ANAL-B\)](#)

### [Staging \(ST-1\)](#)

**Clinical Trials:** NCCN believes that the best management for any cancer patient is in a clinical trial. Participation in clinical trials is especially encouraged.

To find clinical trials online at NCCN Member Institutions, [click here: nccn.org/clinical\\_trials/physician.html](#).

**NCCN Categories of Evidence and Consensus:** All recommendations are category 2A unless otherwise specified.

See [NCCN Categories of Evidence and Consensus](#).

The NCCN Guidelines® are a statement of evidence and consensus of the authors regarding their views of currently accepted approaches to treatment. Any clinician seeking to apply or consult the NCCN Guidelines is expected to use independent medical judgment in the context of individual clinical circumstances to determine any patient's care or treatment. The National Comprehensive Cancer Network® (NCCN®) makes no representations or warranties of any kind regarding their content, use or application and disclaims any responsibility for their application or use in any way. The NCCN Guidelines are copyrighted by National Comprehensive Cancer Network®. All rights reserved. The NCCN Guidelines and the illustrations herein may not be reproduced in any form without the express written permission of NCCN. ©2016.



# NCCN Guidelines Version 2.2016 Updates

## Anal Carcinoma

Updates in Version 2.2016 of the NCCN Guidelines for Anal Carcinoma from Version 1.2016 include:

**[MS-1](#)** - The discussion section was updated to reflect the changes in the algorithm.

Updates in Version 1.2016 of the NCCN Guidelines for Anal Carcinoma from Version 2.2015 include:

### **[ANAL-1](#)**

- Workup; bullet 2, sub-bullet 1 modified: “*Consider* biopsy or FNA if suspicious nodes.”
- Workup; bullet 3 modified: “Chest/abdominal/~~pelvic~~ CT ~~or~~ + *pelvic* CT or MRI”
- Workup; bullet 3, sub-bullet 1 modified: “Consider PET scan for ~~T2-4, N0 or Any T, N+~~”
- Footnote “c” added: “CT should be with IV and oral contrast. Pelvic MRI with contrast.” (also applies to ANAL-2)
- Clinical Stage: T and N categories combined to “locoregional” disease.

### **[ANAL-2](#)**

- Workup; bullet 2, sub-bullet 1 modified: “*Consider* biopsy or FNA if suspicious nodes.”
- Workup; bullet 3 modified: “Chest/abdominal/~~pelvic~~ CT ~~or~~ + *pelvic* CT or MRI”
- Workup; bullet 3, sub-bullet 1 modified: “Consider PET scan for ~~T2-4, N0 or Any T, N+~~”

### **[ANAL-3](#)**

- Surveillance: Anoscopy schedule changed from every 3–6 mo for 5 y to every 6–12 mo x 3 y

### **[ANAL-B](#)**

- Bullet 6 modified: “For T2 lesions ~~with residual disease after 45 Gy~~, T3/4 lesions, or N1 lesions, an additional boost of 9–14 Gy in 1.8–2 Gy fractions to the original primary tumor volume and involved nodes plus a 2–2.5 cm margin is usually delivered.”
- Bullet 7 modified: “The consensus of the panel is that intensity-modulated radiation therapy (IMRT) ~~may be used in place of~~ *is preferred over* 3-D conformal RT in the treatment of anal carcinoma. IMRT requires expertise and careful target design to avoid reduction in local control by so-called ‘marginal-miss.’ The clinical target volumes for anal cancer used in the RTOG-0529 trial have been described in detail. *The outcome results of RTOG-0529 have been reported.*”
- Reference added: “Kachnic LA, Winter K, Myerson RJ, et al. RTOG 0529: a phase 2 evaluation of dose-painted intensity modulated radiation therapy in combination with 5-fluorouracil and mitomycin-C for the reduction of acute morbidity in carcinoma of the anal canal. *Int J Radiat Oncol Biol Phys* 2013;86:27-33.”



# NCCN Guidelines Version 2.2016

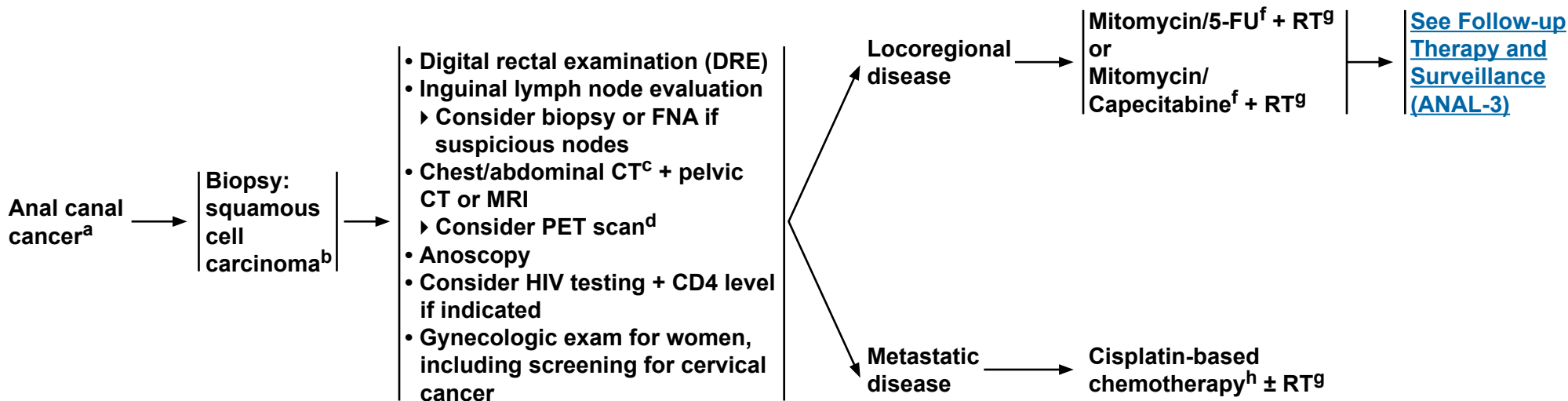
## Anal Carcinoma

### CLINICAL PRESENTATION

### WORKUP

### CLINICAL STAGE

### PRIMARY TREATMENT<sup>e</sup>



<sup>a</sup>The superior border of the functional anal canal, separating it from the rectum, has been defined as the palpable upper border of the anal sphincter and puborectalis muscles of the anorectal ring. It is approximately 3 to 5 cm in length, and its inferior border starts at the anal verge, the lowermost edge of the sphincter muscles, corresponding to the introitus of the anal orifice.

<sup>b</sup>For melanoma histology, see the [NCCN Guidelines for Melanoma](#); for adenocarcinoma, see the [NCCN Guidelines for Rectal Cancer](#).

<sup>c</sup>CT should be with IV and oral contrast. Pelvic MRI with contrast.

<sup>d</sup>PET-CT scan does not replace a diagnostic CT. The routine use of a PET-CT scan for staging or treatment planning has not been validated.

<sup>e</sup>Patients with anal cancer as the first manifestation of HIV may be treated with the same regimen as non-HIV patients. Patients with active HIV/AIDS-related complications or a history of complications (eg, malignancies, opportunistic infections) may not tolerate full-dose therapy or may not tolerate mitomycin and require dosage adjustment or treatment without mitomycin.

<sup>f</sup>[See Principles of Chemotherapy \(ANAL-A\)](#).

<sup>g</sup>[See Principles of Radiation Therapy \(ANAL-B\)](#).

<sup>h</sup>Cisplatin/5-FU is recommended for metastatic disease. If this regimen fails, no other regimens have been shown to be effective. [See Principles of Chemotherapy \(ANAL-A\)](#). Local control can be achieved with the use of RT.

**Note:** All recommendations are category 2A unless otherwise indicated.

**Clinical Trials:** NCCN believes that the best management of any cancer patient is in a clinical trial. Participation in clinical trials is especially encouraged.





# NCCN Guidelines Version 2.2016

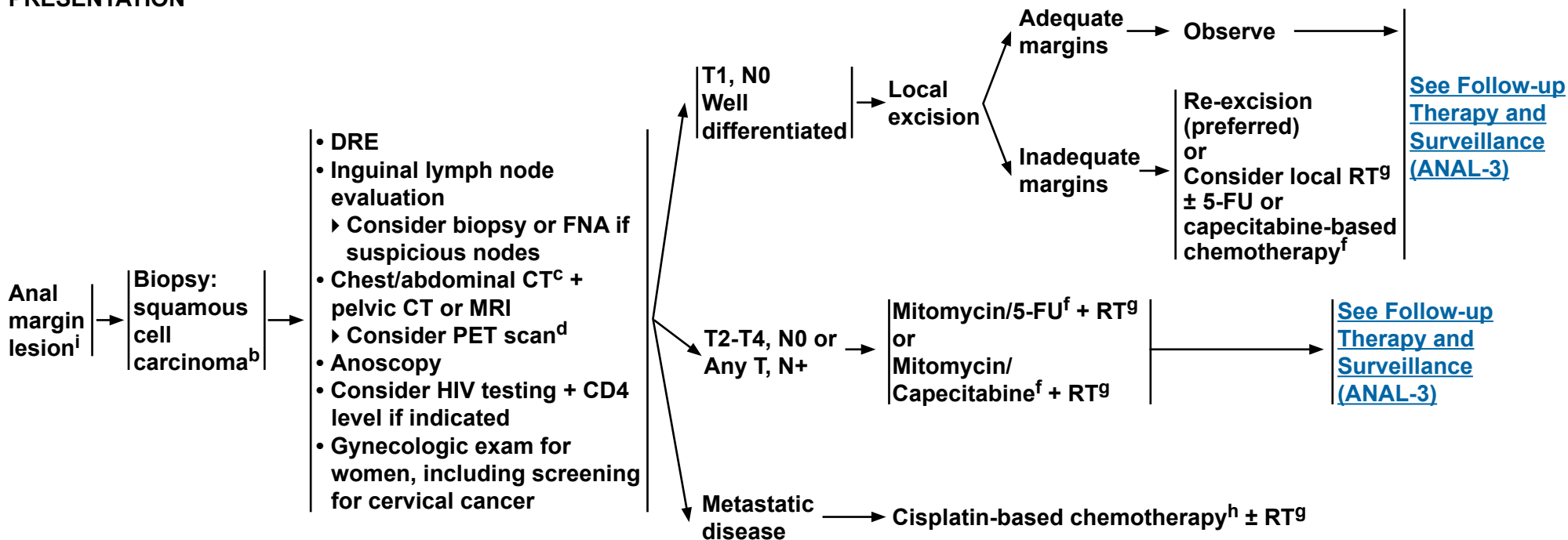
## Anal Carcinoma

### CLINICAL PRESENTATION

### WORKUP

### CLINICAL STAGE

### PRIMARY TREATMENT<sup>e</sup>



<sup>b</sup>For melanoma histology, see the [NCCN Guidelines for Melanoma](#); for adenocarcinoma, see the [NCCN Guidelines for Rectal Cancer](#).

<sup>c</sup>CT should be with IV and oral contrast. Pelvic MRI with contrast.

<sup>d</sup>PET-CT scan does not replace a diagnostic CT. The routine use of a PET-CT scan for staging or treatment planning has not been validated.

<sup>e</sup>Patients with anal cancer as the first manifestation of HIV may be treated with the same regimen as non-HIV patients. Patients with active HIV/AIDS-related complications or a history of complications (eg, malignancies, opportunistic infections) may not tolerate full-dose therapy or may not tolerate mitomycin and require dosage adjustment or treatment without mitomycin.

<sup>f</sup>[See Principles of Chemotherapy \(ANAL-A\)](#).

<sup>g</sup>[See Principles of Radiation Therapy \(ANAL-B\)](#).

<sup>h</sup>Cisplatin/5-FU is recommended for metastatic disease. If this regimen fails, no other regimens have been shown to be effective.

<sup>i</sup>[See Principles of Chemotherapy \(ANAL-A\)](#). Local control can be achieved with the use of RT.

<sup>j</sup>The anal margin starts at the anal verge and includes the perianal skin over a 5- to 6-cm radius from the squamous mucocutaneous junction.

**Note:** All recommendations are category 2A unless otherwise indicated.

**Clinical Trials:** NCCN believes that the best management of any cancer patient is in a clinical trial. Participation in clinical trials is especially encouraged.



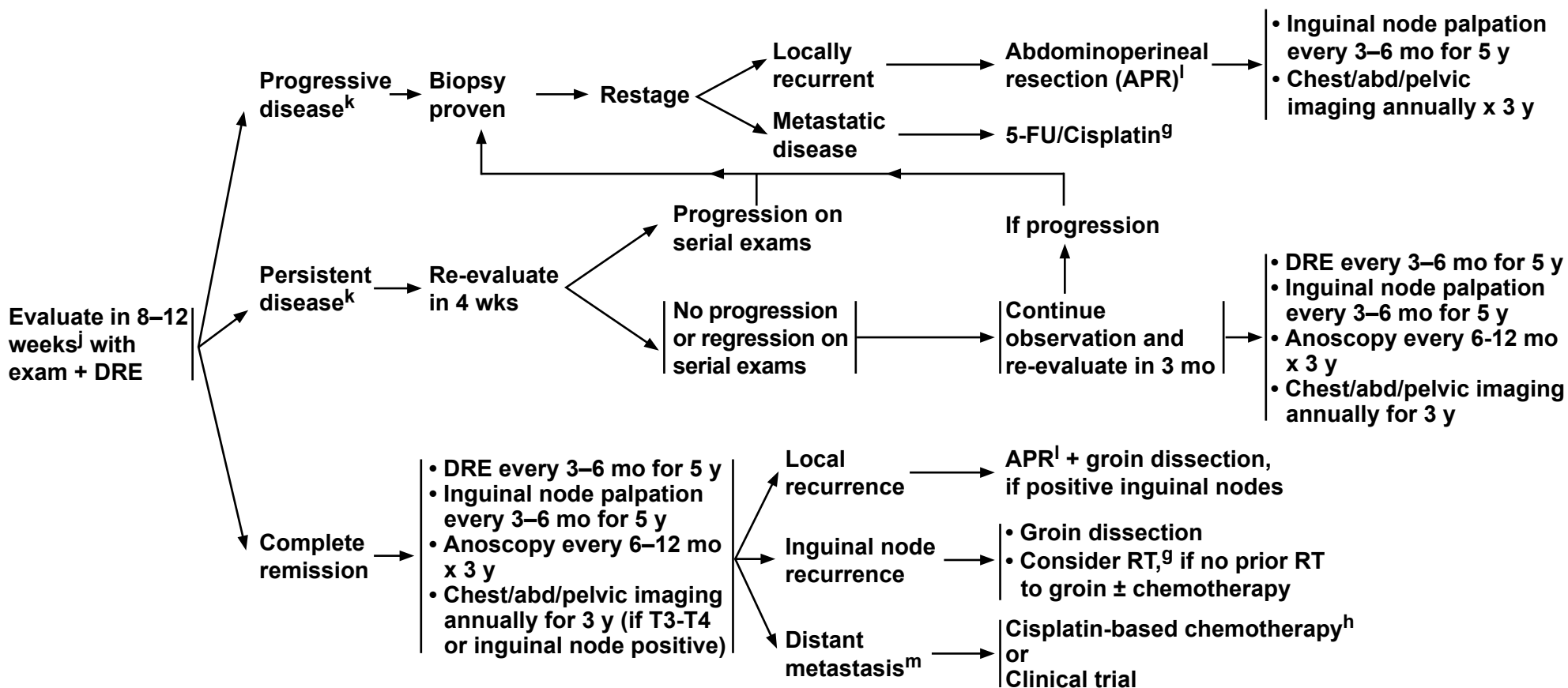
# NCCN Guidelines Version 2.2016

## Anal Carcinoma

### FOLLOW-UP

### TREATMENT

### SURVEILLANCE



<sup>g</sup>See Principles of Radiation Therapy (ANAL-B).

<sup>h</sup>Cisplatin/5-FU is recommended for metastatic disease. If this regimen fails, no other regimens have been shown to be effective.

<sup>i</sup>See Principles of Chemotherapy ANAL-A. Local control can be achieved with the use of RT.

<sup>j</sup>If a patient with an initially tethered tumor returns 6 weeks post RT with a mobile but suspicious mass, consider biopsy.

<sup>k</sup>Based on the results of the ACT-II study, it may be appropriate to follow patients who have not achieved a complete clinical response with persistent anal cancer up to 6 months following completion of radiation therapy and chemotherapy as long as there is no evidence of progressive disease during this period of follow-up. Persistent disease may continue to regress even at 26 weeks post-treatment. James RD, Glynn-Jones R, Meadows HM, et al. Mitomycin or cisplatin chemoradiation with or without maintenance chemotherapy for treatment of squamous cell carcinoma of the anus (Act II): a randomised, phase 3, open-label, 2x2 factorial trial. *Lancet Oncol* 2013;14:516-524.

<sup>l</sup>Consider muscle flap reconstruction.

<sup>m</sup>There is no evidence supporting resection of metastatic disease.

**Note:** All recommendations are category 2A unless otherwise indicated.

**Clinical Trials:** NCCN believes that the best management of any cancer patient is in a clinical trial. Participation in clinical trials is especially encouraged.



### PRINCIPLES OF CHEMOTHERAPY

#### Localized cancer

##### 5-FU + Mitomycin + RT<sup>1</sup>

Continuous infusion 5-FU 1000 mg/m<sup>2</sup>/d IV days 1–4 and 29–32

Mitomycin 10 mg/m<sup>2</sup> IV bolus days 1 and 29

Concurrent radiotherapy ([See ANAL-B](#))

##### Capecitabine + Mitomycin + RT<sup>2,3</sup>

- Capecitabine 825 mg/m<sup>2</sup> PO BID, Monday–Friday, on each day that RT is given, throughout the duration of RT (typically 28 treatment days)

Mitomycin 10 mg/m<sup>2</sup> days 1 and 29

Concurrent radiotherapy ([See ANAL-B](#))

or

- Capecitabine 825 mg/m<sup>2</sup> PO BID days 1–5 weekly x 6 weeks

Mitomycin 12 mg/m<sup>2</sup> IV bolus day 1

Concurrent radiotherapy ([See ANAL-B](#))

#### Metastatic cancer

##### 5-FU + Cisplatin<sup>4</sup>

Continuous infusion 5-FU 1000 mg/m<sup>2</sup>/d IV days 1–5

Cisplatin 100 mg/m<sup>2</sup> IV day 2

Repeat every 4 weeks

<sup>1</sup>Ajani JA, Winter KA, Gunderson LL, et al. Fluorouracil, mitomycin, and radiotherapy vs fluorouracil, cisplatin, and radiotherapy for carcinoma of the anal canal: a randomized controlled trial. JAMA 2008;299:1914-1921.

<sup>2</sup>Goodman KA, Rothenstein D, Cambridge L, et al. Capecitabine plus mitomycin in patients undergoing definitive chemoradiation for anal squamous cell carcinoma. Int J Radiat Oncol Biol Phys 2014 (in press).

<sup>3</sup>Thind G, Johal B, Follwell M, & Kennecke HF. Chemoradiation with capecitabine and mitomycin-C for stage I-III anal squamous cell carcinoma. Radiation Oncology 2014;9:124.

<sup>4</sup>Faivre C, Rougier P, Ducreux M, et al. 5-fluorouracil and cisplatin combination chemotherapy for metastatic squamous-cell anal cancer. Bull Cancer 1999;86:861-5.

**Note:** All recommendations are category 2A unless otherwise indicated.

**Clinical Trials:** NCCN believes that the best management of any cancer patient is in a clinical trial. Participation in clinical trials is especially encouraged.



**PRINCIPLES OF RADIATION THERAPY<sup>1</sup>**

- **Multifield techniques with supervoltage radiation (photon energy of >6 mV) should be used to deliver a minimum dose of 45 Gy in 1.8 Gy-fractions (25 fractions over 5 weeks) to the primary cancer.**
- **PET-CT should be considered for treatment planning.**
- **The inguinal nodes and the pelvis, anus, and perineum should be included in the initial radiation fields. The superior field border should be at L5-S1, and the inferior border should include the anus with a minimum 2.5-cm margin around the anus and tumor. The lateral border should include the lateral inguinal nodes (as determined from imaging or bony landmarks). There should be attempts to reduce the dose to the femoral heads.**
- **After 17 fractions (30.6 Gy), an additional 14.4 Gy should be given in 8 fractions with the superior field reduced to the bottom of the sacroiliac joints. Additional field reduction off inguinal nodes should occur after 36 Gy for node-negative lesions. This protocol brings the total dose to 45 Gy in 25 fractions over 5 weeks.**
- **For patients treated using an AP-PA technique, rather than the recommended multifield technique, the dose to the lateral inguinal region should be brought to the minimum dose of 36 Gy using an anterior electron boost matched to the PA exit field.**
- **For T2 lesions, T3/4 lesions, or N1 lesions, an additional boost of 9–14 Gy in 1.8–2 Gy fractions to the original primary tumor volume and involved nodes plus a 2–2.5 cm margin is usually delivered. This boost brings the total dose to 54–59 Gy in 30–32 fractions over 6–7.5 weeks. A direct perineal boost using photons or electrons with the patient in lithotomy position or a multifield photon approach (AP-PA plus paired laterals, PA + laterals, or other) can be used.**
- **The consensus of the panel is that intensity-modulated radiation therapy (IMRT) is preferred over 3-D conformal RT in the treatment of anal carcinoma.<sup>2</sup> IMRT requires expertise and careful target design to avoid reduction in local control by so-called “marginal-miss.”<sup>3</sup> The clinical target volumes for anal cancer used in the RTOG-0529 trial have been described in detail.<sup>2</sup> The outcome results of RTOG-0529 have been reported.<sup>4</sup>**

Also see [http://atc.wustl.edu/protocols/rtog-closed/0529/ANAL\\_Ca\\_CTVs\\_5-21-07\\_Final.pdf](http://atc.wustl.edu/protocols/rtog-closed/0529/ANAL_Ca_CTVs_5-21-07_Final.pdf) for more details of the contouring atlas defined by RTOG.

- **Side effect management:**

**Female patients should be considered for vaginal dilators and instructed on the symptoms of vaginal stenosis.**

**Male patients should be counseled on infertility risks and given information regarding sperm banking.**

**Female patients should be counseled on infertility risks and given information regarding oocyte, egg, or ovarian tissue banking prior to treatment.**

<sup>1</sup>Ajani JA, Winter KA, Gunderson LL, et al. Fluorouracil, mitomycin, and radiotherapy vs fluorouracil, cisplatin, and radiotherapy for carcinoma of the anal canal. *JAMA* 2008;299:1914-1921.

<sup>2</sup>Myerson RJ, Garofalo MC, El Naqa I, et al. Elective clinical target volumes for conformal therapy in anorectal cancer: a radiation therapy oncology group consensus panel contouring atlas. *Int J Radiat Oncol Biol Phys* 2009;74:824-830.

<sup>3</sup>Pepek JM, Willett CG, Czito BG. Radiation therapy advances for treatment of anal cancer. *J Natl Compr Canc Netw* 2010;8:123-129.

<sup>4</sup>Kachnic LA, Winter K, Myerson RJ, et al. RTOG 0529: a phase 2 evaluation of dose-painted intensity modulated radiation therapy in combination with 5-fluorouracil and mitomycin-C for the reduction of acute morbidity in carcinoma of the anal canal. *Int J Radiat Oncol Biol Phys* 2013;86:27-33.

**Note: All recommendations are category 2A unless otherwise indicated.**

**Clinical Trials: NCCN believes that the best management of any cancer patient is in a clinical trial. Participation in clinical trials is especially encouraged.**



# NCCN Guidelines Version 2.2016 Staging Anal Carcinoma

**Table 1. DEFINITIONS OF TNM****Primary Tumor (T)**

TX	Primary tumor cannot be assessed
T0	No evidence of primary tumor
Tis	Carcinoma in situ (Bowen's disease, high-grade squamous intraepithelial lesion (HSIL), anal intraepithelial neoplasia II–III (AIN II–III))
T1	Tumor 2 cm or less in greatest dimension
T2	Tumor more than 2 cm but not more than 5 cm in greatest dimension
T3	Tumor more than 5 cm in greatest dimension
T4	Tumor of any size invades adjacent organ(s), e.g., vagina, urethra, bladder*

\*Note: Direct invasion of the rectal wall, perirectal skin, subcutaneous tissue, or the sphincter muscle(s) is not classified as T4.

**Regional Lymph Nodes (N)**

NX	Regional lymph nodes cannot be assessed
N0	No regional lymph node metastasis
N1	Metastasis in perirectal lymph node(s)
N2	Metastasis in unilateral internal iliac and/or inguinal lymph node(s)
N3	Metastasis in perirectal and inguinal lymph nodes and/or bilateral internal iliac and/or inguinal lymph nodes

**Distant Metastasis (M)**

M0	No distant metastasis
M1	Distant metastasis

**Table 2. ANATOMIC STAGE/PROGNOSTIC GROUPS**

Stage	T	N	M
<b>0</b>	Tis	N0	M0
<b>I</b>	T1	N0	M0
<b>II</b>	T2	N0	M0
	T3	N0	M0
<b>IIIA</b>	T1	N1	M0
	T2	N1	M0
	T3	N1	M0
	T4	N0	M0
<b>IIIB</b>	T4	N1	M0
	Any T	N2	M0
	Any T	N3	M0
<b>IV</b>	Any T	Any N	M1

Used with the permission of the American Joint Committee on Cancer (AJCC), Chicago, Illinois. The original and primary source for this information is the AJCC Cancer Staging Manual, Seventh Edition (2010) published by Springer Science+Business Media, LLC (SBM). (For complete information and data supporting the staging tables, visit [www.springer.com](http://www.springer.com).) Any citation or quotation of this material must be credited to the AJCC as its primary source. The inclusion of this information herein does not authorize any reuse or further distribution without the expressed, written permission of Springer SBM, on behalf of the AJCC.



## Discussion

### NCCN Categories of Evidence and Consensus

**Category 1:** Based upon high-level evidence, there is uniform NCCN consensus that the intervention is appropriate.

**Category 2A:** Based upon lower-level evidence, there is uniform NCCN consensus that the intervention is appropriate.

**Category 2B:** Based upon lower-level evidence, there is NCCN consensus that the intervention is appropriate.

**Category 3:** Based upon any level of evidence, there is major NCCN disagreement that the intervention is appropriate.

**All recommendations are category 2A unless otherwise noted.**

Treatment of Anal Cancer in Patients with HIV/AIDS .....	MS-12
Recommendations for the Primary Treatment of Anal Canal Cancer .....	MS-13
Recommendations for the Primary Treatment of Anal Margin Cancer .....	MS-13
Treatment of Metastatic Anal Cancer .....	MS-13
Follow-up and Surveillance Following Primary Treatment .....	MS-14
Treatment of Locally Progressive or Recurrent Anal Carcinoma .....	MS-14
Follow-up and Surveillance Following Resection .....	MS-15
Summary .....	MS-15
References .....	MS-17

## Table of Contents

Overview .....	MS-2
Literature Search Criteria and Guidelines Update Methodology .....	MS-2
Risk Factors .....	MS-2
Risk Reduction .....	MS-3
HPV Immunization .....	MS-4
Anatomy/Histology .....	MS-4
Pathology .....	MS-5
Staging .....	MS-6
Prognostic Factors .....	MS-7
Management of Anal Carcinoma .....	MS-7
Clinical Presentation/Evaluation .....	MS-7
Primary Treatment of Non-Metastatic Anal Carcinoma .....	MS-8
Chemotherapy .....	MS-8
Radiation Therapy .....	MS-11



### Overview

An estimated 8080 new cases (2920 men and 5160 women) of anal cancer involving the anus, anal canal, or anorectum will occur in the United States in 2016, accounting for approximately 2.6% of digestive system cancers.<sup>1</sup> It has been estimated that 1080 deaths due to anal cancer will occur in the United States in 2016.<sup>1</sup> Although considered to be a rare type of cancer, the incidence rate of invasive anal carcinoma in the United States increased by approximately 1.9-fold for men and 1.5-fold for women from the period of 1973 through 1979 to 1994 through 2000 and has continued to increase since that time (see *Risk Factors*, below).<sup>2-4</sup> According to an analysis of SEER data, the incidence of anal squamous carcinoma increased at a rate of 2.9%/year from 1992 to 2001.<sup>5</sup>

This manuscript summarizes the NCCN Clinical Practice Guidelines for managing squamous cell anal carcinoma, which represents the most common histologic form of the disease. Other groups have also published guidelines for the management of anal squamous cell carcinoma.<sup>6</sup> Other types of cancers occurring in the anal region, such as adenocarcinoma or melanoma, are addressed in other NCCN Guidelines; anal adenocarcinoma and anal melanoma are managed according to the NCCN Guidelines for Rectal Cancer and the NCCN Guidelines for Melanoma, respectively. The recommendations in these guidelines are classified as category 2A except where noted, meaning that there is uniform NCCN consensus, based on lower-level evidence, that the recommendation is appropriate. The panel unanimously endorses patient participation in a clinical trial over standard or accepted therapy.

### Literature Search Criteria and Guidelines Update Methodology

Prior to the update of this version of the NCCN Guidelines for Anal Carcinoma, an electronic search of the PubMed database was performed to obtain key literature in the field of anal cancer published between July 23, 2014 and June 12, 2015, using the following search terms: (anal cancer) OR (anal squamous cell carcinoma). The PubMed database was chosen because it remains the most widely used resource for medical literature and indexes only peer-reviewed biomedical literature.<sup>7</sup>

The search results were narrowed by selecting studies in humans published in English. Results were confined to the following article types: Clinical Trial, Phase II; Clinical Trial, Phase III; Clinical Trial, Phase IV; Practice Guideline; Randomized Controlled Trial; Meta-Analysis; Systematic Reviews; and Validation Studies.

The PubMed search resulted in 519 citations, and their potential relevance was examined. The data from key PubMed articles and articles from additional sources deemed as relevant to these Guidelines and discussed by the panel have been included in this version of the Discussion section (eg, e-publications ahead of print, meeting abstracts). Recommendations for which high-level evidence is lacking are based on the panel's review of lower-level evidence and expert opinion.

The complete details of the Development and Update of the NCCN Guidelines are available on the NCCN website ([www.NCCN.org](http://www.NCCN.org)).

### Risk Factors

Anal carcinoma is associated with human papillomavirus (HPV) infection (anal-genital warts); a history of receptive anal intercourse or

sexually transmitted disease; a history of cervical, vulvar, or vaginal cancer; immunosuppression after solid organ transplantation or HIV infection; hematologic malignancies; certain autoimmune disorders; and smoking.<sup>8-14</sup>

The association between anal carcinoma and persistent infection with a high-risk form of HPV (eg, HPV-16; HPV-18) is especially strong.<sup>9,15,16</sup> For example, a study of tumor specimens from more than 60 pathology laboratories in Denmark and Sweden showed that high-risk HPV DNA was detected in 84% of anal cancer specimens, with HPV-16 detected in 73% of them. In contrast, high-risk HPV was not detected in any of the rectal cancer specimens analyzed.<sup>9</sup> In addition, results of a systematic review of 35 peer-reviewed anal cancer studies that included detection of HPV DNA published up until July 2007 showed the prevalence of HPV-16/18 to be 72% in patients with invasive anal cancer.<sup>16</sup> Recent population and registry studies have found similar HPV prevalence rates in anal cancer specimens.<sup>17,18</sup> A 2012 report from the U.S. Centers for Disease Control and Prevention estimated that 86% to 97% of cancers of the anus are attributable to HPV infection.<sup>19</sup>

Suppression of the immune system by the use of immunosuppressive drugs or HIV infection is likely to facilitate persistence of HPV infection of the anal region.<sup>20,21</sup> In the HIV-infected population, the standardized incidence rate of anal carcinoma per 100,000 person-years in the United States, estimated to be 19.0 in 1992 through 1995, increased to 78.2 during 2000 through 2003.<sup>22</sup> This result likely reflects both the survival benefits of highly active antiretroviral therapy (HAART) and the lack of an impact of HAART on the progression of anal cancer precursors. The incidence rate has recently been reported to be 131 per 100,000 person-years in HIV-infected men who have sex with men in North America.<sup>23</sup> Recent analysis of the French Hospital Database on HIV showed a highly elevated risk of anal cancer in HIV-positive

patients, including in those who were on therapy and whose CD4 cell counts were high.<sup>24</sup> The data also revealed an increasing incidence of anal cancer in the HIV population over time.

### Risk Reduction

High-grade anal intraepithelial neoplasia (AIN) can be a precursor to anal cancer,<sup>25-27</sup> and treatment of high-grade AIN may prevent the development of anal cancer. AIN can be identified by cytology, HPV testing, digital rectal examination (DRE), high-resolution anoscopy, and/or biopsy.<sup>28,29</sup> Estimates from a recent systematic review and meta-analysis of studies in men who have sex with men, however, suggest that the progression rates of AIN to cancer might be quite low, and prospective data are limited.<sup>30-33</sup> In addition, the spontaneous regression rate of high-grade AIN is not known.

Routine screening for AIN in high-risk individuals such as HIV-positive patients or men who have sex with men is controversial, because randomized controlled trials showing that such screening programs are efficacious at reducing anal cancer incidence and mortality are lacking, whereas the potential benefits are quite large.<sup>34-40</sup> Most guidelines do not recommend anal cancer screening even in high-risk individuals at this time or state that there may be some benefit with anal cytology.<sup>39,41</sup> Few guidelines recommend screening for anal cancer with DRE in HIV-positive individuals.<sup>42</sup>

Guidelines for the treatment of AIN have been developed by several groups, including the American Society of Colon and Rectal Surgeons.<sup>39,41,43,44</sup> Treatment recommendations vary widely because high-level evidence in the field is limited.<sup>43</sup> One randomized controlled trial in 246 HIV-positive men who have sex with men found that electrocautery was superior to both topical imiquimod and topical fluorouracil in the treatment of AIN overall.<sup>45</sup> The subgroup with perianal



AIN, as opposed to intra-anal AIN, appeared to respond better to imiquimod. Regardless of treatment, recurrence rates were high, and careful follow-up is likely needed. A large ongoing randomized phase III trial is comparing topical or ablative treatment with active monitoring in HIV-positive patients with high-grade AIN. The primary outcome measure is time to anal cancer, and the study is estimated to be completed in 2022 (clinicaltrials.gov NCT02135419).

### **HPV Immunization**

A quadrivalent HPV vaccine is available and has been shown to be effective in women in preventing persistent cervical infection with HPV-6, -11, -16, or -18 as well as in preventing high-grade cervical intraepithelial neoplasia related to these strains of the virus.<sup>46-48</sup> The vaccine has also been shown to be efficacious in young men at preventing genital lesions associated with HPV-6, -11, -16, or -18 infection.<sup>49</sup> A recent substudy of a larger double-blind study assessed the efficacy of the vaccine for the prevention of AIN and anal cancer related to infection with HPV-6, -11, -16, or -18 in men who have sex with men.<sup>50</sup> In this study, 602 healthy men who have sex with men aged 16 to 26 years were randomized to receive the vaccine or a placebo. While none of the participants in either arm developed anal cancer during the 3-year follow-up period, there were 5 cases of grade 2/3 AIN associated with one of the vaccine strains in the vaccine arm and 24 such cases in the placebo arm in the per-protocol population, giving an observed efficacy of 77.5% (95% CI, 39.6–93.3). Since high-grade AIN are known to have the ability to progress to anal cancer,<sup>25-27</sup> these results suggest that use of the quadrivalent HPV vaccine in men who have sex with men may reduce the risk of anal cancer in this population.

A bivalent HPV vaccine against HPV-16 and -18 is also available.<sup>51</sup> In a randomized, double-blind, controlled trial of women in Costa Rica, the vaccine was 83.6% effective against initial anal HPV-16/18 infection

(95% CI, 66.7–92.8).<sup>52</sup> It has also been shown to be effective at preventing high-grade cervical intraepithelial neoplasias in young women.<sup>53</sup> The effect on precancerous anal lesions has not yet been reported.

A 9-valent HPV vaccine is also now available, protecting against HPV-6, -11, -16, -18, -31, -33, -45, -52, and -58.<sup>54</sup> Targeting the additional strains over the quadrivalent vaccine is predicted to prevent an additional 464 cases of anal cancer annually.<sup>55</sup> This vaccine was compared to the quadrivalent vaccine in an international, randomized phase IIb-III study that included >14,000 women.<sup>56</sup> The 9-valent vaccine was noninferior to the quadrivalent vaccine for antibody response to HPV-6, -11, -16, and -18 and prevented infection and disease related to the other viral strains included in the vaccine. The calculated efficacy of the 9-valent vaccine was 96.7% (95% CI, 80.9–99.8) for the prevention of high-grade cervical, vulvar, or vaginal disease related to those strains.

The Advisory Committee on Immunization Practices recommends routine use of one of these 3 vaccines in boys and girls aged 11 and 12 years, in females aged 13 to 26 years, and in males aged 13 to 21 years who have not been previously vaccinated, and in men who have sex with men up to age 26 who have not been previously vaccinated.<sup>54,57</sup> The American Academy of Pediatrics concurs with this vaccination schedule.<sup>58</sup>

### **Anatomy/Histology**

The anal region is comprised of the anal canal and the anal margin, dividing anal cancers into 2 categories. The anal canal is the more proximal portion of the anal region. Various definitions of the anal canal exist (ie, functional/surgical; anatomic; histologic) that are based on particular physical/anatomic landmarks or histologic characteristics.



Histologically, the mucosal lining of the anal canal is predominantly formed by squamous epithelium, in contrast to the mucosa of the rectum, which is lined with glandular epithelium.<sup>11,59</sup> The anal margin, on the other hand, is lined with skin.<sup>60</sup> By the histologic definition, the most superior aspect of the anal canal is a 1- to 2-cm zone between the anal and rectal epithelium, which has rectal, urothelial, and squamous histologic characteristics.<sup>11,59</sup> The most inferior aspect of the anal canal, approximately at the anal verge, corresponds to the area where the mucosa, lined with modified squamous epithelium, transitions to an epidermis-lined anal margin.

The anatomic anal canal begins at the anorectal ring and extends to the anal verge (ie, squamous mucocutaneous junction with the perianal skin).<sup>60,61</sup>

Functionally, the anal canal is defined by the sphincter muscles. The superior border of the functional anal canal, separating it from the rectum, has been defined as the palpable upper border of the anal sphincter and puborectalis muscles of the anorectal ring. It is approximately 3 to 5 cm in length, and its inferior border starts at the anal verge, the lowermost edge of the sphincter muscles, corresponding to the introitus of the anal orifice.<sup>11,59,62</sup> The functional definition of the anal canal is primarily used in the radical surgical treatment of anal cancer and is used in these guidelines to differentiate between treatment options.

The anal margin starts at the anal verge and includes the perianal skin over a 5- to 6-cm radius from the squamous mucocutaneous junction.<sup>59,63</sup> It is covered by epidermis, not mucosa.<sup>11</sup> Tumors can involve both the anal canal and the anal margin.

## Pathology

Most primary cancers of the anal canal are of squamous cell histology.<sup>59,60</sup> The second edition of the WHO classification system of anal carcinoma designated all squamous cell carcinoma variants of the anal canal as cloacogenic and identified subtypes as large-cell keratinizing, large-cell non-keratinizing (transitional), or basaloid.<sup>64</sup> It has been reported that squamous cell cancers in the more proximal region of the anal canal are more likely to be non-keratinizing and less differentiated.<sup>11</sup> However, the terms cloacogenic, transitional, keratinizing, and basaloid were removed from the third and fourth editions of the WHO classification system of anal canal carcinoma,<sup>65,66</sup> and all subtypes have been included under a single generic heading of squamous cell carcinoma.<sup>63,65</sup> Reasons for this change include the following: both cloacogenic (which is sometimes used interchangeably with the term basaloid) and transitional tumors are now considered to be non-keratinizing tumors; it has been reported that both keratinizing and non-keratinizing tumors have a similar natural history and prognosis<sup>65</sup>; and a mixture of cell types frequently characterize histologic specimens of squamous cell carcinomas of the anal canal.<sup>59,65,67</sup> No distinction between squamous anal canal tumors on the basis of cell type has been made in these guidelines. Other less common anal canal tumors, not addressed in these guidelines, include adenocarcinomas in the rectal mucosa or the anal glands, small cell (anaplastic) carcinoma, undifferentiated cancers, and melanomas.<sup>59</sup>

Squamous cell carcinomas of the anal margin are more likely than those of the anal canal to be well-differentiated and keratinizing large-cell types,<sup>68</sup> but they are not characterized in the guidelines according to cell type. The presence of skin appendages (eg, hair follicles, sweat glands) in anal margin tumors can distinguish them from anal canal tumors. However, it is not always possible to distinguish between anal



# NCCN Guidelines Version 2.2016

## Anal Carcinoma

canal and anal margin squamous cell carcinoma since tumors can involve both areas.

Lymph drainage of anal cancer tumors is dependent on the location of the tumor in the anal region<sup>59,63</sup>: cancers in the perianal skin and the region of the anal canal distal to the dentate line drain mainly to the superficial inguinal nodes. Lymph drainage at and proximal to the dentate line is directed toward the anorectal, perirectal, and paravertebral nodes and to some of the nodes of the internal iliac system. More proximal cancers drain to perirectal nodes and to nodes of the inferior mesenteric system. Therefore, distal anal cancers present with a higher incidence of inguinal node metastases. Because the lymphatic drainage systems throughout the anal canal are not isolated from each other, however, inguinal node metastases can occur in proximal anal cancer as well.<sup>59</sup>

The College of American Pathologists publishes a protocol for the pathologic examination and reporting of anal tumors. The most recent update was made in June 2012.<sup>60</sup>

### Staging

The TNM staging system for anal canal cancer developed by the AJCC is detailed in the guidelines.<sup>63</sup> Since current recommendations for the primary treatment of anal canal cancer do not involve a surgical excision, most tumors are staged clinically with an emphasis on the size of the primary tumor as determined by direct examination and microscopic confirmation.<sup>63</sup> A tumor biopsy is required. Rectal ultrasound to determine depth of tumor invasion is not used in the staging of anal cancer (see *Clinical Presentation/Evaluation*, below).

In the past, these guidelines have used the AJCC TNM skin cancer system for the staging of anal margin cancer since the 2 types of

cancers have a similar biology. However, the latest addition of the AJCC Cancer Staging Manual made substantial changes to the cutaneous squamous cell carcinoma stagings,<sup>63</sup> making them much less appropriate for the staging of cancers of the anal margin. Furthermore, many anal margin cancers have involvement of the anal canal or have high-grade, pre-cancerous lesions in the anal canal. It is important to look for such anal canal involvement, particularly if conservative management (simple excision) is being contemplated. Many patients, particularly HIV-positive ones, could be significantly undertreated. For these reasons, these guidelines use the anal canal staging system for tumors of both the anal canal and the anal margin.

The prognosis of anal carcinoma is related to the size of the primary tumor and the presence of lymph node metastases.<sup>11</sup> According to the SEER database,<sup>69</sup> between 1999 and 2006, 50% of anal carcinomas were localized at initial diagnosis; these patients had an 80% 5-year survival rate. Approximately 29% of patients had anal carcinoma that had already spread to regional lymph nodes at diagnosis; these patients had a 60% 5-year survival rate. The 12% of patients presenting with distant metastasis demonstrated a 30.5% 5-year survival rate.<sup>69</sup> In a retrospective study of 270 patients treated for anal canal cancer with radiation therapy (RT) between 1980 and 1996, synchronous inguinal node metastasis was observed in 6.4% of patients with tumors staged as T1 or T2, and in 16% of patients with T3 or T4 tumors.<sup>70</sup> In patients with N2-3 disease, survival was related to T-stage rather than nodal involvement with respective 5-year survival rates of 72.7% and 39.9% for patients with T1-T2 and T3-T4 tumors; however, the number of patients involved in this analysis was small.<sup>70</sup> A recent analysis of >600 patients with non-metastatic anal carcinoma from the RTOG 98-11 trial also found that TN stage impacted clinical outcomes such as overall





survival (OS), disease-free survival (DFS), and colostomy failure, with the worst prognoses for patients with T4,N0 and T3-4,N+ disease.<sup>71</sup>

Lymph node staging in anal canal cancer is based on location of involved nodes: N1 designates metastasis in 1 or more perirectal nodes; N2 represents metastasis in unilateral internal iliac nodes and/or inguinal node(s); and N3 designates metastasis in perirectal and inguinal nodes and/or bilateral internal iliac and/or inguinal nodes.<sup>63</sup>

However, initial therapy of anal cancer does not typically involve surgery, and the true lymph node status may not be determined accurately by clinical and radiologic evaluation. Fine-needle aspiration (FNA) biopsy of inguinal nodes can be considered if tumor metastasis to these nodes is suspected. In a series of patients with anal cancer who underwent an abdominoperineal resection (APR), it was noted that pelvic nodal metastases were often less than 0.5 cm,<sup>72</sup> suggesting that routine radiologic evaluation with CT and PET scan may not be reliable in the determination of lymph node involvement (discussed in more detail in *Clinical Presentation/Evaluation*, below).

## Prognostic Factors

Multivariate analysis of data from the RTOG 98-11 trial showed that male sex and positive lymph nodes were independent prognostic factors for DFS in patients with anal cancer treated with 5-FU and radiation and either mitomycin or cisplatin.<sup>73</sup> Male sex, positive nodes, and tumor size greater than 5 cm were independently prognostic for worse OS. A secondary analysis of this trial found that tumor diameter could also be prognostic for colostomy rate and time to colostomy.<sup>74</sup> These results are consistent with earlier analyses from the EORTC 22861 trial, which found male sex, lymph node involvement, and skin ulceration to be prognostic for worse survival and local control.<sup>75</sup> Similarly, recent multivariate analyses of data from the ACT I trial also

showed that positive lymph nodes and male sex are prognostic indicators for higher local regional failure, anal cancer death, and lower OS.<sup>76</sup>

Recent data suggest that HPV- and/or p16-positivity are prognostic for improved OS in patients with anal carcinoma.<sup>77,78</sup> In a retrospective study of 143 tumor samples, p16-positivity was an independent prognostic factor for OS (HR, 0.07; 95% CI, 0.01–0.61;  $P = .016$ ).<sup>78</sup> Another study of 95 patients found similar results.<sup>77</sup>

## Management of Anal Carcinoma

### Clinical Presentation/Evaluation

Approximately 45% of patients with anal carcinoma present with rectal bleeding, while approximately 30% have either pain or the sensation of a rectal mass.<sup>11</sup> Following confirmation of squamous cell carcinoma by biopsy, the recommendations of the NCCN Anal Carcinoma Guidelines Panel for the clinical evaluation of patients with anal canal or anal margin cancer are very similar.

The panel recommends a thorough examination/evaluation, including a careful DRE, an anoscopic examination, and palpation of the inguinal lymph nodes, with FNA and/or excisional biopsy of nodes found to be enlarged by either clinical or radiologic examination. Evaluation of pelvic lymph nodes with CT or MRI of the pelvis is also recommended. These methods can also provide information on whether the tumor involves other abdominal/pelvic organs; however, assessment of T stage is primarily performed through clinical examination. A CT scan of the abdomen is also recommended to assess possible disease dissemination. Since veins of the anal region are part of the venous network associated with systemic circulation,<sup>59</sup> chest CT scan is performed to evaluate for pulmonary metastasis. HIV testing and

measurement of CD4 level is suggested, because the risk of anal carcinoma has been reported to be higher in HIV-positive patients.<sup>13</sup> Gynecologic exam, including cervical cancer screening, is suggested for female patients due to the association of anal cancer and HPV.<sup>9</sup>

PET/CT scanning can be considered to verify staging before treatment. PET/CT scanning has been reported to be useful in the evaluation of pelvic nodes, even in patients with anal canal cancer who have normal-sized lymph nodes on CT imaging.<sup>79-84</sup> A systematic review and meta-analysis of 7 retrospective and 5 prospective studies calculated pooled estimates of sensitivity and specificity for detection of lymph node involvement by PET/CT to be 56% (95% CI, 45%–67%) and 90% (95% CI, 86%–93%), respectively.<sup>80</sup> Another systematic review and meta-analysis found that PET/CT resulted in a change of nodal status in 28% of patients, with approximately half upstaged and half downstaged.<sup>85</sup> The panel does not consider PET/CT to be a replacement for a diagnostic CT. Furthermore, the panel noted that the routine use of a PET/CT scan for staging has not been validated.

### Primary Treatment of Non-Metastatic Anal Carcinoma

In the past, patients with invasive anal carcinoma were routinely treated with an APR; however, local recurrence rates were high, 5-year survival was only 40% to 70%, and the morbidity with a permanent colostomy was considerable.<sup>11</sup> In 1974, Nigro and coworkers observed complete tumor regression in some patients with anal carcinoma treated with preoperative 5-FU–based concurrent chemotherapy and radiation (chemoRT) including either mitomycin or porfiromycin, suggesting that it might be possible to cure anal carcinoma without surgery and permanent colostomy.<sup>86</sup> Subsequent nonrandomized studies using similar regimens and varied doses of chemoRT provided support for this conclusion.<sup>87,88</sup> Results of randomized trials evaluating the efficacy and

safety of administering chemotherapy with RT support the use of combined modality therapy in the treatment of anal cancer.<sup>14</sup> Summaries of clinical trials involving patients with anal cancer have been presented,<sup>89,90</sup> and several key trials are discussed below.

### Chemotherapy

A phase III study from the EORTC compared the use of chemoRT (5-FU plus mitomycin) to RT alone in the treatment of anal carcinoma. Results from this trial showed that patients in the chemoRT arm had an 18% higher rate of locoregional control at 5 years and a 32% longer colostomy-free interval.<sup>75</sup> The United Kingdom Coordinating Committee on Cancer Research (UKCCCR) randomized ACT I trial confirmed that chemoRT with 5-FU and mitomycin was more effective in controlling local disease than RT alone (relative risk, 0.54; 95% CI, 0.42–0.69;  $P < .0001$ ), although no significant differences in OS were observed at 3 years.<sup>91</sup> A recently published follow-up study on these patients demonstrates that a clear benefit of chemoRT remains after 13 years, including a benefit in OS.<sup>92</sup> The median survival was 5.4 years in the RT arm and 7.6 years in the chemoRT arm. There was also a reduction in the risk of dying from anal cancer (HR, 0.67; 95% CI, 0.51–0.88,  $P = .004$ ).

A few studies have addressed the efficacy and safety of specific chemotherapeutic agents in the chemoRT regimens used in the treatment of anal carcinoma.<sup>73,93,94</sup> In a phase III Intergroup study, patients receiving chemoRT with the combination of 5-FU and mitomycin had a lower colostomy rate (9% vs. 22%;  $P = .002$ ) and a higher 4-year DFS (73% vs. 51%;  $P = .0003$ ) compared with patients receiving chemoRT with 5-FU alone, indicating that mitomycin is an important component of chemoRT in the treatment of anal carcinoma.<sup>94</sup> The OS rate at 4 years was the same for the 2 groups, however,



reflecting the ability to treat recurrent patients with additional chemoradiation or an APR.

Capecitabine, an oral fluoropyrimidine prodrug, is an accepted alternative to 5-FU in the treatment of colon and rectal cancer.<sup>95-98</sup> Capecitabine has therefore been assessed as an alternative to 5-FU in chemoradiation regimens for non-metastatic anal cancer.<sup>99-102</sup> A retrospective study compared 58 patients treated with capecitabine to 47 patients treated with infusional 5-FU; both groups also received mitomycin and radiation.<sup>101</sup> No significant differences were seen in clinical complete response, 3-year locoregional control, 3-year OS, or colostomy-free survival between the 2 groups of patients. Another retrospective study compared 27 patients treated with capecitabine to 62 patients treated with infusional 5-FU; as in the other study, both groups also received mitomycin and radiation.<sup>100</sup> Grade 3/4 hematologic toxicities were significantly lower in the capecitabine group, with no oncologic outcomes reported. A phase II study found that chemoradiation with capecitabine and mitomycin was safe and resulted in a 6-month locoregional control rate of 86% (95 % CI, 0.72–0.94) in patients with localized anal cancer.<sup>103</sup> Although data for this regimen are limited, the panel recommends mitomycin/capecitabine plus radiation as an alternative to mitomycin/5-FU plus radiation in the setting of stage I through III anal cancer.

Cisplatin as a substitute for 5-FU was evaluated in a phase II trial, and results suggest that cisplatin-containing and 5-FU-containing chemoRT may be comparable for treatment of locally advanced anal cancer.<sup>93</sup>

The efficacy of replacing mitomycin with cisplatin has also been assessed. The phase III UK ACT II trial compared cisplatin with mitomycin and also looked at the effect of additional maintenance chemotherapy following chemoRT. Results from ACT II, the largest trial

ever conducted in patients with anal cancer, were recently published.<sup>104</sup> In this study, more than 900 patients with newly diagnosed anal cancer were randomly assigned to primary treatment with either 5-FU/mitomycin or 5-FU/cisplatin with radiotherapy. A continuous course (ie, no treatment gap) of radiation of 50.4 Gy was administered in both arms, and patients in each arm were further randomized to receive 2 cycles of maintenance therapy with 5-FU and cisplatin or no maintenance therapy. At a median follow-up of 5.1 years, no differences were observed in the primary endpoint of complete response rate in either arm for the chemoRT comparison or in the primary endpoint of progression-free survival for the comparison of maintenance therapy versus no maintenance therapy. In addition, a secondary endpoint, colostomy, did not show differences based on the chemotherapeutic components of chemoRT. These results demonstrate that replacement of mitomycin with cisplatin in chemoRT does not affect the rate of complete response, nor does administration of maintenance therapy decrease the rate of disease recurrence following primary treatment with chemoRT in patients with anal cancer.

Cisplatin as a substitute for mitomycin in the treatment of patients with non-metastatic anal carcinoma was also evaluated in the randomized phase III Intergroup RTOG 98-11 trial. The role of induction chemotherapy was also assessed. In this study, 682 patients were randomly assigned to receive either: 1) induction 5-FU plus cisplatin for 2 cycles followed by concurrent chemoRT with 5-FU and cisplatin; or 2) concurrent chemoRT with 5-FU and mitomycin.<sup>73,105</sup> A significant difference was observed in the primary endpoint, 5-year DFS, in favor of the mitomycin group (57.8% vs. 67.8%;  $P = .006$ ).<sup>105</sup> Five-year OS was also significantly better in the mitomycin arm (70.7% vs. 78.3%;  $P = .026$ ).<sup>105</sup> In addition, 5-year colostomy-free survival showed a trend towards statistical significance (65.0% vs. 71.9%;  $P = .05$ ), again in

favor of the mitomycin group. Since the 2 treatment arms in the RTOG 98-11 trial differed with respect to use of either cisplatin or mitomycin in concurrent chemoRT as well as inclusion of induction chemotherapy in the cisplatin-containing arm, it is difficult to attribute the differences to the substitution of cisplatin for mitomycin or to the use of induction chemotherapy.<sup>89,106</sup> However, since ACT II demonstrated that the two chemoRT regimens are equivalent, some have suggested that results from RTOG 98-11 suggest that induction chemotherapy is probably detrimental.<sup>107</sup>

Results from ACCORD 03 also suggest that there is no benefit of a course of chemotherapy given prior to chemoradiation.<sup>108</sup> In this study, patients with locally advanced anal cancer were randomized to receive induction therapy with 5-FU/cisplatin or no induction therapy followed by chemoRT (they were further randomized to receive an additional radiation boost or not). No differences were seen between tumor complete response, tumor partial response, 3-year colostomy-free survival, local control, event-free survival, or 3-year OS. Final analysis of the ACCORD 03 trial was recently published.<sup>109</sup> After a median follow-up of 50 months, no advantage to induction chemotherapy (or to the additional radiation boost) was observed, consistent with earlier results. A systematic review of randomized trials also showed no benefit to a course of induction chemotherapy.<sup>110</sup>

A recent retrospective analysis, however, suggests that induction chemotherapy preceding chemoradiation may be beneficial for the subset of patients with T4 anal cancer.<sup>111</sup> The 5-year colostomy-free survival rate was significantly better in T4 patients who received induction 5-FU/cisplatin compared to those who did not (100% vs. 38 ± 16.4%, *P* = .0006).

The combination of 5-FU, mitomycin C, and cisplatin has also been studied in a phase II trial, but was found to be too toxic.<sup>112</sup> In addition, a trial assessing the safety and efficacy of capecitabine/oxaliplatin with radiation in the treatment of localized anal cancer has been completed, but final results have not yet been reported (clinicaltrials.gov NCT00093379). Preliminary results from this trial seem promising.<sup>113</sup>

Cetuximab is an epidermal growth factor receptor (EGFR) inhibitor, whose anti-tumor activity is dependent on the presence of wild-type *KRAS*.<sup>114</sup> Because *KRAS* mutations appear to be very rare in anal cancer,<sup>115,116</sup> the use of an EGFR inhibitor such as cetuximab has been considered to be a promising avenue of investigation. Results of the phase II ECOG 3205 and AIDS Malignancy Consortium 045 trials were reported in 2012.<sup>117</sup> These trials evaluated the safety and efficacy of cetuximab with cisplatin/5-FU and radiation in immunocompetent (E3205) and HIV-positive (AMC045) patients with anal squamous cell carcinoma. Although additional recruitment and follow-up are required to assess the primary endpoints of a reduction in 3-year locoregional failure rates, preliminary results from these trials are encouraging with acceptable toxicity and 2-year PFS rates of 92% (95% CI, 81%–100%) and 80% (95% CI, 61%–90%) in the immunocompetent and HIV-positive populations, respectively.<sup>117</sup> However, the ACCORD 16 phase II trial, which was designed to assess response rate after chemoRT with cisplatin/5-FU and cetuximab, was terminated prematurely because of extremely high rates of serious adverse events.<sup>118</sup> The 15 evaluable patients from ACCORD 16 had a 4-year DFS rate of 53% (95% CI, 28–79), and 2 of the 5 patients who completed the planned treatments had locoregional recurrences.<sup>119</sup> A phase I study of cetuximab with 5-fluorouracil, cisplatin, and radiation also saw a high rate of toxicity.<sup>120</sup> Longer term results from E3205 and AMC045 will be presented at the



2016 ASCO Annual Meeting (ClinicalTrials.gov identifiers: NCT00316888 and NCT00324415).

### **Radiation Therapy**

The optimal dose and schedule of RT for anal carcinoma also continues to be explored, and has been evaluated in a number of nonrandomized studies. In one study of patients with early-stage (T1 or Tis) anal canal cancer, most patients were effectively treated with RT doses of 40 to 50 Gy for Tis lesions and 50 to 60 Gy for T1 lesions.<sup>121</sup> In another study, in which the majority of patients had stage II/III anal canal cancer, local control of disease was higher in patients who received RT doses greater than 50 Gy than in those who received lower doses (86.5% vs. 34%,  $P = .012$ ).<sup>122</sup> In a third study of patients with T3, T4, or lymph node-positive tumors, RT doses of  $\geq 54$  Gy administered with limited treatment breaks (less than 60 days) were associated with increased local control.<sup>123</sup> The effect of further escalation of radiation dose was assessed in the ACCORD 03 trial, with the primary endpoint of colostomy-free survival at 3 years.<sup>108</sup> No benefit was seen with the higher dose of radiation. These results are supported by much earlier results from the RTOG 92-08 trial<sup>124</sup> and suggest that doses of  $>59$  Gy provide no additional benefit to patients with anal cancer.

There is evidence that treatment interruptions, either planned or required by treatment-related toxicity, can compromise the effectiveness of treatment.<sup>83</sup> In the phase II RTOG 92-08 trial, a planned 2-week treatment break in the delivery of chemoRT to patients with anal cancer was associated with increased locoregional failure rates and lower colostomy-free survival rates when compared to patients who only had treatment breaks for severe skin toxicity,<sup>125</sup> although the trial was not designed for that particular comparison. In addition, the absence of a planned treatment break in the ACT II trial was considered to be at least partially responsible for the high colostomy-free survival rates observed

in that study (74% at 3 years).<sup>104</sup> Although results of these and other studies have supported the benefit of delivery of chemoRT over shorter time periods,<sup>126-128</sup> treatment breaks in the delivery of chemoRT are required in up to 80% of patients since chemoRT-related toxicities are common.<sup>128</sup> For example, it has been reported that one-third of patients receiving primary chemoRT for anal carcinoma at RT doses of 30 Gy in 3 weeks develop acute anoproctitis and perineal dermatitis, increasing to one-half to two-thirds of patients when RT doses of 54 to 60 Gy are administered in 6 to 7 weeks.<sup>59</sup>

Some of the reported late side effects of chemoRT include increased frequency and urgency of defecation, chronic perineal dermatitis, dyspareunia, and impotence.<sup>129,130</sup> In some cases, severe late RT complications, such as anal ulcers, stenosis, and necrosis, may necessitate surgery involving colostomy.<sup>130</sup> In addition, results from a retrospective cohort study of data from the SEER registry showed the risk of subsequent pelvic fracture to be 3-fold higher in older women undergoing RT for anal cancer compared with older women with anal cancer who did not receive RT.<sup>131</sup>

An increasing body of literature suggests that toxicity can be reduced with advanced radiation delivery techniques.<sup>83,132-142</sup> Intensity-modulated radiation therapy (IMRT) utilizes detailed beam shaping to target specific volumes and limit the exposure of normal tissue.<sup>141</sup> Multiple pilot studies have demonstrated reduced toxicity while maintaining local control using IMRT. For example, in a cross-study comparison of a multicenter study of 53 patients with anal cancer treated with concurrent 5-FU/mitomycin chemotherapy and IMRT compared to patients in the 5-FU/mitomycin arm of the randomized RTOG 98-11 study, which used conventional 3-D RT, the rates of grade 3/4 dermatologic toxicity were 38%/0% for IMRT-treated patients compared to 43%/5% for those undergoing conventional RT.<sup>73,141</sup> No decrease in treatment



effectiveness or local control rates was observed with use of IMRT, although the small sample size and short duration of follow-up limit the conclusions drawn from such a comparison. In one retrospective comparison between IMRT and conventional radiotherapy, IMRT was less toxic and showed better efficacy in 3-year OS, locoregional control, and progression-free survival.<sup>143</sup> In a larger retrospective comparison, no significant differences in local recurrence-free survival, distant metastasis-free survival, colostomy-free survival, and OS at 2 years were seen between patients receiving IMRT and those receiving 3-D conformal radiotherapy, despite the fact that the IMRT group had a higher average N stage.<sup>144</sup>

The only prospective study assessing IMRT for anal cancer is the phase II dose-painted IMRT study, RTOG 0529. This trial did not meet its primary endpoint of reducing grade 2+ combined acute genitourinary and gastrointestinal adverse events by 15% compared to the chemoRT/5-FU/mitomycin arm from RTOG 98-11, which used conventional radiation.<sup>145</sup> Of 52 evaluable patients, the grade 2+ combined acute adverse event rate was 77%; the rate in RTOG 98-11 was also 77%. However, significant reductions were seen in grade 2+ hematologic events (73% vs. 85%;  $P = .032$ ), grade 3+ gastrointestinal events (21% vs. 36%;  $P = .008$ ), and grade 3+ dermatologic events (23% vs. 49%;  $P < .0001$ ). Clinical outcomes will be reported in the future and are of great interest because of the risk of underdosing (marginal miss) associated with highly conformal RT.<sup>145</sup>

Recommendations regarding RT doses follow the multifield technique used in the RTOG 98-11 trial.<sup>73</sup> PET/CT should be considered for treatment planning.<sup>146</sup> All patients should receive a minimum RT dose of 45 Gy to the primary cancer. The recommended initial RT dose is 30.6 Gy to the pelvis, anus, perineum, and inguinal nodes; there should be attempts to reduce the dose to the femoral heads. Field reduction off

the superior field border and node-negative inguinal nodes is recommended after delivery of 30.6 Gy and 36 Gy, respectively. For patients treated with an anteroposterior-posteroanterior (AP-PA) rather than multifield technique, the dose to the lateral inguinal region should be brought to the minimum dose of 36 Gy using an anterior electron boost matched to the PA exit field. Patients with disease clinically staged as node-positive or T2-T4 should receive an additional boost of 9 to 14 Gy. The consensus of the panel is that IMRT is preferred over 3-D conformal RT in the treatment of anal carcinoma.<sup>147</sup> IMRT requires expertise and careful target design to avoid reduction in local control by marginal miss.<sup>83</sup> The clinical target volumes for anal cancer used in the RTOG 0529 trial have been described in detail.<sup>147</sup> Also see [http://atc.wustl.edu/protocols/rto-g-closed/0529/ANAL\\_Ca\\_CTVs\\_5-21-07\\_Final.pdf](http://atc.wustl.edu/protocols/rto-g-closed/0529/ANAL_Ca_CTVs_5-21-07_Final.pdf) and <http://www.rtog.org/CoreLab/ContouringAtlases/Anorectal.aspx> for more details of the contouring atlas defined by RTOG.

#### ***Treatment of Anal Cancer in Patients with HIV/AIDS***

As discussed above (see *Risk Factors*), patients with HIV/AIDS have been reported to be at increased risk for anal carcinoma.<sup>13,14,148,149</sup> Although most studies evaluating outcomes of patients with HIV/AIDS treated with chemoRT for anal carcinoma are retrospective,<sup>14</sup> evidence indicates that patients with anal carcinoma as the first manifestation of HIV/AIDS (especially those with a CD4 count of  $\geq 200/\text{mm}^3$ ) may be treated with the same regimen as HIV-negative patients.<sup>150,151</sup>

Most evidence regarding outcomes in HIV-positive patients with anal cancer comes from retrospective comparisons, a few of which found worse outcomes in the HIV-positive group.<sup>152,153</sup> For example, a recent cohort comparison of 40 HIV-positive patients and 81 HIV-negative patients with anal canal cancer found local relapse rates to be 4 times higher in the HIV-positive group (62% vs. 13%) at 3 years and found

significantly higher rates of severe acute skin toxicity for patients infected with HIV.<sup>153</sup> However, no differences in rates of complete response or 5-year OS were observed between the groups in that study. Most studies, however, have found outcomes to be similar in HIV-positive and HIV-negative populations.<sup>154-156</sup> In a retrospective cohort study of 1184 veterans diagnosed with squamous cell carcinoma of the anus between 1998 and 2004 (15% of whom tested positive for HIV), no differences with respect to receipt of treatment or 2-year survival rates were observed when the group of patients infected with HIV was compared with the group of patients testing negative for HIV.<sup>154</sup> Another study of 36 consecutive patients with anal cancer including 19 immunocompetent and 17 immunodeficient (14 HIV-positive) patients showed no differences in the efficacy or toxicity of chemoRT.<sup>155</sup> A recent population-based study of almost 2 million patients with cancer, 6459 of whom were infected with HIV, found no increase in cancer-specific mortality for anal cancer in HIV-positive patients.<sup>157</sup>

It is unclear whether increased compliance with HAART is associated with better outcomes following chemoRT for anal carcinoma.<sup>14,158,159</sup> Patients with active HIV/AIDS-related complications or a history of complications (eg, malignancies, opportunistic infections) may not tolerate full-dose therapy and may require dosage adjustment.

### **Recommendations for the Primary Treatment of Anal Canal Cancer**

Currently, concurrent chemoRT is the recommended primary treatment for patients with nonmetastatic anal canal cancer. Mitomycin and 5-FU or mitomycin and capecitabine are administered concurrently with radiation.<sup>73,100-102</sup> Most studies have delivered 5-FU as a protracted 96- to 120-hour infusion during the first and fifth weeks of RT, and bolus injection of mitomycin is typically given on the first or second day of the 5-FU infusion.<sup>59</sup> Capecitabine is given orally, Monday through Friday,

for 4 or 6 weeks, with bolus injection of mitomycin and concurrent radiation.<sup>100,102</sup>

RT is associated with significant side effects. Patients should be counseled on infertility risks and given information regarding sperm, oocyte, egg, or ovarian tissue banking prior to treatment. In addition, female patients should be considered for vaginal dilators and should be instructed on the symptoms of vaginal stenosis.

### **Recommendations for the Primary Treatment of Anal Margin Cancer**

Anal margin lesions can be treated with either local excision or chemoRT depending on the clinical stage. Primary treatment for patients with T1, N0 well-differentiated anal margin cancers is by local excision with adequate margins. The ASCRS defines an adequate margin as 1 cm.<sup>41</sup> If the margins are not adequate, re-excision is the preferred treatment option. Local RT with or without continuous infusion 5-FU- or capecitabine-based chemotherapy can be considered as an alternative treatment option when surgical margins are inadequate. For all other stages of anal margin cancer, the treatment options are the same as for anal canal cancer (see above).<sup>160</sup>

### **Treatment of Metastatic Anal Cancer**

It has been reported that the most common sites of anal cancer metastasis outside of the pelvis are the liver, lung, and extrapelvic lymph nodes.<sup>161</sup> Since anal carcinoma is a rare cancer and only 10% to 20% of patients with anal carcinoma present with extrapelvic metastatic disease,<sup>161</sup> only limited data are available on this population of patients. Despite this fact, some evidence indicates that chemotherapy with a fluoropyrimidine-based regimen plus cisplatin has some benefit in patients with metastatic anal carcinoma.<sup>160-164</sup> No evidence supports resection of metastatic disease.

Treatment recommendations for patients with a distant metastasis should be individualized, but metastatic disease is usually treated with cisplatin-based chemotherapy.<sup>160</sup> The efficacies of other regimens are also being assessed.<sup>165,166</sup> Enrollment in a clinical trial is another option. For example, the phase II International Multicentre InterAACT study (clinicaltrials.gov NCT02051868) is comparing cisplatin plus 5-FU with carboplatin plus paclitaxel in patients with unresectable locally recurrent or metastatic anal squamous cell carcinoma. Palliative RT (best administered with 5-FU- or capecitabine-based chemotherapy with a platinum agent) can also be given to patients with metastatic disease for local control in the case of a symptomatic bulky primary.<sup>146</sup> If cisplatin-based chemotherapy fails, no other regimens have been shown to be effective.

### Follow-up and Surveillance Following Primary Treatment

Following primary treatment of non-metastatic anal cancer, the surveillance and follow-up treatment recommendations for anal margin and anal canal cancer are the same. Patients are re-evaluated by DRE between 8 and 12 weeks after completion of chemoRT. Following re-evaluation, patients are classified according to whether they have a complete remission of disease, persistent disease, or progressive disease. Patients with persistent disease but without evidence of progression may be managed with close follow-up (in 4 weeks) to see if further regression occurs.

The National Cancer Research Institute's ACT II study compared different chemoRT regimens and found no difference in OS or progression-free survival.<sup>167</sup> Interestingly, 29% of patients in this trial who did not show a complete response at 11 weeks had achieved a complete response by 26 weeks. Based on these results, the panel believes it may be appropriate to follow patients who have not achieved

a complete clinical response with persistent anal cancer for up to 6 months after completion of radiation and chemotherapy, as long as there is no evidence of progressive disease during this period of follow-up. Persistent disease may continue to regress even at 26 weeks post-treatment, and APR can thereby be avoided in some patients. If biopsy-proven disease progression occurs, further intensive treatment is indicated (see *Treatment of Locally Progressive or Recurrent Anal Carcinoma*, below).

Although a clinical assessment of progressive disease requires histologic confirmation, patients can be classified as having a complete remission without biopsy verification if clinical evidence of disease is absent. The panel recommends that these patients undergo evaluation every 3 to 6 months for 5 years, including DRE, anoscopic evaluation, and inguinal node palpation. Annual chest, abdominal, and pelvic imaging is recommended for 3 years for patients with slow disease regression and for those who initially had locally advanced disease (ie, T3/T4 tumor) or node-positive cancers.

### Treatment of Locally Progressive or Recurrent Anal Carcinoma

Despite the effectiveness of chemoRT in the primary treatment of anal carcinoma, rates of locoregional failure of 10% to 30% have been reported.<sup>168,169</sup> Some of the disease characteristics that have been associated with higher recurrence rates following chemoRT include higher T stage and higher N stage (also see the section on *Prognostic Factors*, above).<sup>170</sup>

Evidence of progression found on DRE should be followed by biopsy as well as restaging with CT and/or PET imaging. Patients with biopsy-proven locally progressive disease are candidates for radical surgery with an APR and colostomy.<sup>169</sup>





A recent multicenter retrospective cohort study looked at the cause-specific colostomy rates in 235 patients with anal cancer who were treated with radiotherapy or chemoradiation from 1995 to 2003.<sup>171</sup> The 5-year cumulative incidence rates for tumor-specific and therapy-specific colostomy were 26% (95% CI, 21%–32%) and 8% (95% CI, 5%–12%), respectively. Larger tumor size (>6 cm) was a risk factor for tumor-specific colostomy, while local excision prior to radiotherapy was a risk factor for therapy-specific colostomy. However, it should be noted that these patients were treated with older chemotherapy and RT regimens, which could account for these high colostomy rates.<sup>172</sup>

In studies involving a minimum of 25 patients undergoing an APR for anal carcinoma, 5-year survival rates of 39% to 64% have been observed.<sup>168,169,173-175</sup> Complication rates were reported to be high in some of these studies. Factors associated with worse prognosis following APR include an initial presentation of node-positive disease and RT doses <55 Gy used in the treatment of primary disease.<sup>169</sup>

It has been shown that for patients undergoing an APR that was preceded by RT, closure of the perineal wound using rectus abdominis myocutaneous flap reconstruction results in decreased perineal wound complications.<sup>176</sup> Muscle flap reconstruction of the perineum should therefore be considered for patients with extensive previous RT to the area.

A recent retrospective analysis of the medical records of 14 patients who received intraoperative radiation therapy (IORT) during APR revealed that IORT is unlikely to improve local control or to give a survival benefit.<sup>177</sup> This technique is not recommended during surgery in patients with recurrent anal cancer.

Inguinal node dissection is reserved for recurrence in that area, and can be performed without an APR in cases where recurrence is limited to the inguinal nodes. Patients who develop inguinal node metastasis who do not undergo an APR can be considered for RT to the groin with or without chemotherapy, if no prior RT to the groin was given.

#### ***Follow-up and Surveillance Following Resection***

Following APR, patients should undergo re-evaluation every 3 to 6 months for 5 years, including clinical evaluation for nodal metastasis (ie, inguinal node palpation). In addition, it is recommended that these patients undergo annual imaging of the chest, abdomen, and pelvis for 3 years. In one retrospective study of 105 patients with anal canal carcinoma who had an APR between 1996 and 2009, the overall recurrence rate following APR was 43%.<sup>178</sup> Those with T3/4 tumors or involved margins were more likely to experience recurrence. The 5-year survival rate after APR has been reported to be 60% to 64%.<sup>178,179</sup>

#### **Summary**

The NCCN Anal Carcinoma Guidelines Panel believes that a multidisciplinary approach including physicians from gastroenterology, medical oncology, surgical oncology, radiation oncology, and radiology is necessary for treating patients with anal carcinoma. Recommendations for the primary treatment of anal margin cancer and anal canal cancer are very similar and include continuous infusion 5-FU/mitomycin-based RT or capecitabine/mitomycin-based RT in most cases. The exception is small, well-differentiated anal margin lesions, which can be treated with margin-negative local excision alone. Follow-up clinical evaluations are recommended for all patients with anal carcinoma because additional curative-intent treatment is possible. Patients with biopsy-proven evidence of locoregional progressive disease following primary treatment should undergo an APR. Following



## NCCN Guidelines Version 2.2016 Anal Carcinoma

complete remission of disease, patients with a local recurrence should be treated with an APR with a groin dissection if there is clinical evidence of inguinal nodal metastasis, and patients with a regional recurrence in the inguinal nodes can be treated with an inguinal node dissection, with consideration of RT with or without chemotherapy if no prior RT to the groin was given. Patients with evidence of extrapelvic metastatic disease should be treated with cisplatin-based chemotherapy or enrolled in a clinical trial. The panel endorses the concept that treating patients in a clinical trial has priority over standard or accepted therapy.



## References

1. Siegel RL, Miller KD, Jemal A. Cancer statistics, 2016. *CA Cancer J Clin* 2016;66:7-30. Available at: <http://www.ncbi.nlm.nih.gov/pubmed/26742998>.
2. Jemal A, Simard EP, Dorell C, et al. Annual Report to the Nation on the Status of Cancer, 1975-2009, featuring the burden and trends in human papillomavirus (HPV)-associated cancers and HPV vaccination coverage levels. *J Natl Cancer Inst* 2013;105:175-201. Available at: <http://www.ncbi.nlm.nih.gov/pubmed/23297039>.
3. Johnson LG, Madeleine MM, Newcomer LM, et al. Anal cancer incidence and survival: the surveillance, epidemiology, and end results experience, 1973-2000. *Cancer* 2004;101:281-288. Available at: <http://www.ncbi.nlm.nih.gov/pubmed/15241824>.
4. Nelson RA, Levine AM, Bernstein L, et al. Changing patterns of anal canal carcinoma in the United States. *J Clin Oncol* 2013;31:1569-1575. Available at: <http://www.ncbi.nlm.nih.gov/pubmed/23509304>.
5. Shiels MS, Kreimer AR, Coghill AE, et al. Anal cancer incidence in the United States, 1977-2011: distinct patterns by histology and behavior. *Cancer Epidemiol Biomarkers Prev* 2015;24:1548-1556. Available at: <http://www.ncbi.nlm.nih.gov/pubmed/26224796>.
6. Glynne-Jones R, Nilsson PJ, Aschele C, et al. Anal cancer: ESMO-ESSO-ESTRO clinical practice guidelines for diagnosis, treatment and follow-up. *Radiother Oncol* 2014;111:330-339. Available at: <http://www.ncbi.nlm.nih.gov/pubmed/24947004>.
7. U.S. National Library of Medicine-Key MEDLINE® Indicators. Available at: [http://www.nlm.nih.gov/bsd/bsd\\_key.html](http://www.nlm.nih.gov/bsd/bsd_key.html). Accessed April 26, 2016.
8. Daling JR, Madeleine MM, Johnson LG, et al. Human papillomavirus, smoking, and sexual practices in the etiology of anal cancer. *Cancer* 2004;101:270-280. Available at: <http://www.ncbi.nlm.nih.gov/pubmed/15241823>.
9. Frisch M, Glimelius B, van den Brule AJ, et al. Sexually transmitted infection as a cause of anal cancer. *N Engl J Med* 1997;337:1350-1358. Available at: <http://www.ncbi.nlm.nih.gov/pubmed/9358129>.
10. Jimenez W, Paszat L, Kupets R, et al. Presumed previous human papillomavirus (HPV) related gynecological cancer in women diagnosed with anal cancer in the province of Ontario. *Gynecol Oncol* 2009;114:395-398. Available at: <http://www.ncbi.nlm.nih.gov/pubmed/19501390>.
11. Ryan DP, Compton CC, Mayer RJ. Carcinoma of the anal canal. *N Engl J Med* 2000;342:792-800. Available at: <http://www.ncbi.nlm.nih.gov/pubmed/10717015>.
12. Sunesen KG, Norgaard M, Thorlacius-Ussing O, Laurberg S. Immunosuppressive disorders and risk of anal squamous cell carcinoma: a nationwide cohort study in Denmark, 1978-2005. *Int J Cancer* 2010;127:675-684. Available at: <http://www.ncbi.nlm.nih.gov/pubmed/19960431>.
13. Frisch M, Biggar RJ, Goedert JJ. Human papillomavirus-associated cancers in patients with human immunodeficiency virus infection and acquired immunodeficiency syndrome. *J Natl Cancer Inst* 2000;92:1500-1510. Available at: <http://www.ncbi.nlm.nih.gov/pubmed/10995805>.
14. Uronis HE, Bendell JC. Anal cancer: an overview. *Oncologist* 2007;12:524-534. Available at: <http://www.ncbi.nlm.nih.gov/pubmed/17522240>.
15. De Vuyst H, Clifford GM, Nascimento MC, et al. Prevalence and type distribution of human papillomavirus in carcinoma and intraepithelial neoplasia of the vulva, vagina and anus: a meta-analysis. *Int J Cancer* 2009;124:1626-1636. Available at: <http://www.ncbi.nlm.nih.gov/pubmed/19115209>.
16. Hoots BE, Palefsky JM, Pimenta JM, Smith JS. Human papillomavirus type distribution in anal cancer and anal intraepithelial



lesions. *Int J Cancer* 2009;124:2375-2383. Available at:

<http://www.ncbi.nlm.nih.gov/pubmed/19189402>.

17. Ouhoumane N, Steben M, Coutlee F, et al. Squamous anal cancer: patient characteristics and HPV type distribution. *Cancer Epidemiol* 2013;37:807-812. Available at:

<http://www.ncbi.nlm.nih.gov/pubmed/24139594>.

18. Steinau M, Unger ER, Hernandez BY, et al. Human papillomavirus prevalence in invasive anal cancers in the United States before vaccine introduction. *J Low Genit Tract Dis* 2013;17:397-403. Available at:

<http://www.ncbi.nlm.nih.gov/pubmed/23609590>.

19. Human papillomavirus-associated cancers - United States, 2004-2008. *MMWR Morb Mortal Wkly Rep* 2012;61:258-261. Available at:

<http://www.ncbi.nlm.nih.gov/pubmed/22513527>.

20. Palefsky JM, Holly EA, Ralston ML, Jay N. Prevalence and risk factors for human papillomavirus infection of the anal canal in human immunodeficiency virus (HIV)-positive and HIV-negative homosexual men. *J Infect Dis* 1998;177:361-367. Available at:

<http://www.ncbi.nlm.nih.gov/pubmed/9466522>.

21. Patel HS, Silver AR, Northover JM. Anal cancer in renal transplant patients. *Int J Colorectal Dis* 2007;22:1-5. Available at:

<http://www.ncbi.nlm.nih.gov/pubmed/16133005>.

22. Patel P, Hanson DL, Sullivan PS, et al. Incidence of types of cancer among HIV-infected persons compared with the general population in the United States, 1992-2003. *Ann Intern Med* 2008;148:728-736. Available at:

<http://www.ncbi.nlm.nih.gov/pubmed/18490686>.

23. Silverberg MJ, Lau B, Justice AC, et al. Risk of anal cancer in HIV-infected and HIV-uninfected individuals in North America. *Clin Infect Dis* 2012;54:1026-1034. Available at:

<http://www.ncbi.nlm.nih.gov/pubmed/22291097>.

24. Piketty C, Selinger-Leneman H, Bouvier AM, et al. Incidence of HIV-related anal cancer remains increased despite long-term combined antiretroviral treatment: results from the french hospital database on HIV. *J Clin Oncol* 2012;30:4360-4366. Available at:

<http://www.ncbi.nlm.nih.gov/pubmed/23091098>.

25. Berry JM, Jay N, Cranston RD, et al. Progression of anal high-grade squamous intraepithelial lesions to invasive anal cancer among HIV-infected men who have sex with men. *Int J Cancer* 2014;134:1147-1155. Available at: <http://www.ncbi.nlm.nih.gov/pubmed/23934991>.

26. Scholefield JH, Castle MT, Watson NF. Malignant transformation of high-grade anal intraepithelial neoplasia. *Br J Surg* 2005;92:1133-1136. Available at: <http://www.ncbi.nlm.nih.gov/pubmed/16044425>.

27. Watson AJ, Smith BB, Whitehead MR, et al. Malignant progression of anal intra-epithelial neoplasia. *ANZ J Surg* 2006;76:715-717. Available at:

<http://www.ncbi.nlm.nih.gov/pubmed/16916390>.

28. Berry JM, Palefsky JM, Jay N, et al. Performance characteristics of anal cytology and human papillomavirus testing in patients with high-resolution anoscopy-guided biopsy of high-grade anal intraepithelial neoplasia. *Dis Colon Rectum* 2009;52:239-247. Available at:

<http://www.ncbi.nlm.nih.gov/pubmed/19279418>.

29. Jay N. Elements of an anal dysplasia screening program. *J Assoc Nurses AIDS Care* 2011;22:465-477. Available at:

<http://www.ncbi.nlm.nih.gov/pubmed/22035526>.

30. Fuchs W, Wieland U, Skaletz-Rorowski A, et al. The male ScreenING Study: prevalence of HPV-related genital and anal lesions in an urban cohort of HIV-positive men in Germany. *J Eur Acad Dermatol Venereol* 2016. Available at:

<http://www.ncbi.nlm.nih.gov/pubmed/26833895>.

31. Jin F, Grulich AE, Poynten IM, et al. The performance of anal cytology as a screening test for anal HSILs in homosexual men. *Cancer*



Cytopathol 2016. Available at:

<http://www.ncbi.nlm.nih.gov/pubmed/26915346>.

32. Machalek DA, Poynten M, Jin F, et al. Anal human papillomavirus infection and associated neoplastic lesions in men who have sex with men: a systematic review and meta-analysis. *Lancet Oncol* 2012;13:487-500. Available at:

<http://www.ncbi.nlm.nih.gov/pubmed/22445259>.

33. Schofield AM, Sadler L, Nelson L, et al. A prospective study of anal cancer screening in HIV positive and negative men who have sex with men; results of Analogy. *AIDS* 2016. Available at:

<http://www.ncbi.nlm.nih.gov/pubmed/26836788>.

34. Barroso LF. Anal cancer screening. *Lancet Oncol* 2012;13:e278-279; author reply e280. Available at:

<http://www.ncbi.nlm.nih.gov/pubmed/22748260>.

35. Goldstone SE, Johnstone AA, Moshier EL. Long-term outcome of ablation of anal high-grade squamous intraepithelial lesions: recurrence and incidence of cancer. *Dis Colon Rectum* 2014;57:316-323. Available at:

<http://www.ncbi.nlm.nih.gov/pubmed/24509453>.

36. Palefsky J, Berry JM, Jay N. Anal cancer screening. *Lancet Oncol* 2012;13:e279-280; author reply e280. Available at:

<http://www.ncbi.nlm.nih.gov/pubmed/22748261>.

37. Park IU, Palefsky JM. Evaluation and management of anal intraepithelial neoplasia in HIV-negative and HIV-positive men who have sex with men. *Curr Infect Dis Rep* 2010;12:126-133. Available at:

<http://www.ncbi.nlm.nih.gov/pubmed/20461117>.

38. Roark R. The need for anal dysplasia screening and treatment programs for HIV-infected men who have sex with men: a review of the literature. *J Assoc Nurses AIDS Care* 2011;22:433-443. Available at:

<http://www.ncbi.nlm.nih.gov/pubmed/22035523>.

39. Scholefield JH, Harris D, Radcliffe A. Guidelines for management of anal intraepithelial neoplasia. *Colorectal Dis* 2011;13 Suppl 1:3-10.

Available at: <http://www.ncbi.nlm.nih.gov/pubmed/21251167>.

40. Wentzensen N. Screening for anal cancer: endpoints needed. *Lancet Oncol* 2012;13:438-440. Available at:

<http://www.ncbi.nlm.nih.gov/pubmed/22445258>.

41. Steele SR, Varma MG, Melton GB, et al. Practice parameters for anal squamous neoplasms. *Dis Colon Rectum* 2012;55:735-749.

Available at: <http://www.ncbi.nlm.nih.gov/pubmed/22706125>.

42. Ong JJ, Chen M, Grulich AE, Fairley CK. Regional and national guideline recommendations for digital ano-rectal examination as a means for anal cancer screening in HIV positive men who have sex with men: a systematic review. *BMC Cancer* 2014;14:557. Available at:

<http://www.ncbi.nlm.nih.gov/pubmed/25081485>.

43. Alam NN, White DA, Narang SK, et al. Systematic review of guidelines for the assessment and management of high-grade anal intraepithelial neoplasia (AIN II/III). *Colorectal Dis* 2016;18:135-146.

Available at: <http://www.ncbi.nlm.nih.gov/pubmed/26559167>.

44. Hartschuh W, Breitkopf C, Lenhard B, et al. S1 guideline: anal intraepithelial neoplasia (AIN) and perianal intraepithelial neoplasia (PAIN). *J Dtsch Dermatol Ges* 2011;9:256-258. Available at:

<http://www.ncbi.nlm.nih.gov/pubmed/21208377>.

45. Richel O, de Vries HJ, van Noesel CJ, et al. Comparison of imiquimod, topical fluorouracil, and electrocautery for the treatment of anal intraepithelial neoplasia in HIV-positive men who have sex with men: an open-label, randomised controlled trial. *Lancet Oncol* 2013;14:346-353. Available at:

<http://www.ncbi.nlm.nih.gov/pubmed/23499546>.

46. Quadrivalent vaccine against human papillomavirus to prevent high-grade cervical lesions. *N Engl J Med* 2007;356:1915-1927. Available at:

<http://www.ncbi.nlm.nih.gov/pubmed/17494925>.



# NCCN Guidelines Version 2.2016

## Anal Carcinoma

47. Dillner J, Kjaer SK, Wheeler CM, et al. Four year efficacy of prophylactic human papillomavirus quadrivalent vaccine against low grade cervical, vulvar, and vaginal intraepithelial neoplasia and anogenital warts: randomised controlled trial. *BMJ* 2010;341:c3493. Available at: <http://www.ncbi.nlm.nih.gov/pubmed/20647284>.
48. Garland SM, Hernandez-Avila M, Wheeler CM, et al. Quadrivalent vaccine against human papillomavirus to prevent anogenital diseases. *N Engl J Med* 2007;356:1928-1943. Available at: <http://www.ncbi.nlm.nih.gov/pubmed/17494926>.
49. Giuliano AR, Palefsky JM, Goldstone S, et al. Efficacy of quadrivalent HPV vaccine against HPV Infection and disease in males. *N Engl J Med* 2011;364:401-411. Available at: <http://www.ncbi.nlm.nih.gov/pubmed/21288094>.
50. Palefsky JM, Giuliano AR, Goldstone S, et al. HPV vaccine against anal HPV infection and anal intraepithelial neoplasia. *N Engl J Med* 2011;365:1576-1585. Available at: <http://www.ncbi.nlm.nih.gov/pubmed/22029979>.
51. FDA licensure of bivalent human papillomavirus vaccine (HPV2, Cervarix) for use in females and updated HPV vaccination recommendations from the Advisory Committee on Immunization Practices (ACIP). *MMWR Morb Mortal Wkly Rep* 2010;59:626-629. Available at: <http://www.ncbi.nlm.nih.gov/pubmed/20508593>.
52. Kreimer AR, Gonzalez P, Katki HA, et al. Efficacy of a bivalent HPV 16/18 vaccine against anal HPV 16/18 infection among young women: a nested analysis within the Costa Rica Vaccine Trial. *Lancet Oncol* 2011;12:862-870. Available at: <http://www.ncbi.nlm.nih.gov/pubmed/21865087>.
53. Lehtinen M, Paavonen J, Wheeler CM, et al. Overall efficacy of HPV-16/18 AS04-adjuvanted vaccine against grade 3 or greater cervical intraepithelial neoplasia: 4-year end-of-study analysis of the randomised, double-blind PATRICIA trial. *Lancet Oncol* 2011;13:69-99. Available at: <http://www.ncbi.nlm.nih.gov/pubmed/22075171>.
54. Petrosky E, Bocchini JA, Jr., Hariri S, et al. Use of 9-valent human papillomavirus (HPV) vaccine: updated HPV vaccination recommendations of the advisory committee on immunization practices. *MMWR Morb Mortal Wkly Rep* 2015;64:300-304. Available at: <http://www.ncbi.nlm.nih.gov/pubmed/25811679>.
55. Saraiya M, Unger ER, Thompson TD, et al. US assessment of HPV types in cancers: implications for current and 9-valent HPV vaccines. *J Natl Cancer Inst* 2015;107:djv086. Available at: <http://www.ncbi.nlm.nih.gov/pubmed/25925419>.
56. Joura EA, Giuliano AR, Iversen OE, et al. A 9-valent HPV vaccine against infection and intraepithelial neoplasia in women. *N Engl J Med* 2015;372:711-723. Available at: <http://www.ncbi.nlm.nih.gov/pubmed/25693011>.
57. Markowitz LE, Dunne EF, Saraiya M, et al. Human papillomavirus vaccination: recommendations of the Advisory Committee on Immunization Practices (ACIP). *MMWR Recomm Rep* 2014;63:1-30. Available at: <http://www.ncbi.nlm.nih.gov/pubmed/25167164>.
58. HPV vaccine recommendations. *Pediatrics* 2012;129:602-605. Available at: <http://www.ncbi.nlm.nih.gov/pubmed/22371460>.
59. Cummings BJ, Ajani JA, Swallow CJ. Cancer of the anal region. In: DeVita Jr. VT, Lawrence TS, Rosenberg SA, et al., eds. *Cancer: Principles & Practice of Oncology*, Eighth Edition. Philadelphia, PA: Lippincott, Williams & Wilkins; 2008.
60. Tang LH, Berlin J, Branton P, et al. Protocol for the Examination of Specimens from Patients with Carcinoma of the Anus. 2012. Available at: [http://www.cap.org/apps/docs/committees/cancer/cancer\\_protocols/2012/Anus\\_12protocol\\_3200.pdf](http://www.cap.org/apps/docs/committees/cancer/cancer_protocols/2012/Anus_12protocol_3200.pdf).
61. Pandey P. Anal anatomy and normal histology. *Sex Health* 2012;9:513-516. Available at: <http://www.ncbi.nlm.nih.gov/pubmed/23380234>.



62. Nivatvongs S, Stern HS, Fryd DS. The length of the anal canal. *Dis Colon Rectum* 1981;24:600-601. Available at: <http://www.ncbi.nlm.nih.gov/pubmed/7318624>.
63. Edge SBB, D.R.; Compton, C.C.; Fritz, A.G.; Greene, F.L.; Trotti, A., ed *AJCC Cancer Staging Manual* (ed 7th Edition). New York: Springer; 2010.
64. Jass JR, Sobin LH. *Histological Typing of Intestinal Tumours*: Springer-Verlag Berlin Heidelberg; 1989.
65. Fenger C, Frisch M, Marti MC, Parc R. Tumours of the anal canal. In: Hamilton SR, Aaltonen LA, eds. *WHO Classification of Tumours, Volume 2: Pathology and Genetics. Tumours of the Digestive System*. Lyon: IARC Press; 2000:145-155.
66. Welton ML, Lambert R, Bosman FT. Tumours of the Anal Canal. In: Bosman FT, Carneiro, F., Hruban, R. H., Theise, N.D., ed. *WHO Classification of Tumours of the Digestive System*. Lyon: IARC; 2010:183-193.
67. Fenger C. Prognostic factors in anal carcinoma. *Pathology* 2002;34:573-578. Available at: <http://www.ncbi.nlm.nih.gov/pubmed/12555997>.
68. Oliver GC, Labow SB. Neoplasms of the anus. *Surg Clin North Am* 1994;74:1475-1490. Available at: <http://www.ncbi.nlm.nih.gov/pubmed/7985077>.
69. Altekruse SF, Kosary CL, Krapcho M, et al. *SEER Cancer Statistics Review, 1975-2007*. 2010. Available at: [http://seer.cancer.gov/csr/1975\\_2007/](http://seer.cancer.gov/csr/1975_2007/).
70. Gerard JP, Chapet O, Samiei F, et al. Management of inguinal lymph node metastases in patients with carcinoma of the anal canal: experience in a series of 270 patients treated in Lyon and review of the literature. *Cancer* 2001;92:77-84. Available at: <http://www.ncbi.nlm.nih.gov/pubmed/11443612>.
71. Gunderson LL, Moughan J, Ajani JA, et al. Anal carcinoma: impact of TN category of disease on survival, disease relapse, and colostomy failure in US Gastrointestinal Intergroup RTOG 98-11 phase 3 trial. *Int J Radiat Oncol Biol Phys* 2013;87:638-645. Available at: <http://www.ncbi.nlm.nih.gov/pubmed/24035327>.
72. Wade DS, Herrera L, Castillo NB, Petrelli NJ. Metastases to the lymph nodes in epidermoid carcinoma of the anal canal studied by a clearing technique. *Surg Gynecol Obstet* 1989;169:238-242. Available at: <http://www.ncbi.nlm.nih.gov/pubmed/2672386>.
73. Ajani JA, Winter KA, Gunderson LL, et al. Fluorouracil, mitomycin, and radiotherapy vs fluorouracil, cisplatin, and radiotherapy for carcinoma of the anal canal: a randomized controlled trial. *JAMA* 2008;299:1914-1921. Available at: <http://www.ncbi.nlm.nih.gov/pubmed/18430910>.
74. Ajani JA, Winter KA, Gunderson LL, et al. US intergroup anal carcinoma trial: tumor diameter predicts for colostomy. *J Clin Oncol* 2009;27:1116-1121. Available at: <http://www.ncbi.nlm.nih.gov/pubmed/19139424>.
75. Bartelink H, Roelofsen F, Eschwege F, et al. Concomitant radiotherapy and chemotherapy is superior to radiotherapy alone in the treatment of locally advanced anal cancer: results of a phase III randomized trial of the European Organization for Research and Treatment of Cancer Radiotherapy and Gastrointestinal Cooperative Groups. *J Clin Oncol* 1997;15:2040-2049. Available at: <http://www.ncbi.nlm.nih.gov/pubmed/9164216>.
76. Glynne-Jones R, Sebag-Montefiore D, Adams R, et al. Prognostic factors for recurrence and survival in anal cancer: generating hypotheses from the mature outcomes of the first United Kingdom Coordinating Committee on Cancer Research Anal Cancer Trial (ACT I). *Cancer* 2013;119:748-755. Available at: <http://www.ncbi.nlm.nih.gov/pubmed/23011911>.

77. Rodel F, Wieland U, Fraunholz I, et al. Human papillomavirus DNA load and p16 expression predict for local control in patients with anal squamous cell carcinoma treated with chemoradiotherapy. *Int J Cancer* 2014. Available at: <http://www.ncbi.nlm.nih.gov/pubmed/24839133>.
78. Serup-Hansen E, Linnemann D, Skovrider-Ruminski W, et al. Human papillomavirus genotyping and p16 expression as prognostic factors for patients with American Joint Committee on Cancer stages I to III carcinoma of the anal canal. *J Clin Oncol* 2014;32:1812-1817. Available at: <http://www.ncbi.nlm.nih.gov/pubmed/24821878>.
79. Bhuvana NJ, Glynne-Jones R, Sonoda L, et al. To PET or not to PET? That is the question. Staging in anal cancer. *Ann Oncol* 2012;23:2078-2082. Available at: <http://www.ncbi.nlm.nih.gov/pubmed/22294527>.
80. Caldarella C, Annunziata S, Treglia G, et al. Diagnostic performance of positron emission tomography/computed tomography using fluorine-18 fluorodeoxyglucose in detecting locoregional nodal involvement in patients with anal canal cancer: a systematic review and meta-analysis. *Scientific World Journal* 2014:196068. Available at: <http://www.ncbi.nlm.nih.gov/pubmed/24672298>.
81. Cotter SE, Grigsby PW, Siegel BA, et al. FDG-PET/CT in the evaluation of anal carcinoma. *Int J Radiat Oncol Biol Phys* 2006;65:720-725. Available at: <http://www.ncbi.nlm.nih.gov/pubmed/16626889>.
82. Mistrangelo M, Pelosi E, Bello M, et al. Role of positron emission tomography-computed tomography in the management of anal cancer. *Int J Radiat Oncol Biol Phys* 2012;84:66-72. Available at: <http://www.ncbi.nlm.nih.gov/pubmed/22592047>.
83. Pepek JM, Willett CG, Czito BG. Radiation therapy advances for treatment of anal cancer. *J Natl Compr Canc Netw* 2010;8:123-129. Available at: <http://www.ncbi.nlm.nih.gov/pubmed/20064294>.
84. Trautmann TG, Zuger JH. Positron Emission Tomography for pretreatment staging and posttreatment evaluation in cancer of the anal canal. *Mol Imaging Biol* 2005;7:309-313. Available at: <http://www.ncbi.nlm.nih.gov/pubmed/16028002>.
85. Jones M, Hruby G, Solomon M, et al. The role of FDG-PET in the initial staging and response assessment of anal cancer: a systematic review and meta-analysis. *Ann Surg Oncol* 2015;22:3574-3581. Available at: <http://www.ncbi.nlm.nih.gov/pubmed/25652048>.
86. Nigro ND, Vaitkevicius VK, Considine B. Combined therapy for cancer of the anal canal: a preliminary report. *Dis Colon Rectum* 1974;17:354-356. Available at: <http://www.ncbi.nlm.nih.gov/pubmed/4830803>.
87. Cummings BJ, Keane TJ, O'Sullivan B, et al. Epidermoid anal cancer: treatment by radiation alone or by radiation and 5-fluorouracil with and without mitomycin C. *Int J Radiat Oncol Biol Phys* 1991;21:1115-1125. Available at: <http://www.ncbi.nlm.nih.gov/pubmed/1938508>.
88. Papillon J, Chassard JL. Respective roles of radiotherapy and surgery in the management of epidermoid carcinoma of the anal margin. Series of 57 patients. *Dis Colon Rectum* 1992;35:422-429. Available at: <http://www.ncbi.nlm.nih.gov/pubmed/1568392>.
89. Czito BG, Willett CG. Current management of anal canal cancer. *Curr Oncol Rep* 2009;11:186-192. Available at: <http://www.ncbi.nlm.nih.gov/pubmed/19336010>.
90. Glynne-Jones R, Lim F. Anal cancer: an examination of radiotherapy strategies. *Int J Radiat Oncol Biol Phys* 2011;79:1290-1301. Available at: <http://www.ncbi.nlm.nih.gov/pubmed/21414513>.
91. Epidermoid anal cancer: results from the UKCCCR randomised trial of radiotherapy alone versus radiotherapy, 5-fluorouracil, and mitomycin. UKCCCR Anal Cancer Trial Working Party. UK Coordinating Committee on Cancer Research. *Lancet* 1996;348:1049-1054. Available at: <http://www.ncbi.nlm.nih.gov/pubmed/8874455>.





92. Northover J, Glynn-Jones R, Sebag-Montefiore D, et al. Chemoradiation for the treatment of epidermoid anal cancer: 13-year follow-up of the first randomised UKCCCR Anal Cancer Trial (ACT I). *Br J Cancer* 2010;102:1123-1128. Available at: <http://www.ncbi.nlm.nih.gov/pubmed/20354531>.
93. Crehange G, Bosset M, Lorchel F, et al. Combining cisplatin and mitomycin with radiotherapy in anal carcinoma. *Dis Colon Rectum* 2007;50:43-49. Available at: <http://www.ncbi.nlm.nih.gov/pubmed/17089083>.
94. Flam M, John M, Pajak TF, et al. Role of mitomycin in combination with fluorouracil and radiotherapy, and of salvage chemoradiation in the definitive nonsurgical treatment of epidermoid carcinoma of the anal canal: results of a phase III randomized intergroup study. *J Clin Oncol* 1996;14:2527-2539. Available at: <http://www.ncbi.nlm.nih.gov/pubmed/8823332>.
95. Hofheinz RD, Wenz F, Post S, et al. Chemoradiotherapy with capecitabine versus fluorouracil for locally advanced rectal cancer: a randomised, multicentre, non-inferiority, phase 3 trial. *Lancet Oncol* 2012;13:579-588. Available at: <http://www.ncbi.nlm.nih.gov/pubmed/22503032>.
96. O'Connell MJ, Colangelo LH, Beart RW, et al. Capecitabine and oxaliplatin in the preoperative multimodality treatment of rectal cancer: surgical end points from National Surgical Adjuvant Breast and Bowel Project trial R-04. *J Clin Oncol* 2014;32:1927-1934. Available at: <http://www.ncbi.nlm.nih.gov/pubmed/24799484>.
97. Twelves C, Scheithauer W, McKendrick J, et al. Capecitabine versus 5-fluorouracil/folinic acid as adjuvant therapy for stage III colon cancer: final results from the X-ACT trial with analysis by age and preliminary evidence of a pharmacodynamic marker of efficacy. *Ann Oncol* 2012;23:1190-1197. Available at: <http://www.ncbi.nlm.nih.gov/pubmed/21896539>.
98. Twelves C, Wong A, Nowacki MP, et al. Capecitabine as adjuvant treatment for stage III colon cancer. *N Engl J Med* 2005;352:2696-2704. Available at: <http://www.ncbi.nlm.nih.gov/pubmed/15987918>.
99. Glynn-Jones R, Meadows H, Wan S, et al. EXTRA--a multicenter phase II study of chemoradiation using a 5 day per week oral regimen of capecitabine and intravenous mitomycin C in anal cancer. *Int J Radiat Oncol Biol Phys* 2008;72:119-126. Available at: <http://www.ncbi.nlm.nih.gov/pubmed/18472366>.
100. Goodman K, Rothenstein D, Lajhem C, et al. Capecitabine plus mitomycin in patients undergoing definitive chemoradiation for anal squamous cell carcinoma. *Int J Radiat Oncol Biol Phys* 2014;90:S32-S33. Available at: [http://www.redjournal.org/article/S0360-3016\(14\)00792-5/fulltext](http://www.redjournal.org/article/S0360-3016(14)00792-5/fulltext).
101. Meulendijks D, Dewit L, Tomaso NB, et al. Chemoradiotherapy with capecitabine for locally advanced anal carcinoma: an alternative treatment option. *Br J Cancer* 2014;111:1726-1733. Available at: <http://www.ncbi.nlm.nih.gov/pubmed/25167226>.
102. Thind G, Johal B, Follwell M, Kennecke HF. Chemoradiation with capecitabine and mitomycin-C for stage I-III anal squamous cell carcinoma. *Radiat Oncol* 2014;9:124. Available at: <http://www.ncbi.nlm.nih.gov/pubmed/24885554>.
103. Oliveira SC, Moniz CM, Riechelmann R, et al. Phase II study of capecitabine in substitution of 5-FU in the chemoradiotherapy regimen for patients with localized squamous cell carcinoma of the anal canal. *J Gastrointest Cancer* 2016;47:75-81. Available at: <http://www.ncbi.nlm.nih.gov/pubmed/26691173>.
104. James RD, Glynn-Jones R, Meadows HM, et al. Mitomycin or cisplatin chemoradiation with or without maintenance chemotherapy for treatment of squamous-cell carcinoma of the anus (ACT II): a randomised, phase 3, open-label, 2 x 2 factorial trial. *Lancet Oncol* 2013;14:516-524. Available at: <http://www.ncbi.nlm.nih.gov/pubmed/23578724>.

105. Gunderson LL, Winter KA, Ajani JA, et al. Long-term update of US GI Intergroup RTOG 98-11 phase III trial for anal carcinoma: survival, relapse, and colostomy failure with concurrent chemoradiation involving fluorouracil/mitomycin versus fluorouracil/cisplatin. *J Clin Oncol* 2012;30:4344-4351. Available at:

<http://www.ncbi.nlm.nih.gov/pubmed/23150707>.

106. Eng C, Crane CH, Rodriguez-Bigas MA. Should cisplatin be avoided in the treatment of locally advanced squamous cell carcinoma of the anal canal? *Nat Clin Pract Gastroenterol Hepatol* 2009;6:16-17.

Available at: <http://www.ncbi.nlm.nih.gov/pubmed/19047998>.

107. Abbas A, Yang G, Fakhri M. Management of anal cancer in 2010. Part 2: current treatment standards and future directions. *Oncology (Williston Park)* 2010;24:417-424. Available at:

<http://www.ncbi.nlm.nih.gov/pubmed/20480740>.

108. Conroy T, Ducreux M, Lemanski C, et al. Treatment intensification by induction chemotherapy (ICT) and radiation dose escalation in locally advanced squamous cell anal canal carcinoma (LAAC): Definitive analysis of the intergroup ACCORD 03 trial [abstract]. *J Clin Oncol* 2009;27 (suppl 15s):4033. Available at:

<http://meetinglibrary.asco.org/content/34304-65>.

109. Peiffert D, Tournier-Rangard L, Gerard JP, et al. Induction chemotherapy and dose intensification of the radiation boost in locally advanced anal canal carcinoma: final analysis of the randomized UNICANCER ACCORD 03 trial. *J Clin Oncol* 2012;30:1941-1948.

Available at: <http://www.ncbi.nlm.nih.gov/pubmed/22529257>.

110. Spithoff K, Cummings B, Jonker D, et al. Chemoradiotherapy for squamous cell cancer of the anal canal: a systematic review. *Clin Oncol (R Coll Radiol)* 2014;26:473-487. Available at:

<http://www.ncbi.nlm.nih.gov/pubmed/24721444>.

111. Moureau-Zabotto L, Viret F, Giovaninni M, et al. Is neoadjuvant chemotherapy prior to radio-chemotherapy beneficial in T4 anal

carcinoma? *J Surg Oncol* 2011;104:66-71. Available at:

<http://www.ncbi.nlm.nih.gov/pubmed/21240983>.

112. Sebag-Montefiore D, Meadows HM, Cunningham D, et al. Three cytotoxic drugs combined with pelvic radiation and as maintenance chemotherapy for patients with squamous cell carcinoma of the anus (SCCA): long-term follow-up of a phase II pilot study using 5-fluorouracil, mitomycin C and cisplatin. *Radiother Oncol* 2012;104:155-160. Available at: <http://www.ncbi.nlm.nih.gov/pubmed/22857859>.

113. Eng C, Chang GJ, Das P, et al. Phase II study of capecitabine and oxaliplatin with concurrent radiation therapy (XELOX-XRT) for squamous cell carcinoma of the anal canal. *ASCO Meeting Abstracts* 2009;27:4116. Available at:

<http://meeting.ascopubs.org/cgi/content/abstract/27/15S/4116>.

114. Package Insert. Cetuximab (Erbix®). Branchburg, NJ: ImClone Systems Incorporated; 2015. Available at:

[http://www.accessdata.fda.gov/drugsatfda\\_docs/label/2015/125084s262lbl.pdf](http://www.accessdata.fda.gov/drugsatfda_docs/label/2015/125084s262lbl.pdf). Accessed April 26, 2016.

115. Van Damme N, Deron P, Van Roy N, et al. Epidermal growth factor receptor and K-RAS status in two cohorts of squamous cell carcinomas. *BMC Cancer* 2010;10:189. Available at:

<http://www.ncbi.nlm.nih.gov/pubmed/20459770>.

116. Zampino MG, Magni E, Sonzogni A, Renne G. K-ras status in squamous cell anal carcinoma (SCC): it's time for target-oriented treatment? *Cancer Chemother Pharmacol* 2009;65:197-199. Available at:

<http://www.ncbi.nlm.nih.gov/pubmed/19727729>.

117. Garg M, Lee JY, Kachnic LA, et al. Phase II trials of cetuximab (CX) plus cisplatin (CDDP), 5-fluorouracil (5-FU) and radiation (RT) in immunocompetent (ECOG 3205) and HIV-positive (AMC045) patients with squamous cell carcinoma of the anal canal (SCAC): Safety and preliminary efficacy results [abstract]. *ASCO Meeting Abstracts* 2012;30:4030. Available at:

[http://meeting.ascopubs.org/cgi/content/abstract/30/15\\_suppl/4030](http://meeting.ascopubs.org/cgi/content/abstract/30/15_suppl/4030).



118. Deutsch E, Lemanski C, Pignon JP, et al. Unexpected toxicity of cetuximab combined with conventional chemoradiotherapy in patients with locally advanced anal cancer: results of the UNICANCER ACCORD 16 phase II trial. *Ann Oncol* 2013;24:2834-2838. Available at: <http://www.ncbi.nlm.nih.gov/pubmed/24026540>.

119. Levy A, Azria D, Pignon JP, et al. Low response rate after cetuximab combined with conventional chemoradiotherapy in patients with locally advanced anal cancer: long-term results of the UNICANCER ACCORD 16 phase II trial. *Radiother Oncol* 2015;114:415-416. Available at: <http://www.ncbi.nlm.nih.gov/pubmed/25769380>.

120. Olivatto LO, Vieira FM, Pereira BV, et al. Phase 1 study of cetuximab in combination with 5-fluorouracil, cisplatin, and radiotherapy in patients with locally advanced anal canal carcinoma. *Cancer* 2013;119:2973-2980. Available at: <http://www.ncbi.nlm.nih.gov/pubmed/23674135>.

121. Ortholan C, Ramaioli A, Peiffert D, et al. Anal canal carcinoma: early-stage tumors < or =10 mm (T1 or Tis): therapeutic options and original pattern of local failure after radiotherapy. *Int J Radiat Oncol Biol Phys* 2005;62:479-485. Available at: <http://www.ncbi.nlm.nih.gov/pubmed/15890590>.

122. Ferrigno R, Nakamura RA, Dos Santos Novaes PER, et al. Radiochemotherapy in the conservative treatment of anal canal carcinoma: retrospective analysis of results and radiation dose effectiveness. *Int J Radiat Oncol Biol Phys* 2005;61:1136-1142. Available at: <http://www.ncbi.nlm.nih.gov/pubmed/15752894>.

123. Huang K, Haas-Kogan D, Weinberg V, Krieg R. Higher radiation dose with a shorter treatment duration improves outcome for locally advanced carcinoma of anal canal. *World J Gastroenterol* 2007;13:895-900. Available at: <http://www.ncbi.nlm.nih.gov/pubmed/17352019>.

124. John M, Pajak T, Flam M, et al. Dose escalation in chemoradiation for anal cancer: preliminary results of RTOG 92-08. *Cancer J Sci Am*

1996;2:205-211. Available at: <http://www.ncbi.nlm.nih.gov/pubmed/9166533>.

125. Konski A, Garcia M, Jr., John M, et al. Evaluation of planned treatment breaks during radiation therapy for anal cancer: update of RTOG 92-08. *Int J Radiat Oncol Biol Phys* 2008;72:114-118. Available at: <http://www.ncbi.nlm.nih.gov/pubmed/18472363>.

126. Ben-Josef E, Moughan J, Ajani JA, et al. Impact of overall treatment time on survival and local control in patients with anal cancer: a pooled data analysis of Radiation Therapy Oncology Group trials 87-04 and 98-11. *J Clin Oncol* 2010;28:5061-5066. Available at: <http://www.ncbi.nlm.nih.gov/pubmed/20956625>.

127. Graf R, Wust P, Hildebrandt B, et al. Impact of overall treatment time on local control of anal cancer treated with radiochemotherapy. *Oncology* 2003;65:14-22. Available at: <http://www.ncbi.nlm.nih.gov/pubmed/12837978>.

128. Roohipour R, Patil S, Goodman KA, et al. Squamous-cell carcinoma of the anal canal: predictors of treatment outcome. *Dis Colon Rectum* 2008;51:147-153. Available at: <http://www.ncbi.nlm.nih.gov/pubmed/18180997>.

129. Allal AS, Sprangers MA, Laurencet F, et al. Assessment of long-term quality of life in patients with anal carcinomas treated by radiotherapy with or without chemotherapy. *Br J Cancer* 1999;80:1588-1594. Available at: <http://www.ncbi.nlm.nih.gov/pubmed/10408404>.

130. de Bree E, van Ruth S, Dewit LGH, Zoetmulder FAN. High risk of colostomy with primary radiotherapy for anal cancer. *Ann Surg Oncol* 2007;14:100-108. Available at: <http://www.ncbi.nlm.nih.gov/pubmed/17066231>.

131. Baxter NN, Habermann EB, Tepper JE, et al. Risk of pelvic fractures in older women following pelvic irradiation. *JAMA* 2005;294:2587-2593. Available at: <http://www.ncbi.nlm.nih.gov/pubmed/16304072>.

132. Call JA, Prendergast BM, Jensen LG, et al. Intensity-modulated radiation therapy for anal cancer: results from a multi-institutional retrospective cohort study. *Am J Clin Oncol* 2014. Available at: <http://www.ncbi.nlm.nih.gov/pubmed/24401669>.

133. Chen YJ, Liu A, Tsai PT, et al. Organ sparing by conformal avoidance intensity-modulated radiation therapy for anal cancer: dosimetric evaluation of coverage of pelvis and inguinal/femoral nodes. *Int J Radiat Oncol Biol Phys* 2005;63:274-281. Available at: <http://www.ncbi.nlm.nih.gov/pubmed/16111597>.

134. Chuong MD, Freilich JM, Hoffe SE, et al. Intensity-modulated radiation therapy vs. 3D conformal radiation therapy for squamous cell carcinoma of the anal canal. *Gastrointest Cancer Res* 2013;6:39-45. Available at: <http://www.ncbi.nlm.nih.gov/pubmed/23745158>.

135. DeFoe SG, Beriwal S, Jones H, et al. Concurrent chemotherapy and intensity-modulated radiation therapy for anal carcinoma--clinical outcomes in a large National Cancer Institute-designated integrated cancer centre network. *Clin Oncol (R Coll Radiol)* 2012;24:424-431. Available at: <http://www.ncbi.nlm.nih.gov/pubmed/22075444>.

136. Franco P, Mistrangelo M, Arcadipane F, et al. Intensity-modulated radiation therapy with simultaneous integrated boost combined with concurrent chemotherapy for the treatment of anal cancer patients: 4-year results of a consecutive case series. *Cancer Invest* 2015;33:259-266. Available at: <http://www.ncbi.nlm.nih.gov/pubmed/25950188>.

137. Kachnic LA, Tsai HK, Coen JJ, et al. Dose-painted intensity-modulated radiation therapy for anal cancer: a multi-institutional report of acute toxicity and response to therapy. *Int J Radiat Oncol Biol Phys* 2012;82:153-158. Available at: <http://www.ncbi.nlm.nih.gov/pubmed/21095071>.

138. Lin A, Ben-Josef E. Intensity-modulated radiation therapy for the treatment of anal cancer. *Clin Colorectal Cancer* 2007;6:716-719. Available at: <http://www.ncbi.nlm.nih.gov/pubmed/18039425>.

139. Milano MT, Jani AB, Farrey KJ, et al. Intensity-modulated radiation therapy (IMRT) in the treatment of anal cancer: toxicity and clinical outcome. *Int J Radiat Oncol Biol Phys* 2005;63:354-361. Available at: <http://www.ncbi.nlm.nih.gov/pubmed/16168830>.

140. Mitchell MP, Abboud M, Eng C, et al. Intensity-modulated radiation therapy with concurrent chemotherapy for anal cancer: outcomes and toxicity. *Am J Clin Oncol* 2014;37:461-466. Available at: <http://www.ncbi.nlm.nih.gov/pubmed/23466576>.

141. Salama JK, Mell LK, Schomas DA, et al. Concurrent chemotherapy and intensity-modulated radiation therapy for anal canal cancer patients: a multicenter experience. *J Clin Oncol* 2007;25:4581-4586. Available at: <http://www.ncbi.nlm.nih.gov/pubmed/17925552>.

142. Yates A, Carroll S, Kneebone A, et al. Implementing intensity-modulated radiotherapy with simultaneous integrated boost for anal cancer: 3 year outcomes at two Sydney institutions. *Clin Oncol (R Coll Radiol)* 2015;27:700-707. Available at: <http://www.ncbi.nlm.nih.gov/pubmed/26382849>.

143. Bazan JG, Hara W, Hsu A, et al. Intensity-modulated radiation therapy versus conventional radiation therapy for squamous cell carcinoma of the anal canal. *Cancer* 2011;117:3342-3351. Available at: <http://www.ncbi.nlm.nih.gov/pubmed/21287530>.

144. Rothenstein DA, Dasgupta T, Chou JF, et al. Comparison of outcomes of intensity-modulated radiotherapy and 3-D conformal radiotherapy for anal squamous cell carcinoma using a propensity score analysis [abstract]. *J Clin Oncol* 2011;29 (suppl):3555. Available at: <http://meetinglibrary.asco.org/content/78333-102>.

145. Kachnic LA, Winter K, Myerson RJ, et al. RTOG 0529: a phase 2 evaluation of dose-painted intensity modulated radiation therapy in combination with 5-fluorouracil and mitomycin-C for the reduction of acute morbidity in carcinoma of the anal canal. *Int J Radiat Oncol Biol Phys* 2013;86:27-33. Available at: <http://www.ncbi.nlm.nih.gov/pubmed/23154075>.



146. Benson AB, 3rd, Arnoletti JP, Bekaii-Saab T, et al. Anal Carcinoma, Version 2.2012: featured updates to the NCCN guidelines. *J Natl Compr Canc Netw* 2012;10:449-454. Available at: <http://www.ncbi.nlm.nih.gov/pubmed/22491045>.

147. Myerson RJ, Garofalo MC, El Naqa I, et al. Elective clinical target volumes for conformal therapy in anorectal cancer: a radiation therapy oncology group consensus panel contouring atlas. *Int J Radiat Oncol Biol Phys* 2009;74:824-830. Available at: <http://www.ncbi.nlm.nih.gov/pubmed/19117696>.

148. Cunin L, Alfa-Wali M, Turner J, et al. Salvage surgery for residual primary and locally recurrent anal squamous cell carcinoma after chemoradiotherapy in HIV-positive individuals. *Ann Surg Oncol* 2014;21:527-532. Available at: <http://www.ncbi.nlm.nih.gov/pubmed/24242676>.

149. Fraunholz IB, Haberl A, Klauke S, et al. Long-term effects of chemoradiotherapy for anal cancer in patients with HIV infection: oncological outcomes, immunological status, and the clinical course of the HIV disease. *Dis Colon Rectum* 2014;57:423-431. Available at: <http://www.ncbi.nlm.nih.gov/pubmed/24608297>.

150. Fraunholz I, Weiss C, Eberlein K, et al. Concurrent chemoradiotherapy with 5-fluorouracil and mitomycin C for invasive anal carcinoma in human immunodeficiency virus-positive patients receiving highly active antiretroviral therapy. *Int J Radiat Oncol Biol Phys* 2010;76:1425-1432. Available at: <http://www.ncbi.nlm.nih.gov/pubmed/19744801>.

151. Hoffman R, Welton ML, Klencke B, et al. The significance of pretreatment CD4 count on the outcome and treatment tolerance of HIV-positive patients with anal cancer. *Int J Radiat Oncol Biol Phys* 1999;44:127-131. Available at: <http://www.ncbi.nlm.nih.gov/pubmed/10219805>.

152. Grew D, Bitterman D, Leichman CG, et al. HIV infection is associated with poor outcomes for patients with anal cancer in the

highly active antiretroviral therapy era. *Dis Colon Rectum* 2015;58:1130-1136. Available at: <http://www.ncbi.nlm.nih.gov/pubmed/26544809>.

153. Oehler-Janne C, Huguet F, Provencher S, et al. HIV-specific differences in outcome of squamous cell carcinoma of the anal canal: a multicentric cohort study of HIV-positive patients receiving highly active antiretroviral therapy. *J Clin Oncol* 2008;26:2550-2557. Available at: <http://www.ncbi.nlm.nih.gov/pubmed/18427149>.

154. Chiao EY, Giordano TP, Richardson P, El-Serag HB. Human immunodeficiency virus-associated squamous cell cancer of the anus: epidemiology and outcomes in the highly active antiretroviral therapy era. *J Clin Oncol* 2008;26:474-479. Available at: <http://www.ncbi.nlm.nih.gov/pubmed/18202423>.

155. Seo Y, Kinsella MT, Reynolds HL, et al. Outcomes of chemoradiotherapy with 5-Fluorouracil and mitomycin C for anal cancer in immunocompetent versus immunodeficient patients. *Int J Radiat Oncol Biol Phys* 2009;75:143-149. Available at: <http://www.ncbi.nlm.nih.gov/pubmed/19203845>.

156. White EC, Khodayari B, Erickson KT, et al. Comparison of toxicity and treatment outcomes in HIV-positive versus HIV-negative patients with squamous cell carcinoma of the anal canal. *Am J Clin Oncol* 2014. Available at: <http://www.ncbi.nlm.nih.gov/pubmed/25513996>.

157. Coghill AE, Shiels MS, Suneja G, Engels EA. Elevated cancer-specific mortality among HIV-infected patients in the United States. *J Clin Oncol* 2015;33:2376-2383. Available at: <http://www.ncbi.nlm.nih.gov/pubmed/26077242>.

158. Duncan KC, Chan KJ, Chiu CG, et al. HAART slows progression to anal cancer in HIV-infected MSM. *AIDS* 2015;29:305-311. Available at: <http://www.ncbi.nlm.nih.gov/pubmed/25686679>.



159. Klencke BJ, Palefsky JM. Anal cancer: an HIV-associated cancer. *Hematol Oncol Clin North Am* 2003;17:859-872. Available at: <http://www.ncbi.nlm.nih.gov/pubmed/12852659>.
160. Faivre C, Rougier P, Ducreux M, et al. [5-fluorouracil and cisplatin combination chemotherapy for metastatic squamous-cell anal cancer]. *Bull Cancer* 1999;86:861-865. Available at: <http://www.ncbi.nlm.nih.gov/pubmed/10572237>.
161. Cummings BJ. Metastatic anal cancer: the search for cure. *Onkologie* 2006;29:5-6. Available at: <http://www.ncbi.nlm.nih.gov/pubmed/16514247>.
162. Ajani JA, Carrasco CH, Jackson DE, Wallace S. Combination of cisplatin plus fluoropyrimidine chemotherapy effective against liver metastases from carcinoma of the anal canal. *Am J Med* 1989;87:221-224. Available at: <http://www.ncbi.nlm.nih.gov/pubmed/2527006>.
163. Eng C, Chang GJ, You YN, et al. The role of systemic chemotherapy and multidisciplinary management in improving the overall survival of patients with metastatic squamous cell carcinoma of the anal canal. *Oncotarget* 2014;5:11133-11142. Available at: <http://www.ncbi.nlm.nih.gov/pubmed/25373735>.
164. Jaiyesimi IA, Pazdur R. Cisplatin and 5-fluorouracil as salvage therapy for recurrent metastatic squamous cell carcinoma of the anal canal. *Am J Clin Oncol* 1993;16:536-540. Available at: <http://www.ncbi.nlm.nih.gov/pubmed/8256774>.
165. Kim S, Jary M, Mansi L, et al. DCF (docetaxel, cisplatin and 5-fluorouracil) chemotherapy is a promising treatment for recurrent advanced squamous cell anal carcinoma. *Ann Oncol* 2013;24:3045-3050. Available at: <http://www.ncbi.nlm.nih.gov/pubmed/24114858>.
166. Kim R, Byer J, Fulp WJ, et al. Carboplatin and paclitaxel treatment is effective in advanced anal cancer. *Oncology* 2014;87:125-132. Available at: <http://www.ncbi.nlm.nih.gov/pubmed/25012155>.
167. Glynne-Jones R, James R, Meadows H, et al. Optimum time to assess complete clinical response (CR) following chemoradiation (CRT) using mitomycin (MMC) or cisplatin (CisP), with or without maintenance CisP/5FU in squamous cell carcinoma of the anus: Results of ACT II [abstract]. *ASCO Meeting Abstracts* 2012;30:4004. Available at: [http://meeting.ascopubs.org/cgi/content/abstract/30/15\\_suppl/4004](http://meeting.ascopubs.org/cgi/content/abstract/30/15_suppl/4004).
168. Schiller DE, Cummings BJ, Rai S, et al. Outcomes of salvage surgery for squamous cell carcinoma of the anal canal. *Ann Surg Oncol* 2007;14:2780-2789. Available at: <http://www.ncbi.nlm.nih.gov/pubmed/17638059>.
169. Mullen JT, Rodriguez-Bigas MA, Chang GJ, et al. Results of surgical salvage after failed chemoradiation therapy for epidermoid carcinoma of the anal canal. *Ann Surg Oncol* 2007;14:478-483. Available at: <http://www.ncbi.nlm.nih.gov/pubmed/17103253>.
170. Das P, Bhatia S, Eng C, et al. Predictors and patterns of recurrence after definitive chemoradiation for anal cancer. *Int J Radiat Oncol Biol Phys* 2007;68:794-800. Available at: <http://www.ncbi.nlm.nih.gov/pubmed/17379452>.
171. Sunesen KG, Norgaard M, Lundby L, et al. Cause-specific colostomy rates after radiotherapy for anal cancer: a danish multicentre cohort study. *J Clin Oncol* 2011;29:3535-3540. Available at: <http://www.ncbi.nlm.nih.gov/pubmed/21825256>.
172. Ozsahin M, Santa Cruz O, Bouchaab H, et al. Definitive organ-sparing treatment of anal canal cancer: can we afford to question it? *J Clin Oncol* 2012;30:673-674; author reply 674-675. Available at: <http://www.ncbi.nlm.nih.gov/pubmed/22278906>.
173. Allal AS, Laurencet FM, Reymond MA, et al. Effectiveness of surgical salvage therapy for patients with locally uncontrolled anal carcinoma after sphincter-conserving treatment. *Cancer* 1999;86:405-409. Available at: <http://www.ncbi.nlm.nih.gov/pubmed/10430247>.



174. Ellenhorn JD, Enker WE, Quan SH. Salvage abdominoperineal resection following combined chemotherapy and radiotherapy for epidermoid carcinoma of the anus. *Ann Surg Oncol* 1994;1:105-110. Available at: <http://www.ncbi.nlm.nih.gov/pubmed/7834434>.

175. Nilsson PJ, Svensson C, Goldman S, Glimelius B. Salvage abdominoperineal resection in anal epidermoid cancer. *Br J Surg* 2002;89:1425-1429. Available at: <http://www.ncbi.nlm.nih.gov/pubmed/12390386>.

176. Chessin DB, Hartley J, Cohen AM, et al. Rectus flap reconstruction decreases perineal wound complications after pelvic chemoradiation and surgery: a cohort study. *Ann Surg Oncol* 2005;12:104-110. Available at: <http://www.ncbi.nlm.nih.gov/pubmed/15827789>.

177. Wright JL, Gollub MJ, Weiser MR, et al. Surgery and high-dose-rate intraoperative radiation therapy for recurrent squamous-cell carcinoma of the anal canal. *Dis Colon Rectum* 2011;54:1090-1097. Available at: <http://www.ncbi.nlm.nih.gov/pubmed/21825888>.

178. Lefevre JH, Corte H, Tiret E, et al. Abdominoperineal resection for squamous cell anal carcinoma: survival and risk factors for recurrence. *Ann Surg Oncol* 2012;19:4186-4192. Available at: <http://www.ncbi.nlm.nih.gov/pubmed/22825769>.

179. Harris DA, Williamson J, Davies M, et al. Outcome of salvage surgery for anal squamous cell carcinoma. *Colorectal Dis* 2013;15:968-973. Available at: <http://www.ncbi.nlm.nih.gov/pubmed/23522325>.