

NCCN Clinical Practice Guidelines in Oncology (NCCN Guidelines®)

Bone Cancer

Version 2.2016

NCCN.org

Continue



National
Comprehensive
Cancer
Network®

NCCN Guidelines Version 2.2016 Panel Members

Bone Cancer

[NCCN Guidelines Index](#)
[Bone Cancer Table of Contents](#)
[Discussion](#)

***J. Sybil Biermann, MD/Chair ¶ τ**
University of Michigan
Comprehensive Cancer Center

***Warren Chow, MD/Vice-Chair † ‡**
City of Hope Comprehensive
Cancer Center

Douglas R. Adkins, MD †
Siteman Cancer Center
at Barnes-Jewish Hospital
and Washington University
School of Medicine

Mark Agulnik, MD †
Robert H. Lurie Comprehensive Cancer
Center of Northwestern University

Robert S. Benjamin, MD †
The University of Texas
MD Anderson Cancer Center

Brian Brigman, MD, PhD ¶ τ
Duke Cancer Institute

William T. Curry, MD ¶
Massachusetts General Hospital
Cancer Center

Nicola Fabbri, MD
Memorial Sloan Kettering Cancer Center

NCCN
Mary Anne Bergman
Jillian Scavone, PhD

Suzanne George, MD †
Dana-Farber Cancer Institute

Kenneth R. Hande, MD †
Vanderbilt-Ingram Cancer Center

Francis J. Hornicek, MD, PhD τ €
Massachusetts General Hospital
Cancer Center

Anna Kulidjian, MD, MSc ¶ τ
UC San Diego Moores Cancer Center

Dieter Lindskog, MD
Yale Cancer Center/
Smilow Cancer Hospital

Joel Mayerson, MD ¶ τ
The Ohio State University
Comprehensive Cancer Center -
James Cancer Hospital and
Solove Research Institute

Sean V. McGarry, MD τ
Fred & Pamela Buffett Cancer Center

Brian McGrath, MD
Roswell Park Cancer Institute

Lynn Million, MD §
Stanford Cancer Institute

Carol D. Morris, MD, MS ¶ τ
The Sidney Kimmel Comprehensive
Cancer Center at Johns Hopkins

Sujana Movva, MD †
Fox Chase Cancer Center

Richard J. O'Donnell, MD ¶ τ
UCSF Helen Diller Family
Comprehensive Cancer Center

R. Lor Randall, MD ¶ τ
Huntsman Cancer Institute
at the University of Utah

Damon R. Reed, MD €
Moffitt Cancer Center

Peter Rose, MD τ
Mayo Clinic Cancer Center

Victor M. Santana, MD €
St. Jude Children's Research Hospital/The
University of Tennessee Health Science Center

Robert L. Satcher, MD, PhD ¶ τ
The University of Texas
MD Anderson Cancer Center

Herrick J. Siegel, MD ¶ τ
University of Alabama at Birmingham
Comprehensive Cancer Center

Victor Villalobos, MD, PhD †
University of Colorado Cancer Center

¶ Surgery/Surgical oncology
† Medical oncology
‡ Hematology/Hematology oncology
§ Radiotherapy/Radiation oncology
τ Orthopedics
€ Pediatric oncology

*Discussion Section Writing Committee

Continue

[NCCN Guidelines Panel Disclosures](#)



[NCCN Bone Cancer Panel Members](#) [Summary of the Guidelines Updates](#)

[Multidisciplinary Team \(TEAM-1\)](#) [Bone Cancer Workup \(BONE-1\)](#)

Chondrosarcoma:

- [Presentation and Primary Treatment \(CHON-1\)](#)

Chordoma:

- [Workup and Histologic Subtype \(CHOR-1\)](#)
- [Presentation and Primary Treatment \(CHOR-2\)](#)
- [Surveillance and Recurrence \(CHOR-3\)](#)

Ewing's Sarcoma Family of Tumors:

- [Workup and Primary Treatment \(EW-1\)](#)
- [Adjuvant Treatment, Surveillance, and Relapse \(EW-2\)](#)

Giant Cell Tumor of the Bone:

- [Workup and Presentation \(GCTB-1\)](#)
- [Primary Treatment \(GCTB-2\)](#)
- [Surveillance \(GCTB-3\)](#)

Osteosarcoma:

- [Workup and Primary Treatment \(OSTEO-1\)](#)
- [Neoadjuvant and Adjuvant Treatment \(OSTEO-2\)](#)
- [Metastatic Disease \(OSTEO-3\)](#)
- [Surveillance and Relapse \(OSTEO-4\)](#)

[Principles of Bone Cancer Management \(BONE-A\)](#) [Bone Cancer Systemic Therapy Agents \(BONE-B\)](#) [Principles of Radiation Therapy \(BONE-C\)](#) [Staging \(ST-1\)](#)

Clinical Trials: NCCN believes that the best management for any cancer patient is in a clinical trial. Participation in clinical trials is especially encouraged.

To find clinical trials online at NCCN Member Institutions, [click here: nccn.org/clinical_trials/physician.html](http://nccn.org/clinical_trials/physician.html).

NCCN Categories of Evidence and Consensus: All recommendations are category 2A unless otherwise specified.

See [NCCN Categories of Evidence and Consensus](#).

The NCCN Guidelines® are a statement of evidence and consensus of the authors regarding their views of currently accepted approaches to treatment. Any clinician seeking to apply or consult the NCCN Guidelines is expected to use independent medical judgment in the context of individual clinical circumstances to determine any patient's care or treatment. The National Comprehensive Cancer Network® (NCCN®) makes no representations or warranties of any kind regarding their content, use or application and disclaims any responsibility for their application or use in any way. The NCCN Guidelines are copyrighted by National Comprehensive Cancer Network®. All rights reserved. The NCCN Guidelines and the illustrations herein may not be reproduced in any form without the express written permission of NCCN. ©2015.



Updates in Version 2.2016 of the NCCN Guidelines for Bone Cancer from Version 1.2016 include:

[MS-1](#)

- The Discussion section was updated to reflect the changes in the algorithm.

Updates in Version 1.2016 of the NCCN Guidelines for Bone Cancer from Version 1.2015 include:

Multidisciplinary Team:

[TEAM-1](#)

- Formerly BONE-A, this page has been renamed and is now the first page of the guidelines.

Bone Cancer:

[BONE-1](#)

- "Painful" has been replaced with "Symptomatic bone lesion" and corresponding footnote "a" has been modified: "See Multidisciplinary Team (TEAM-1)."

Chondrosarcoma:

[CHON-1](#)

- Under Primary Treatment, "This management should be restricted to extremity tumors (not pelvic tumors)" is a new footnote corresponding to "Intralesional excision."

Ewing's Sarcoma Family of Tumors:

[EW-1](#)

- 5th bullet under Workup has been modified: "Bone marrow biopsy and/or screening MRI of spine and pelvis"
 - ▶ 6th bullet: "Strongly consider" has been deleted.

Osteosarcoma:

[OSTEO-2](#)

- Under Adjuvant Treatment:
 - ▶ "Consider changing chemotherapy" has changed from a category 2A to a category 2B. A new footnote corresponds directing the reader to "see discussion for further information."

[OSTEO-4](#)

- 5th column "Radium 223 dichloride (Ra 223)" is new to the page with the following references:
 - ▶ "Subbiah V; Anderson PM; Rohren E. Alpha Emitter Radium 223 in High-Risk Osteosarcoma: First Clinical Evidence of Response and Blood-Brain Barrier Penetration. *JAMA Oncol* 2015;1(2):253-255"
 - ▶ "Anderson PM; Subbiah V; Rohren E. Bone-seeking radiopharmaceuticals as targeted agents of osteosarcoma: Samarium-153-EDTMP and Radium-223. *Adv Exp Med Biol* 2014;804:291-304"
 - ▶ "Subbiah V; Rohren E; Huh WW; Kappadath CS; Anderson PM. Phase 1 dose escalation trial of intravenous radium 223 dichloride alpha-particle therapy in osteosarcoma. *J Clin Oncol* 2014;32(5s): Abstract TPS10600"

Bone Cancer Systemic Therapy Agents:

[BONE-B](#)

- Under Ewing's Sarcoma:
 - ▶ Ifosfamide "(high dose) ±" and (was added to "etoposide") with the following new reference: *Magnan H, Goodbody CM, Riedel E, et al. Ifosfamide dose-intensification for patients with metastatic Ewing sarcoma. *Pediatr Blood Cancer* 2015;62(4):594-7.*
- Under Osteosarcoma
 - ▶ Ifosfamide "(high dose) ±" and (was added to "etoposide") with the following new reference: *Goorin AM, Harris MB, Bernstein M, et al. Phase II/III trial of etoposide and high-dose ifosfamide in newly diagnosed metastatic osteosarcoma: a pediatric oncology group trial. *J Clin Oncol* 2002;20(2):426-33. <http://www.ncbi.nlm.nih.gov/pubmed/11786570>.*
 - ▶ "Radium-223" is new to the page. See references for OSTEO-4.
 - ▶ "Sorafenib + everolimus" (was added) with the following new reference: *Grignani G, Palmerini E, Ferraresi V, et al. Sorafenib and everolimus for patients with unresectable high-grade osteosarcoma progressing after standard treatment: a non-randomised phase 2 clinical trial. *Lancet Oncol* 2015;16(1):90-107.*

Note: All recommendations are category 2A unless otherwise indicated.

Clinical Trials: NCCN believes that the best management of any cancer patient is in a clinical trial. Participation in clinical trials is especially encouraged.

MULTIDISCIPLINARY TEAM

Primary bone tumors and selected metastatic tumors should be evaluated and treated by a multidisciplinary team with expertise in the management of these tumors. The team should meet on a regular basis and should include:

Core Group

- **Musculoskeletal oncologist**
- **Bone pathologist**
- **Medical/pediatric oncologist**
- **Radiation oncologist**
- **Musculoskeletal radiologist**

Specialists Critical in Certain Cases

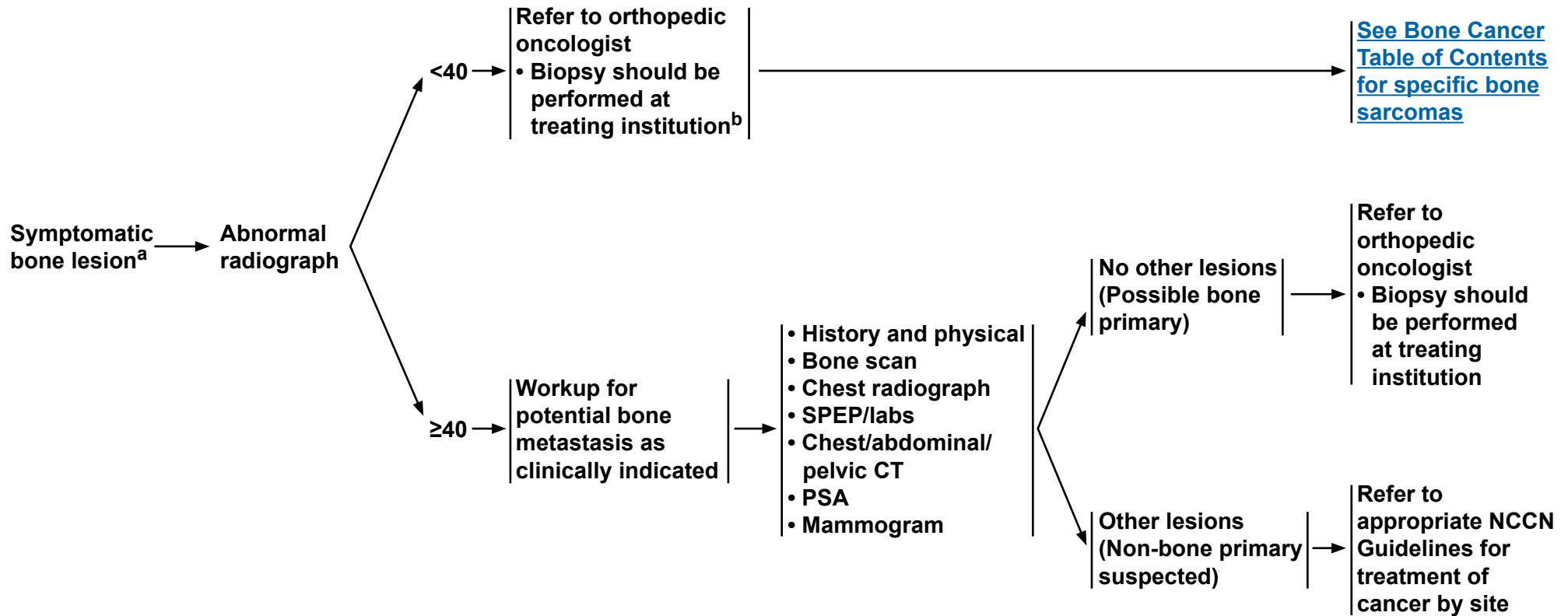
- **Thoracic surgeon**
- **Plastic surgeon**
- **Interventional radiologist**
- **Physiatrist**
- **Vascular/general surgeon**
- **Neurosurgeon**
- **Additional surgical subspecialties as clinically indicated**

Note: All recommendations are category 2A unless otherwise indicated.

Clinical Trials: NCCN believes that the best management of any cancer patient is in a clinical trial. Participation in clinical trials is especially encouraged.



WORKUP



^aSee Multidisciplinary Team (TEAM-1).

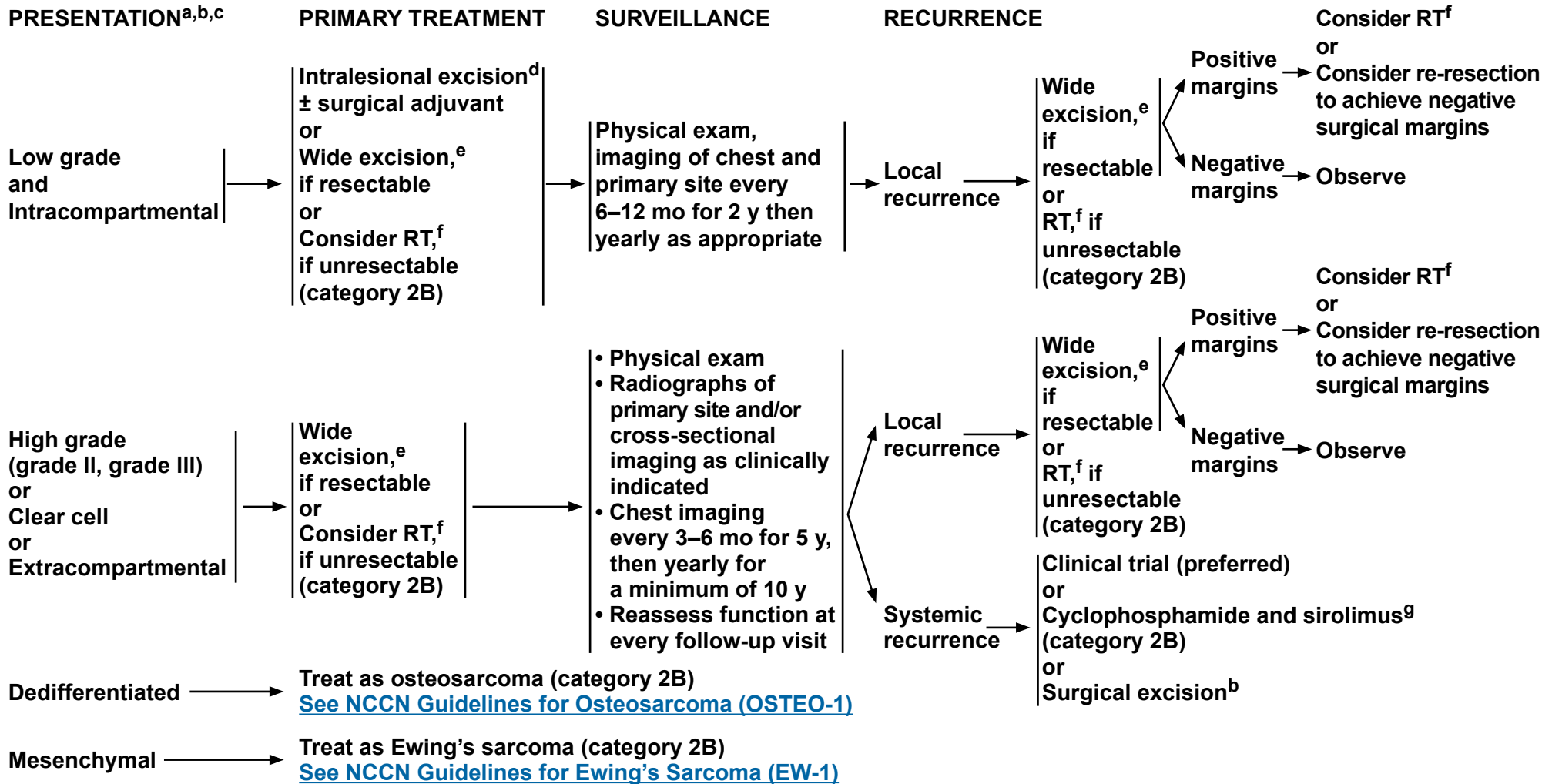
^bSee Principles of Bone Cancer Management (BONE-A).

Note: All recommendations are category 2A unless otherwise indicated.
Clinical Trials: NCCN believes that the best management of any cancer patient is in a clinical trial. Participation in clinical trials is especially encouraged.



NCCN Guidelines Version 2.2016

Chondrosarcoma



^aSee [Multidisciplinary Team \(TEAM-1\)](#).

^bSee [Principles of Bone Cancer Management \(BONE-A\)](#).

^cThere is considerable controversy regarding the grading of chondrosarcoma. In addition to histology, radiologic features, size, and location of tumors should also be considered in deciding local treatment.

^dThis management should be restricted to extremity tumors (not pelvic tumors).

^eWide excision should provide histologically negative surgical margins. This may be achieved by either limb-sparing resection or limb amputation.

^fSee [Principles of Radiation Therapy \(BONE-C\)](#).

^gBernstein-Molho R, Kollender Y, Issakov J, et al. Clinical activity of mTOR inhibition in combination with cyclophosphamide in the treatment of recurrent unresectable chondrosarcomas. *Cancer Chemother Pharmacol.* 2012;70(6):855-860.

Note: All recommendations are category 2A unless otherwise indicated.

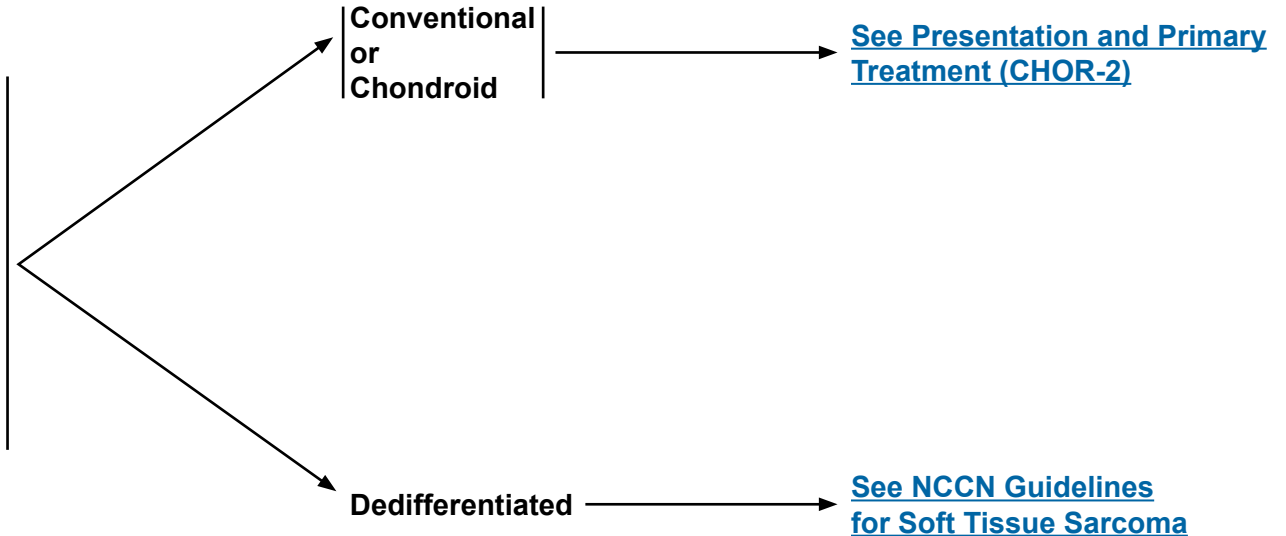
Clinical Trials: NCCN believes that the best management of any cancer patient is in a clinical trial. Participation in clinical trials is especially encouraged.



WORKUP^{a,b}

HISTOLOGIC SUBTYPE

- All patients should be evaluated and treated by a multidisciplinary team with expertise in the management of chordoma^a
- History and physical
- Adequate imaging (eg, x-ray, CT ± MRI) of primary site and screening MRI of spinal axis
- CT scan of chest, abdomen, and pelvis
- Consider PET scan
- Consider bone scan if PET is negative
- Biopsy to confirm histologic subtype^{b,c}



^aSee [Multidisciplinary Team \(TEAM-1\)](#).

^bSee [Principles of Bone Cancer Management \(BONE-A\)](#).

^cBiopsy should be done after imaging studies are completed; biopsy type may vary depending on anatomic location. Optimally, biopsy should be performed at a center of excellence where definitive management is given. Cord compression may limit surgical procedures.

Note: All recommendations are category 2A unless otherwise indicated.

Clinical Trials: NCCN believes that the best management of any cancer patient is in a clinical trial. Participation in clinical trials is especially encouraged.



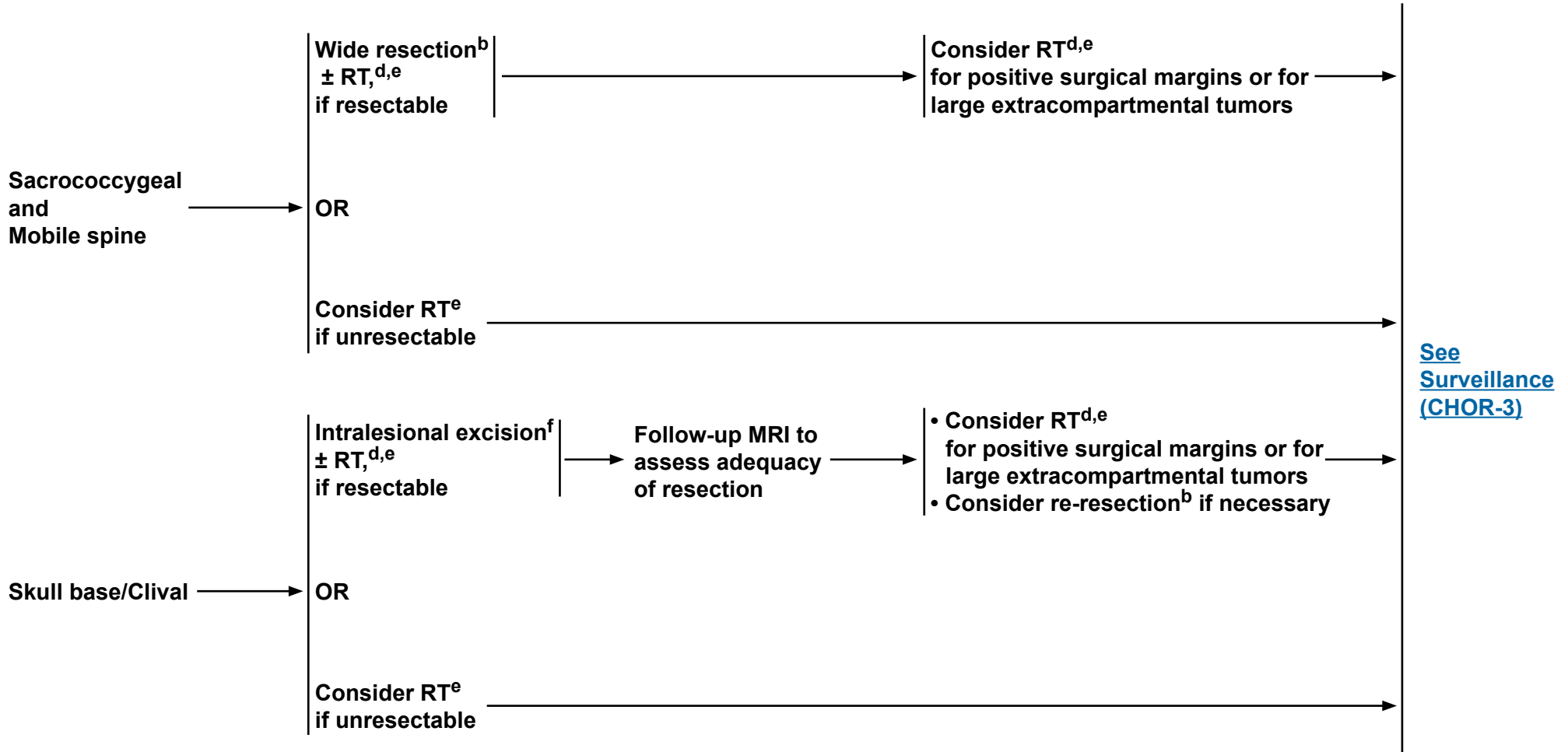
NCCN Guidelines Version 2.2016

Chordoma

PRESENTATION

PRIMARY TREATMENT

ADJUVANT TREATMENT



^bSee Principles of Bone Cancer Management (BONE-A).

^dRadiation therapy may be given preoperatively, intraoperatively, and/or postoperatively.

^eSee Principles of Radiation Therapy (BONE-C).

^fMaximal safe resection. Maximal tumor removal is recommended when appropriate.

Note: All recommendations are category 2A unless otherwise indicated.
Clinical Trials: NCCN believes that the best management of any cancer patient is in a clinical trial. Participation in clinical trials is especially encouraged.



NCCN Guidelines Version 2.2016

Chordoma

SURVEILLANCE

RECURRENCE

TREATMENT

- Physical exam
- Imaging (eg, x-ray, CT ± MRI) of surgical site as clinically indicated
- Chest imaging every 6 mo for 5 y, then annually thereafter
- Cross-sectional abdominal imaging annually

Local
recurrence

Surgical excision^b
and/or
RT^e
and/or
Systemic therapy^g

Metastatic
recurrence

Systemic therapy^g
and/or
Surgical excision^b
and/or
RT^e
and/or
Best supportive care

^bSee Principles of Bone Cancer Management (BONE-A).

^eSee Principles of Radiation Therapy (BONE-C).

^gSee Bone Cancer Systemic Therapy Agents (BONE-B).

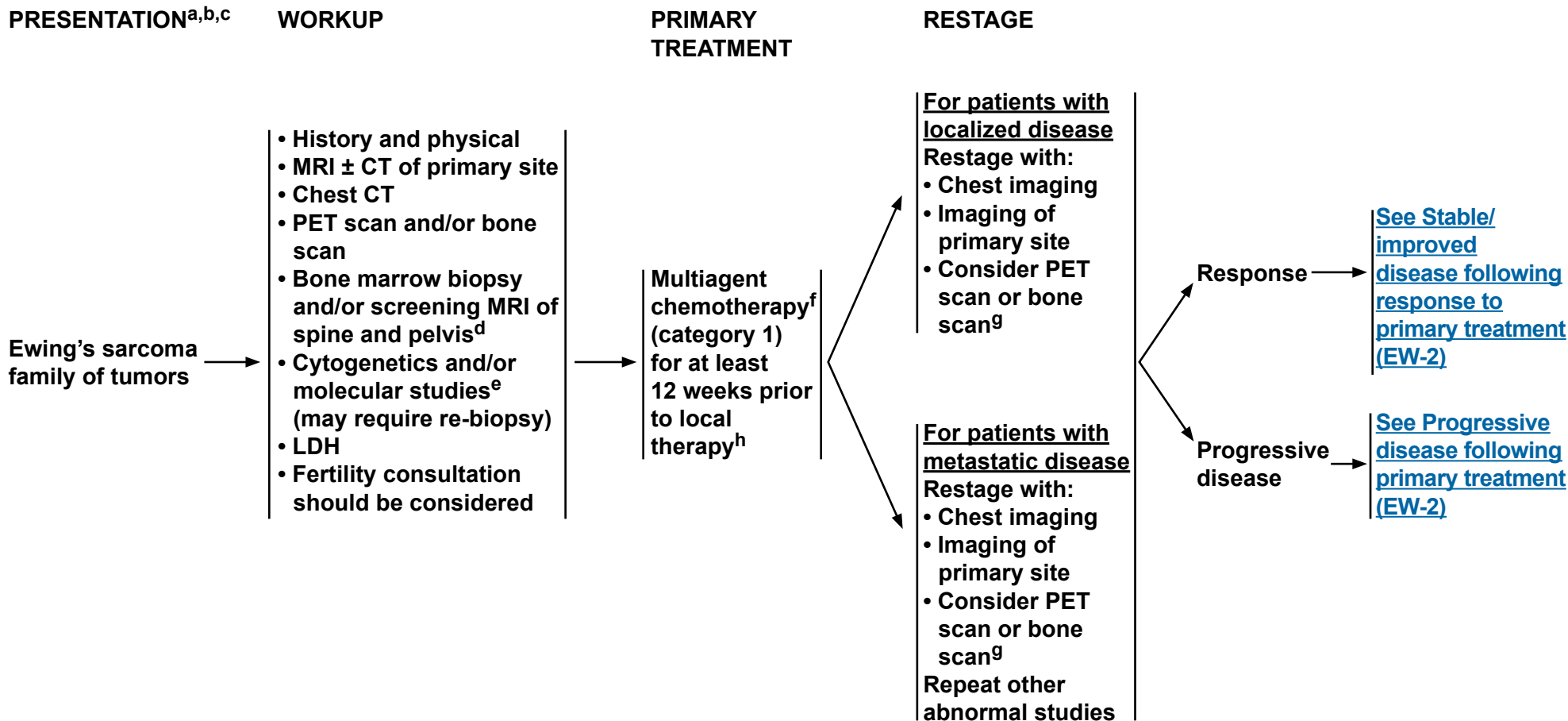
Note: All recommendations are category 2A unless otherwise indicated.

Clinical Trials: NCCN believes that the best management of any cancer patient is in a clinical trial. Participation in clinical trials is especially encouraged.



NCCN Guidelines Version 2.2016

Ewing's Sarcoma Family of Tumors



^aSee [Multidisciplinary Team \(TEAM-1\)](#).

^bSee [Principles of Bone Cancer Management \(BONE-A\)](#).

^cAny member of the Ewing's sarcoma family of tumors can be treated using this algorithm, including primitive neuroectodermal tumor (PNET) of bone, Askin's tumor, and extraosseous Ewing's sarcoma.

^dKumar J, Seith A, Kumar A, et al. Whole-body MR imaging with the use of parallel imaging for detection of skeletal metastases in pediatric patients with small cell neoplasms: comparison with skeletal scintigraphy and FDG PET/CT. *Pediatr Radiol* 2008;38:953-962. Epub 2008 Jul 18.

^e90% of Ewing's sarcoma family of tumors will have one of four specific cytogenetic translocations.

^fSee [Bone Cancer Systemic Therapy Agents \(BONE-B\)](#).

^gUse the same imaging technique that was performed in the initial workup.

^hLonger primary treatment duration can be considered in patients with metastatic disease based on response.

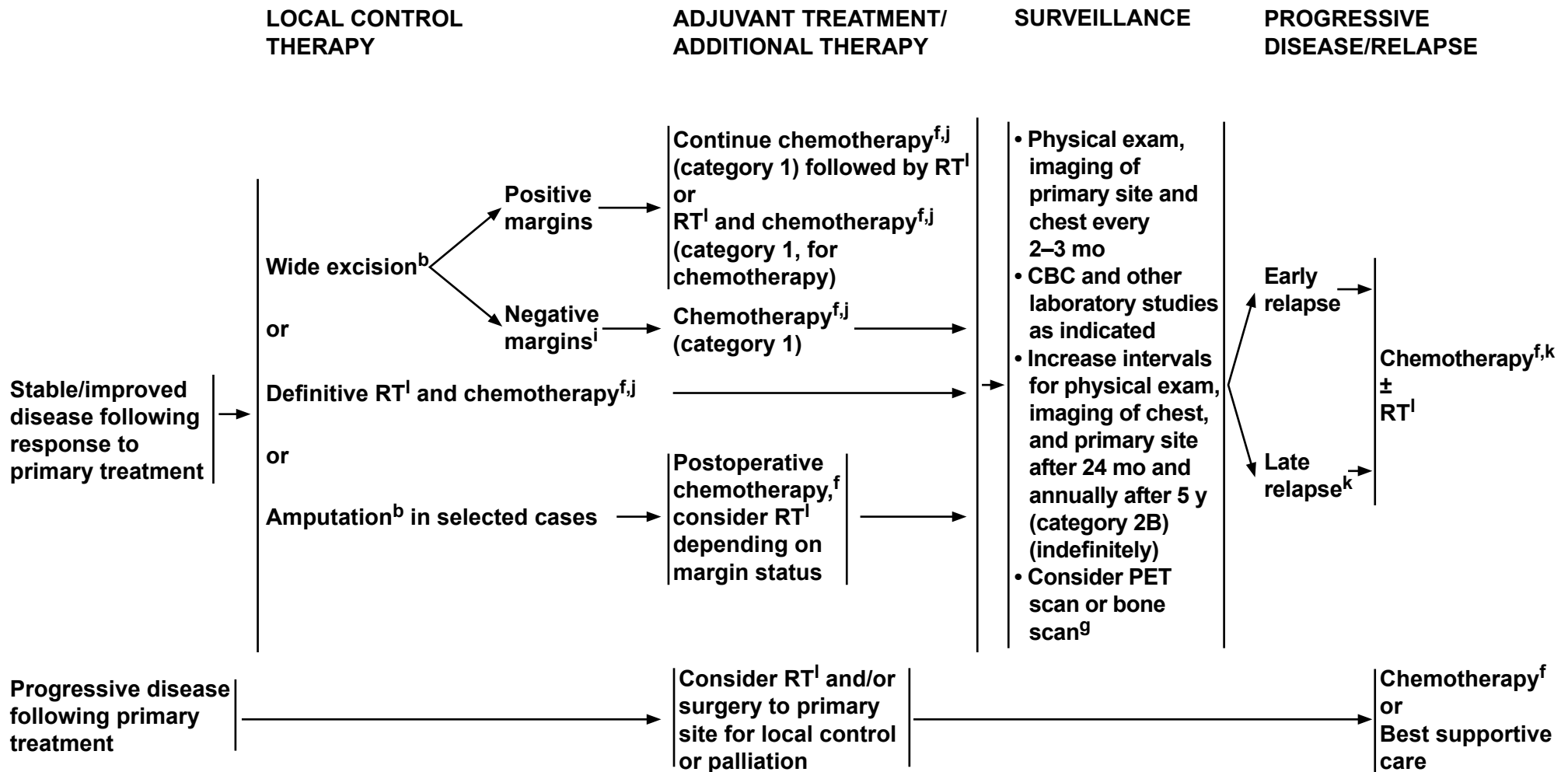
Note: All recommendations are category 2A unless otherwise indicated.

Clinical Trials: NCCN believes that the best management of any cancer patient is in a clinical trial. Participation in clinical trials is especially encouraged.



NCCN Guidelines Version 2.2016

Ewing's Sarcoma Family of Tumors



^bSee Principles of Bone Cancer Management (BONE-A).

^fSee Bone Cancer Systemic Therapy Agents (BONE-B).

^gUse the same imaging technique that was performed in the initial workup.

^lRT may be considered for close margins.

^jThere is category 1 evidence for between 28 and 49 weeks of chemotherapy depending on the chemotherapy and dosing schedule used.

^kFor late relapse, consider re-treatment with previously effective regimen.

^lSee Principles of Radiation Therapy (BONE-C).

Note: All recommendations are category 2A unless otherwise indicated.

Clinical Trials: NCCN believes that the best management of any cancer patient is in a clinical trial. Participation in clinical trials is especially encouraged.



NCCN Guidelines Version 2.2016

Giant Cell Tumor of the Bone

WORKUP

- History and physical examination
- Imaging (eg, x-ray, MRI ± CT) of primary site
- Chest imaging
- Bone scan (optional)
- Biopsy to confirm diagnosis^{a,b}
- If there is malignant transformation, treat as described for osteosarcoma. ([See OSTE0-1](#))

PRESENTATION

Localized disease → [See GCTB-2](#)

Metastatic disease at presentation → [See GCTB-2](#)

^aBrown tumor of hyperparathyroidism should be considered as a differential diagnosis.

^b[See Principles of Bone Cancer Management \(BONE-A\)](#).

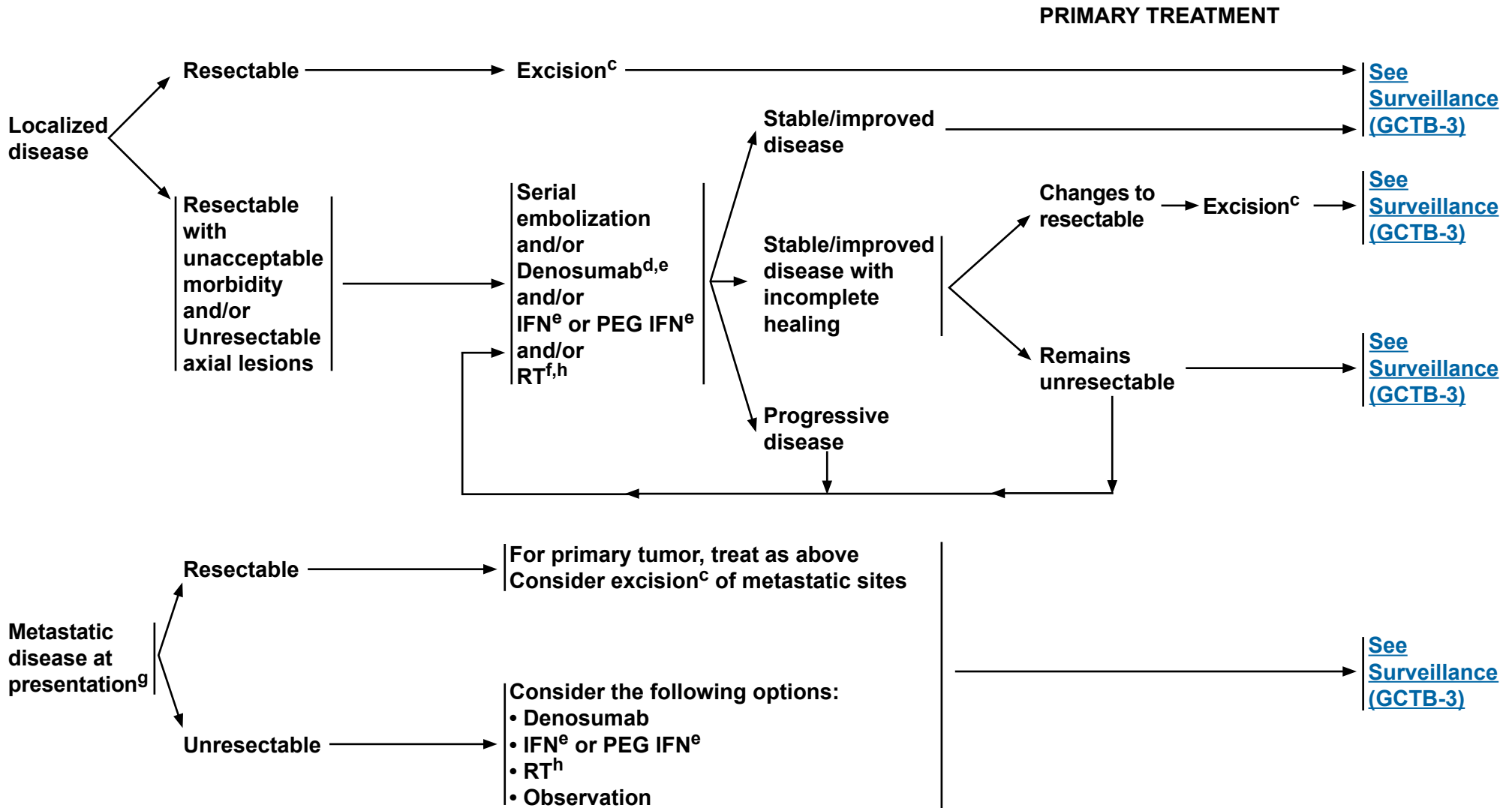
Note: All recommendations are category 2A unless otherwise indicated.

Clinical Trials: NCCN believes that the best management of any cancer patient is in a clinical trial. Participation in clinical trials is especially encouraged.



NCCN Guidelines Version 2.2016

Giant Cell Tumor of the Bone



^cIntralesional excision with an effective adjuvant is adequate.

^dDenosumab should be continued until disease progression in responding disease.

^e[See Bone Cancer Systemic Therapy Agents \(BONE-B\).](#)

^f RT has been associated with increased risk of malignant transformation.

^gTreatment of primary tumor is as described for localized disease.

^h[See Principles of Radiation Therapy \(BONE-C\).](#)

Note: All recommendations are category 2A unless otherwise indicated.

Clinical Trials: NCCN believes that the best management of any cancer patient is in a clinical trial. Participation in clinical trials is especially encouraged.



NCCN Guidelines Version 2.2016

Giant Cell Tumor of the Bone

SURVEILLANCE

- Physical exam
- Imaging (x-ray, MRI ± CT) of surgical site as clinically indicated
- Chest imaging every 6 months for 2 years then annually thereafter

RECURRENCE

Local recurrence

Resectable

Consider chest imaging

Consider denosumab prior to surgery ([See GCTB-2](#))

Resectable with unacceptable morbidity or unresectable axial lesions

[See GCTB-2](#)

Metastatic recurrence

[See GCTB-2](#)

Note: All recommendations are category 2A unless otherwise indicated.

Clinical Trials: NCCN believes that the best management of any cancer patient is in a clinical trial. Participation in clinical trials is especially encouraged.

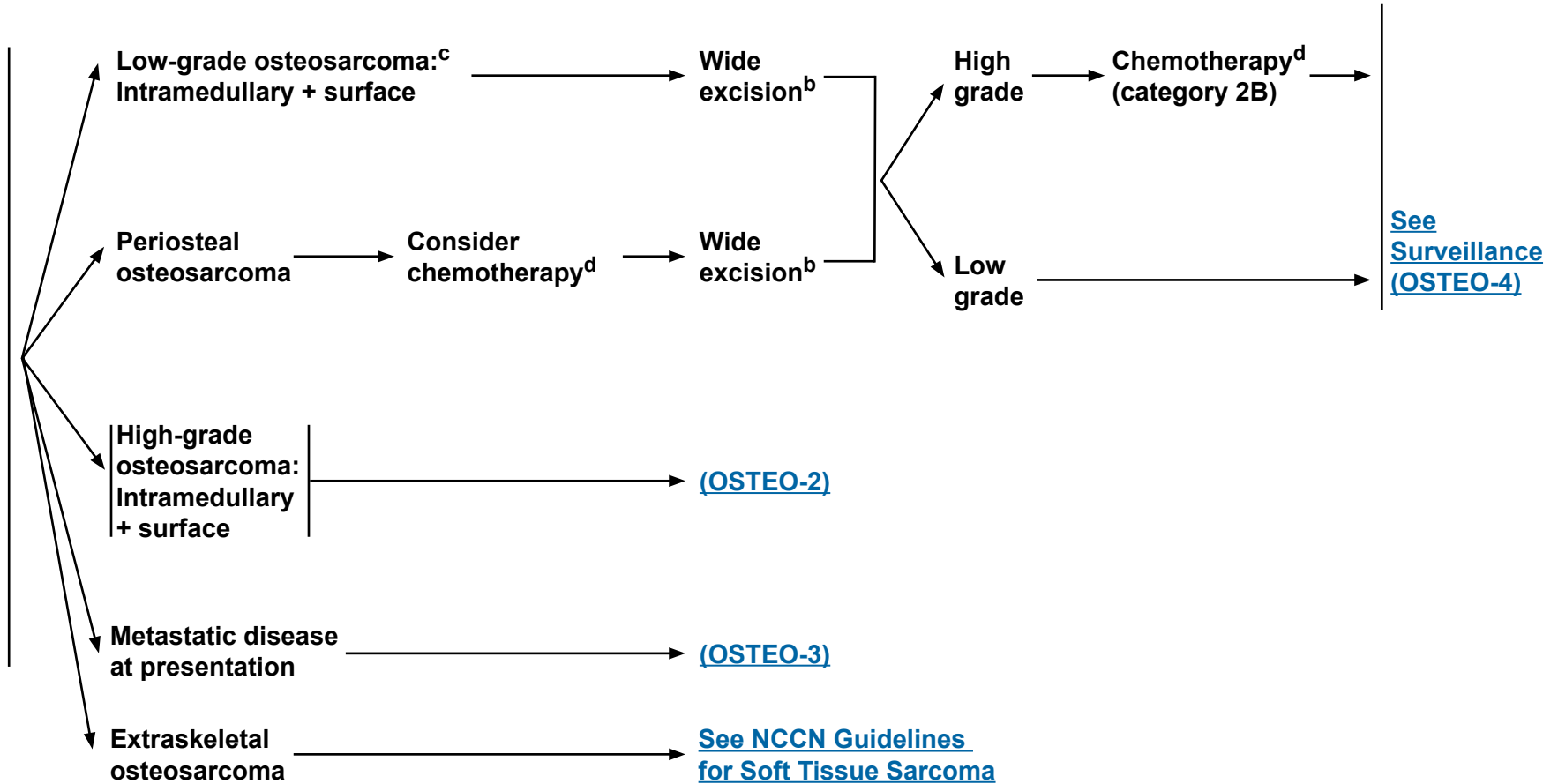


NCCN Guidelines Version 2.2016

Osteosarcoma

WORKUP^{a,b}

- History and physical
- MRI ± CT of primary site
- Chest imaging including chest CT
- PET scan and/or bone scan
- MRI or CT of skeletal metastatic sites^e
- LDH
- ALP
- Fertility consultation should be considered



^aSee [Multidisciplinary Team \(TEAM-1\)](#).

^bSee [Principles of Bone Cancer Management \(BONE-A\)](#).

^cDedifferentiated parosteal osteosarcomas are not considered to be low-grade tumors.

^dSee [Bone Cancer Systemic Therapy Agents \(BONE-B\)](#).

^eMore detailed imaging (CT or MRI) of abnormalities identified on primary imaging is required for suspected metastatic disease.

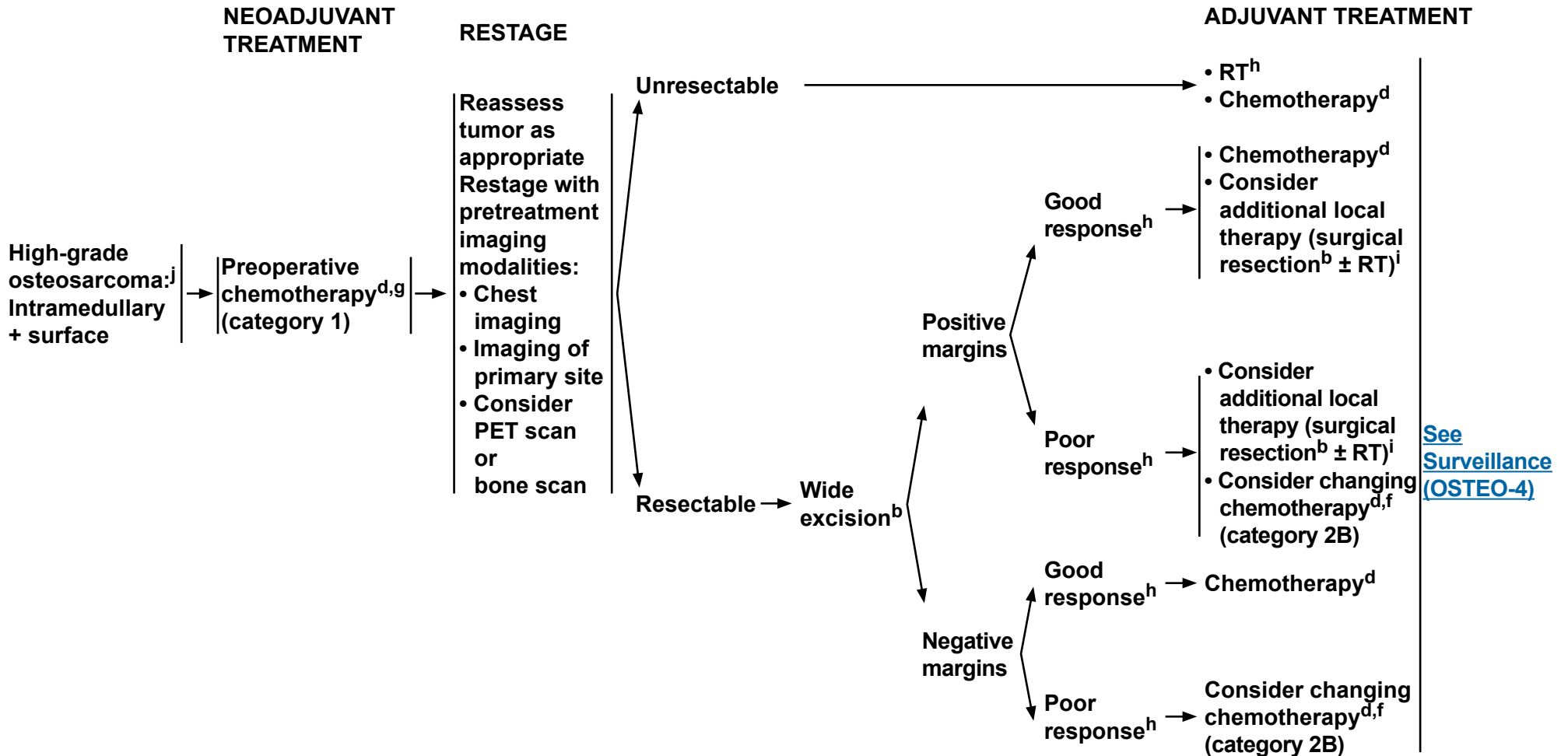
Note: All recommendations are category 2A unless otherwise indicated.

Clinical Trials: NCCN believes that the best management of any cancer patient is in a clinical trial. Participation in clinical trials is especially encouraged.



NCCN Guidelines Version 2.2016

Osteosarcoma



^bSee Principles of Bone Cancer Management (BONE-A).

^dSee Bone Cancer Systemic Therapy Agents (BONE-B).

^fSee discussion for further information (MS-1)

^gSelected elderly patients may benefit from immediate surgery.

^hResponse is defined by pathologic mapping per institutional guidelines; the amount of viable tumor is

reported as less than 10% of the tumor area in cases showing a good response and greater than or equal to 10% in cases showing a poor response.

ⁱSee Principles of Radiation Therapy (BONE-C).

^jOther high-grade non-osteosarcoma variants such as undifferentiated pleomorphic sarcoma (UPS) of bone could also be treated using this algorithm.

Note: All recommendations are category 2A unless otherwise indicated.

Clinical Trials: NCCN believes that the best management of any cancer patient is in a clinical trial. Participation in clinical trials is especially encouraged.

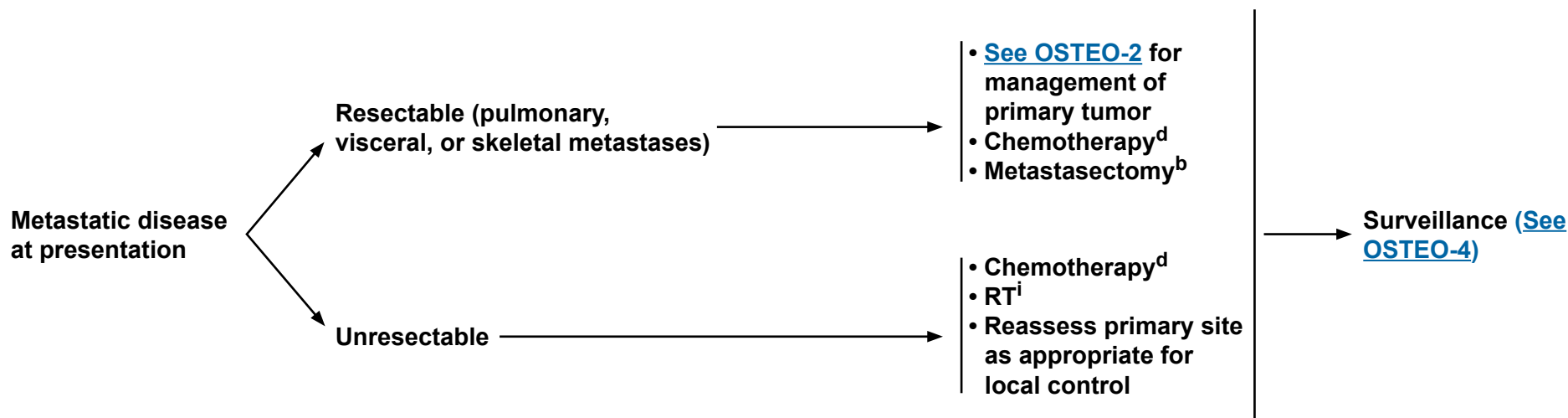


NCCN Guidelines Version 2.2016

Osteosarcoma

PRESENTATION

PRIMARY TREATMENT



^bSee Principles of Bone Cancer Management (BONE-A).

^dSee Bone Cancer Systemic Therapy Agents (BONE-B).

ⁱSee Principles of Radiation Therapy (BONE-C).

Note: All recommendations are category 2A unless otherwise indicated.

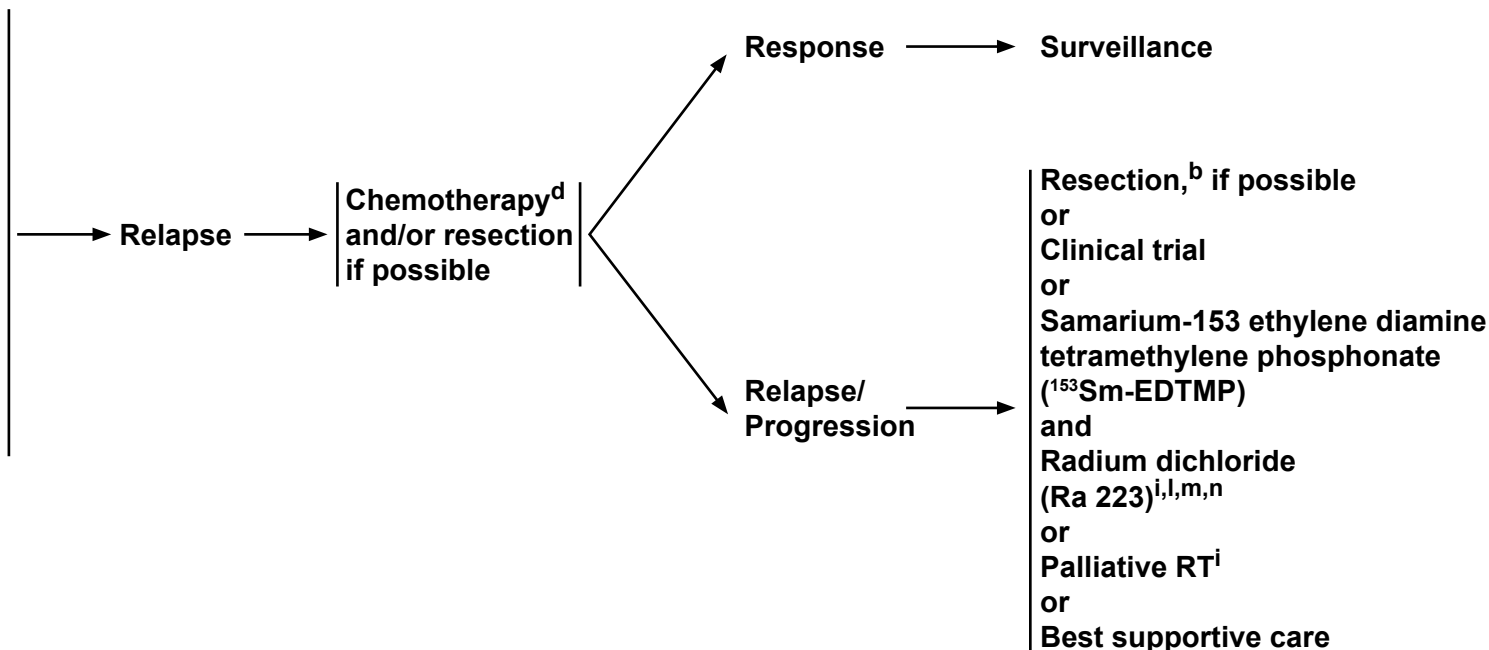
Clinical Trials: NCCN believes that the best management of any cancer patient is in a clinical trial. Participation in clinical trials is especially encouraged.



SURVEILLANCE

- Physical exam, imaging of primary site and chest^k
 - Follow-up schedule: (Orthopedic and Oncologic)
 - Every 3 months for y 1 and 2
 - Every 4 months for y 3
 - Every 6 months for y 4 and 5 and yearly thereafter
- CBC and other laboratory studies as clinically indicated
- Consider PET and/or bone scan (category 2B)
- Reassess function every visit

RELAPSE



^bSee Principles of Bone Cancer Management (BONE-A).

^dSee Bone Cancer Systemic Therapy Agents (BONE-B).

ⁱSee Principles of Radiation Therapy (BONE-C).

^kUse the same imaging technique that was performed in the initial workup.

^lSubbiah V; Anderson PM; Rohren E. Alpha Emitter Radium 223 in High-Risk Osteosarcoma: First Clinical Evidence of Response and Blood-Brain Barrier Penetration. JAMA Oncol-2015;1(2):253-255.

^mAnderson PM; Subbiah V; Rohren E. Bone-seeking radiopharmaceuticals as targeted agents of osteosarcoma: Samarium-153-EDTMP and Radium-223. Adv Exp Med Biol 2014;804:291-304.

ⁿSubbiah V; Rohren E; Huh WW; Kappadath CS; Anderson PM. Phase 1 dose escalation trial of intravenous radium 223 dichloride alpha-particle therapy in osteosarcoma. J Clin Oncol 2014;32(5s): Abstract TPS10600. Presented at the 2014 ASCO Annual Meeting, Chicago, IL, United States.

Note: All recommendations are category 2A unless otherwise indicated.

Clinical Trials: NCCN believes that the best management of any cancer patient is in a clinical trial. Participation in clinical trials is especially encouraged.



PRINCIPLES OF BONE CANCER MANAGEMENT

Biopsy

- Biopsy diagnosis is necessary prior to any surgical procedure or fixation of primary site.
- Biopsy is optimally performed at a center that will do definitive management.
- Placement of biopsy is critical.
- Biopsy should be core needle or surgical biopsy.
- Technique: Apply same principles for core needle or open biopsy. Needle biopsy is not recommended for skull base tumors.
- Appropriate communication between the surgeon, musculoskeletal radiologist, and bone pathologist is critical.
- Fresh tissue may be needed for molecular studies and tissue banking.
- In general, failure to follow appropriate biopsy procedures may lead to adverse patient outcomes.
- Final pathologic evaluation should include assessment of surgical margins and size/dimensions of tumor.

Surgery

- Wide excision should achieve histologically negative surgical margins.
- Negative surgical margins optimize local tumor control.
- Local tumor control may be achieved by either limb-sparing resection or limb amputation (individualized for a given patient).
- Limb-sparing resection is preferred to optimize function if reasonable functional expectations can be achieved.

Lab Studies

- Lab studies such as CBC, LDH, and ALP may have relevance in the diagnosis, prognosis, and management of bone sarcoma patients and should be done prior to definitive treatment and periodically during treatment and surveillance.

Treatment

- Fertility issues should be addressed with patients prior to commencing chemotherapy.
- Care for bone cancer patients should be delivered directly by physicians on the multidisciplinary team (category 1).
[See TEAM-1.](#)

Long-Term Follow-up and Surveillance/Survivorship

- Patients should have a survivorship prescription to schedule follow-up with a multidisciplinary team.
- Life-long follow-up is recommended for surveillance and treatment of late effects of surgery, radiation, and chemotherapy in long-term survivors.
- [See NCCN Guidelines for Adolescent and Young Adult \(AYA\) Oncology](#) (15–39 years old) as clinically appropriate.

Note: All recommendations are category 2A unless otherwise indicated.

Clinical Trials: NCCN believes that the best management of any cancer patient is in a clinical trial. Participation in clinical trials is especially encouraged.

**BONE CANCER SYSTEMIC THERAPY AGENTS****Chondrosarcoma**

- Conventional chondrosarcoma (Grades 1–3) has no known standard chemotherapy options
 - ▶ Cyclophosphamide and sirolimus for high-grade chondrosarcoma for systemic recurrence (category 2B)
- Mesenchymal chondrosarcoma: Follow Ewing's sarcoma regimens (category 2B)
- Dedifferentiated chondrosarcoma: Follow osteosarcoma regimens (category 2B)

Chordoma

- ▶ Imatinib^{1,2,3}
- ▶ Imatinib with cisplatin⁴ or sirolimus⁵
- ▶ Erlotinib⁶
- ▶ Sunitinib⁷
- ▶ Lapatinib for EGFR-positive chordomas⁸ (category 2B)

Ewing's Sarcoma[†]

- First-line therapy (primary/neoadjuvant/adjuvant therapy)^{††}
 - ▶ VAC/IE (vincristine, doxorubicin, and cyclophosphamide alternating with ifosfamide and etoposide)^{9,10,†††}
 - ▶ VAI (vincristine, doxorubicin, and ifosfamide)^{11,12}
 - ▶ VIDE (vincristine, ifosfamide, doxorubicin, and etoposide)¹³
- Primary therapy for metastatic disease at initial presentation^{††}
 - ▶ VAdriaC (vincristine, doxorubicin, and cyclophosphamide)¹⁴
 - ▶ VAC/IE⁹
 - ▶ VAI^{11,12}
 - ▶ VIDE¹³

- Second-line therapy (relapsed/refractory or metastatic disease)^{†††}
 - ▶ Cyclophosphamide and topotecan¹⁵⁻¹⁸
 - ▶ Irinotecan ± temozolomide¹⁹⁻²⁵
 - ▶ Ifosfamide (high dose) ± etoposide^{26, 27}
 - ▶ Ifosfamide, carboplatin, and etoposide²⁹
 - ▶ Docetaxel and gemcitabine³⁰

Giant Cell Tumor of Bone

- ▶ Denosumab³¹⁻³³
- ▶ Interferon alfa³³⁻³⁵
- ▶ Peginterferon³⁵

Osteosarcoma[†]

- First-line therapy (primary/neoadjuvant/adjuvant therapy or metastatic disease)
 - ▶ Cisplatin and doxorubicin³⁶⁻³⁸
 - ▶ MAP (High-dose methotrexate, cisplatin, and doxorubicin)³⁹⁻⁴⁰
 - ▶ Doxorubicin, cisplatin, ifosfamide, and high-dose methotrexate⁴¹
 - ▶ Ifosfamide, cisplatin, and epirubicin⁴²
- Second-line therapy (relapsed/refractory or metastatic disease)
 - ▶ Docetaxel and gemcitabine³⁰
 - ▶ Cyclophosphamide and etoposide⁴³
 - ▶ Cyclophosphamide and topotecan¹⁸
 - ▶ Gemcitabine⁴⁴
 - ▶ Ifosfamide (high dose) ± etoposide^{26, 28}
 - ▶ Ifosfamide, carboplatin, and etoposide²⁹
 - ▶ High-dose methotrexate, etoposide, and ifosfamide⁴⁵
 - ▶ ¹⁵³Sm-EDTMP for relapsed or refractory disease beyond second-line therapy⁴⁶
 - ▶ Ra 223⁴⁷⁻⁴⁹
 - ▶ Sorafenib⁵⁰
 - ▶ Sorafenib + everolimus⁵¹

High-Grade Undifferentiated Pleomorphic Sarcoma (UPS)

- Follow osteosarcoma regimens (category 2B)

[†]Chemotherapy should include growth factor support (See [NCCN Guidelines for Myeloid Growth Factors](#)).

^{††}Dactinomycin can be substituted for doxorubicin for concerns regarding cardiotoxicity.

^{†††}In patients younger than 18 y, evidence supports 2-week compressed treatment.

^{††††}Vincristine could be added to any of the regimens.

Note: All recommendations are category 2A unless otherwise indicated.

Clinical Trials: NCCN believes that the best management of any cancer patient is in a clinical trial. Participation in clinical trials is especially encouraged.

[References on next page](#)

BONE-B
1 OF 4

**BONE CANCER SYSTEMIC THERAPY AGENTS****(References)**

- ¹Georger B, Morland B, Ndiaye A, et al. Target-driven exploratory study of imatinib mesylate in children with solid malignancies by the Innovative Therapies for Children with Cancer (ITCC) European Consortium. *Eur J Cancer* 2009; 45:2342-2351.
- ²Casali PG, Messina A, Stacchiotti S, et al. Imatinib mesylate in chordoma. *Cancer* 2004;101:2086-2097.
- ³Stacchiotti S, Longhi A, Ferraresi V, et al. Phase II study of imatinib in advanced chordoma. *J Clin Oncol* 2012;30(9):914-920.
- ⁴Casali PG, Stacchiotti S, Grosso F, et al. Adding cisplatin (CDDP) to imatinib (IM) re-establishes tumor response following secondary resistance to IM in advanced chordoma. *J Clin Oncol (Meeting Abstracts)* 2007;25(18 suppl):10038.
- ⁵Stacchiotti S, Marrari A, Tamborini E, et al. Response to imatinib plus sirolimus in advanced chordoma. *Ann Oncol* 2009;20:1886-1894.
- ⁶Singhal N, Kotasek D, Parnis FX. Response to erlotinib in a patient with treatment refractory chordoma. *Anticancer Drugs* 2009;20(10):953-955.
- ⁷George S, Merriam P, Maki RG, et al. Multicenter phase II trial of sunitinib in the treatment of nongastrointestinal stromal tumor sarcomas. *J Clin Oncol* 2009;27:3154-3160.
- ⁸Stacchiotti S, Tamborini E, LoVullo S, et al. Phase II study on lapatinib in advanced EGFR-positive chordoma. *Ann Oncol* 2013;24(7):1931-6.
- ⁹Grier HE, Krailo MD, Tarbell NJ, et al. Addition of ifosfamide and etoposide to standard chemotherapy for Ewing's sarcoma and primitive neuroectodermal tumor of bone. *N Engl J Med* 2003;348:694-701.
- ¹⁰Womer RB, West DC, Krailo MD, et al. Randomized controlled trial of interval-compressed chemotherapy for the treatment of localized Ewing sarcoma: A report from the Children's Oncology Group. *J Clin Oncol* 2012 Nov 20;30(33):4148-54.
- ¹¹Paulussen M, Ahrens S, Dunst J, et al. Localized Ewing tumor of bone: final results of the cooperative Ewing's Sarcoma Study CESS 86. *J Clin Oncol* 2001;19:1818-1829.
- ¹²Paulussen M, Craft AW, Lewis I, et al. Results of the EICESS-92 Study: two randomized trials of Ewing's sarcoma treatment--cyclophosphamide compared with ifosfamide in standard-risk patients and assessment of benefit of etoposide added to standard treatment in high-risk patients. *J Clin Oncol* 2008;26:4385-4393.
- ¹³Juergens C, Weston C, Lewis I, et al. Safety assessment of intensive induction with vincristine, ifosfamide, doxorubicin, and etoposide (VIDE) in the treatment of Ewing tumors in the EURO-E.W.I.N.G. 99 clinical trial. *Pediatr Blood Cancer* 2006;47:22-29.
- ¹⁴Miser JS, Krailo MD, Tarbell NJ, et al. Treatment of metastatic Ewing's sarcoma or primitive neuroectodermal tumor of bone: evaluation of combination ifosfamide and etoposide--a Children's Cancer Group and Pediatric Oncology Group study. *J Clin Oncol* 2004;22:2873-2876.
- ¹⁵Bernstein ML, Devidas M, Lafreniere D, et al. Intensive therapy with growth factor support for patients with Ewing tumor metastatic at diagnosis: Pediatric Oncology Group/Children's Cancer Group Phase II Study 9457--a report from the Children's Oncology Group. *J Clin Oncol* 2006;24:152-159.
- ¹⁶Hunold A, Weddeling N, Paulussen M, Ranft A, Liebscher C, Jurgens H. Topotecan and cyclophosphamide in patients with refractory or relapsed Ewing tumors. *Pediatr Blood Cancer* 2006;47:795-800.
- ¹⁷Kushner BH, Kramer K, Meyers PA, Wollner N, Cheung NK. Pilot study of topotecan and high-dose cyclophosphamide for resistant pediatric solid tumors. *Med Pediatr Oncol* 2000;35:468-474.
- ¹⁸Saylor RL, 3rd, Stine KC, Sullivan J, et al. Cyclophosphamide plus topotecan in children with recurrent or refractory solid tumors: a Pediatric Oncology Group phase II study. *J Clin Oncol* 2001;19:3463-3469.
- ¹⁹Casey DA, Wexler LH, Merchant MS, et al. Irinotecan and temozolomide for Ewing sarcoma: the Memorial Sloan-Kettering experience. *Pediatr Blood Cancer* 2009;53:1029-1034.
- ²⁰Wagner LM, Crews KR, Iacono LC, et al. Phase I trial of temozolomide and protracted irinotecan in pediatric patients with refractory solid tumors. *Clin Cancer Res* 2004;10:840-848.
- ²¹Wagner LM, McAllister N, Goldsby RE, et al. Temozolomide and intravenous irinotecan for treatment of advanced Ewing sarcoma. *Pediatr Blood Cancer* 2007;48:132-139.
- ²²McNall-Knapp RY, Williams CN, Reeves EN, Heideman RL, Meyer WH. Extended phase I evaluation of vincristine, irinotecan, temozolomide, and antibiotic in children with refractory solid tumors. *Pediatr Blood Cancer* 2010;54:909-915.
- ²³Blaney S, Berg SL, Pratt C, et al. A phase I study of irinotecan in pediatric patients: a pediatric oncology group study. *Clin Cancer Res* 2001;7:32-37.
- ²⁴Furman WL, Stewart CF, Poquette CA, et al. Direct translation of protracted irinotecan schedule from a xenograft model to a phase I trial in children. *J Clin Oncol* 1999;17:1815-1824.

Note: All recommendations are category 2A unless otherwise indicated.**Clinical Trials: NCCN believes that the best management of any cancer patient is in a clinical trial. Participation in clinical trials is especially encouraged.**[Continue](#)**BONE-B**
2 OF 4

**BONE CANCER SYSTEMIC THERAPY AGENTS****(References)**

- ²⁵McGregor LM, Stewart CF, Crews KR, et al. Dose escalation of intravenous irinotecan using oral cefpodoxime: A phase I study in pediatric patients with refractory solid tumors. *Pediatr Blood Cancer* 2012;58:372-379.
- ²⁶Miser JS, Kinsella TJ, Triche TJ, et al. Ifosfamide with mesna uroprotection and etoposide: an effective regimen in the treatment of recurrent sarcomas and other tumors of children and young adults. *J Clin Oncol* 1987;5:1191-1198.
- ²⁷Magnan H, Goodbody CM, Riedel E, et al. Ifosfamide dose-intensification for patients with metastatic Ewing sarcoma. *Pediatr Blood Cancer* 2015;62(4):594-7.
- ²⁸Goorin AM, Harris MB, Bernstein M, et al. Phase II/III trial of etoposide and high-dose ifosfamide in newly diagnosed metastatic osteosarcoma: a pediatric oncology group trial. *J Clin Oncol* 2002;20(2):426-33. <http://www.ncbi.nlm.nih.gov/pubmed/11786570>.
- ²⁹Van Winkle P, Angiolillo A, Krailo M, et al. Ifosfamide, carboplatin, and etoposide (ICE) reinduction chemotherapy in a large cohort of children and adolescents with recurrent/refractory sarcoma: the Children's Cancer Group (CCG) experience. *Pediatr Blood Cancer* 2005;44:338-347.
- ³⁰Navid F, Willert JR, McCarville MB, et al. Combination of gemcitabine and docetaxel in the treatment of children and young adults with refractory bone sarcoma. *Cancer* 2008;113:419-425.
- ³¹Branstetter DG, Nelson SD, Manivel JC, et al. Denosumab induces tumor reduction and bone formation in patients with giant-cell tumor of bone. *Clin Cancer Res* 2012;18:4415-4424.
- ³²Thomas D, Henshaw R, Skubitz K, et al. Denosumab in patients with giant-cell tumour of bone: an open-label, phase 2 study. *Lancet Oncol* 2010;11:275-280.
- ³³Kaiser U, Neumann K, Havemann K. Generalised giant-cell tumour of bone: successful treatment of pulmonary metastases with interferon alpha, a case report. *J Cancer Res Clin Oncol* 1993;119:301-303.
- ³⁴Kaban LB, Troulis MJ, Ebb D, et al. Antiangiogenic therapy with interferon alpha for giant cell lesions of the jaws. *J Oral Maxillofac Surg* 2002;60:1103-1111.
- ³⁵Yasko AW. Interferon therapy for giant cell tumor of bone. *Curr Opin Orthop* 2006;17:568-572.
- ³⁶Bramwell V, Burgers M, Sneath R, et al. A comparison of two short intensive adjuvant chemotherapy regimens in operable osteosarcoma of limbs in children and young adults: the first study of the European Osteosarcoma Intergroup. *J Clin Oncol* 1992;10:1579-1591.
- ³⁷Lewis IJ, Nooij MA, Whelan J, et al. Improvement in histologic response but not survival in osteosarcoma patients treated with intensified chemotherapy: a randomized phase III trial of the European Osteosarcoma Intergroup. *J Natl Cancer Inst* 2007;99:112-128.
- ³⁸Souhami RL, Craft AW, Van der Eijken JW, et al. Randomised trial of two regimens of chemotherapy in operable osteosarcoma: a study of the European Osteosarcoma Intergroup. *Lancet* 1997;350:911-917.
- ³⁹Bacci G, Ferrari S, Bertoni F, et al. Long-term outcome for patients with nonmetastatic osteosarcoma of the extremity treated at the istituto ortopedico rizzoli according to the istituto ortopedico rizzoli/osteosarcoma-2 protocol: an updated report. *J Clin Oncol* 2000;18:4016-4027.
- ⁴⁰Winkler K, Beron G, Delling G, et al. Neoadjuvant chemotherapy of osteosarcoma: results of a randomized cooperative trial (COSS-82) with salvage chemotherapy based on histological tumor response. *J Clin Oncol* 1988;6:329-337.
- ⁴¹Bacci G, Briccoli A, Rocca M, et al. Neoadjuvant chemotherapy for osteosarcoma of the extremities with metastases at presentation: recent experience at the Rizzoli Institute in 57 patients treated with cisplatin, doxorubicin, and a high dose of methotrexate and ifosfamide. *Ann Oncol* 2003;14:1126-1134.
- ⁴²Basaran M, Bavbek ES, Saglam S, et al. A phase II study of cisplatin, ifosfamide and epirubicin combination chemotherapy in adults with nonmetastatic and extremity osteosarcomas. *Oncology* 2007;72:255-260.
- ⁴³Berger M, Grignani G, Ferrari S, et al. Phase 2 trial of two courses of cyclophosphamide and etoposide for relapsed high-risk osteosarcoma patients. *Cancer* 2009;115:2980-2987.

Note: All recommendations are category 2A unless otherwise indicated.**Clinical Trials: NCCN believes that the best management of any cancer patient is in a clinical trial. Participation in clinical trials is especially encouraged.**



BONE CANCER SYSTEMIC THERAPY AGENTS **(References)**

- ⁴⁴Maki RG, Wathen JK, Patel SR, et al. Randomized phase II study of gemcitabine and docetaxel compared with gemcitabine alone in patients with metastatic soft tissue sarcomas: results of sarcoma alliance for research through collaboration study 002. *J Clin Oncol* 2007;25:2755-2763.
- ⁴⁵Le Deley MC, Guinebretiere JM, Gentet JC, et al. SFOP OS94: a randomised trial comparing preoperative high-dose methotrexate plus doxorubicin to high-dose methotrexate plus etoposide and ifosfamide in osteosarcoma patients. *Eur J Cancer* 2007;43:752-761.
- ⁴⁶Anderson PM, Wiseman GA, Dispenzieri A, et al. High-dose samarium-153 ethylene diamine tetramethylene phosphonate: low toxicity of skeletal irradiation in patients with osteosarcoma and bone metastases. *J Clin Oncol* 2002;20:189-196.
- ⁴⁷Subbiah V; Anderson PM; Rohren E. Alpha Emitter Radium 223 in High-Risk Osteosarcoma: First Clinical Evidence of Response and Blood-Brain Barrier Penetration. *JAMA Oncol*-2015;1(2):253-255.
- ⁴⁸Anderson PM; Subbiah V; Rohren E. Bone-seeking radiopharmaceuticals as targeted agents of osteosarcoma: Samarium-153-EDTMP and Radium-223. *Adv Exp Med Biol* 2014;804:291-304.
- ⁴⁹Subbiah V; Rohren E; Huh WW; Kappadath CS; Anderson PM. Phase 1 dose escalation trial of intravenous radium 223 dichloride alpha-particle therapy in osteosarcoma. *J Clin Oncol* 2014;32(5s): Abstract TPS10600.
- ⁵⁰Grignani G, Palmerini E, Dileo P, et al. A phase II trial of sorafenib in relapsed and unresectable high-grade osteosarcoma after failure of standard multimodal therapy: an Italian Sarcoma Group study. *Ann Oncol* 2012; 23:508-516.
- ⁵¹Grignani G, Palmerini E, Ferraresi V, et al. Sorafenib and everolimus for patients with unresectable high-grade osteosarcoma progressing after standard treatment: a non-randomised phase 2 clinical trial. *Lancet Oncol* 2015;16(1):90-107.

Note: All recommendations are category 2A unless otherwise indicated.

Clinical Trials: NCCN believes that the best management of any cancer patient is in a clinical trial. Participation in clinical trials is especially encouraged.



PRINCIPLES OF RADIATION THERAPY

- Patients should be strongly encouraged to have RT at the same specialized center that is providing surgical and systemic interventions.
- Specialized techniques such as intensity-modulated RT (IMRT); particle beam RT with protons, carbon ions, or other heavy ions; stereotactic radiosurgery; or fractionated stereotactic RT should be considered as indicated in order to allow high-dose therapy while maximizing normal tissue sparing.

CHONDROSARCOMA

- Base of Skull Tumors
 - ▶ Postoperative therapy or RT for unresectable disease: >70 Gy with specialized techniques
- Extracranial Sites
 - ▶ Preoperative RT (19.8–50.4 Gy) may be considered (if positive margins are likely) followed by individualized postoperative RT with final target doses of 70 Gy (R1 resection)¹ and 72 to 78 Gy (R2 resection).¹
 - ▶ Postoperative RT (60–70 Gy) may be considered, especially for high-grade/dedifferentiated/mesenchymal subtypes with close or positive margins.
 - ▶ Consider high-dose therapy with specialized techniques for unresectable disease.

CHORDOMA

- Base of Skull
 - ▶ Postoperative RT (R1 and R2 resection)¹ or RT for unresectable disease 70 Gy or higher (total dose will depend on normal tissue tolerance)
 - ▶ Consider postoperative RT for R0 resections
- Mobile Spine
 - ▶ Consider preoperative RT (19.8–50.4 Gy) and postoperative RT to total dose of 70 Gy (depending on normal tissue tolerances)

¹R0 = No microscopic residual disease, R1 = Microscopic residual disease, R2 = Gross residual disease

Note: All recommendations are category 2A unless otherwise indicated.

Clinical Trials: NCCN believes that the best management of any cancer patient is in a clinical trial. Participation in clinical trials is especially encouraged.

[Continue](#)

BONE-C
1 OF 5

**PRINCIPLES OF RADIATION THERAPY****EWING'S SARCOMA FAMILY OF TUMORS****Treatment of Primary Tumor****• Definitive RT**

- ▶ Should start by week 12 of VAC/IE chemotherapy or week 18 of VIDE chemotherapy
- ▶ Treatment volumes and doses:
 - ◇ 45 Gy to initial gross tumor volume (GTV) + 1–1.5 cm for clinical target volume 1 (CTV1) + 0.5–1 cm for planning target volume 1 (PTV1)
 - ◇ Cone-down (CD) to cover original bony extent + a total of 55.8 Gy to postchemotherapy soft tissue volume (GTV2) + 1–1.5 cm for CTV2 + 0.5–1 cm for PTV2
 - ◇ Consider increasing boost dose to a total of 59.4 Gy for chemotherapy response <50%

• Preoperative RT

- ▶ May be considered for marginally resectable tumors and is given concurrently with consolidation chemotherapy
- ▶ Treatment volumes and doses:
 - ◇ 36–45 Gy for initial GTV + 2 cm

• Postoperative RT

- ▶ Should begin within 60 days of surgery and is given concurrently with consolidation chemotherapy
- ▶ Treatment volumes and doses:
 - ◇ R0 resection:¹ Consider treatment for poor histologic response even if margins are adequate (45 Gy to GTV2 equivalent volume + 1–1.5 cm for CTV1 + 0.5–1 cm for PTV1)
 - ◇ R1 resection:¹ 45 Gy GTV2 equivalent volume + 1–1.5 cm for CTV1 + 0.5–1 cm for PTV1
 - ◇ R2 resection:¹ 45 Gy to GTV2 equivalent volume + 1–1.5 cm for CTV1 + 0.5–1 cm for PTV1 followed by CD to residual disease plus a total of 55.8 Gy to GTV2 + 1–1.5 cm for CTV2 + 0.5–1 cm for PTV2

• Hemithorax Irradiation

- ▶ Should be considered for chest wall primaries with pleural involvement
- ▶ 15–20 Gy (1.5 Gy/fx) followed by CD to primary site (final dose based on resection margins)

Treatment of Metastatic Disease**• Whole-lung irradiation following completion of chemotherapy/metastasectomy**

- ▶ 15 Gy (1.5 Gy/fx) for patients <14 years
- ▶ 18 Gy for patients >14 years

• Current Children's Oncology Group (COG) study stratifies age below or above 6 years (12 vs. 15 Gy)¹R0 = No microscopic residual disease, R1 = Microscopic residual disease, R2 = Gross residual disease**Note:** All recommendations are category 2A unless otherwise indicated.**Clinical Trials:** NCCN believes that the best management of any cancer patient is in a clinical trial. Participation in clinical trials is especially encouraged.[Continue](#)**BONE-C**
2 OF 5



PRINCIPLES OF RADIATION THERAPY

GIANT CELL TUMOR OF BONE

Treatment of Metastatic Disease

- Consider RT (50–60 Gy) for unresectable/progressive/recurrent disease that has not responded to serial embolizations, denosumab, IFN, or PEG IFN.
- An increased risk of malignant transformation following RT has been noted in some studies.

OSTEOSARCOMA

Treatment of Primary Tumor

- RT should be considered for patients with positive margins of resection, subtotal resections, or unresectable disease
 - ▶ Postoperative RT (R1 and R2 resections):¹ 55 Gy with 9–13 Gy boost to microscopic or gross disease (total dose to high-risk sites 64–68 Gy)
 - ▶ Unresectable disease: 60–70 Gy (total dose will depend on normal tissue tolerance)

Treatment of Metastatic Disease

- Consider use of ¹⁵³Sm-EDTMP and Radium 223
- Consider use of stereotactic radiosurgery, especially for oligometastases

¹R0 = No microscopic residual disease, R1 = Microscopic residual disease, R2 = Gross residual disease

Note: All recommendations are category 2A unless otherwise indicated.

Clinical Trials: NCCN believes that the best management of any cancer patient is in a clinical trial. Participation in clinical trials is especially encouraged.

[Continue](#)

BONE-C
3 OF 5



REFERENCES

Chondrosarcoma

- Amichetti M, Amelio D, Cianchetti M, et al. A systematic review of proton therapy in the treatment of chondrosarcoma of the skull base. *Neurosurg Rev* 2010;33(2):155.
- Goda J, Ferguson P, O'Sullivan B, et al. High-risk extracranial chondrosarcoma – Long-term results of surgery and radiation therapy. *Cancer* 2011;117:2513-9.
- Kawaguchi S, Weiss I, Lin PP, Huh WW, Lewis VO. Radiation therapy is associated with fewer recurrences in mesenchymal chondrosarcoma. *Clin Orthop Relat Res* 2014; 472(3): 856-864.
- Rosenberg AE, Nielsen GP, Keel SB, et al. Chondrosarcoma of the base of the skull: a clinicopathologic study of 200 cases with emphasis on its distinction from chordoma. *Am J Surg Pathol* 1999;23(11):1370.
- Uhl M, Mattke M, Welzel T, Oelmann J, Habl G, Jensen AD, Ellerbrock M, Haberer T, Herfarth KK, Debus J. High control rate in patients with chondrosarcoma of the skull base after carbon ion therapy: First report of long-term results. *Cancer* 2014 (on-line only).

Chordoma

- Amichetti M, Cianchetti M, Amelio D, et al. Proton therapy in chordoma of the base of the skull: a systematic review. *Neurosurg Rev* 2009;32(4):403.
- Boriani S, Bandiera S, Biagini R, Bacchini P, Boriani L, Cappuccio M, Chevalley F, Gasbarrini A, Picci P, Weinstein JN. Chordoma of the mobile spine: fifty years of experience. *Spine (Phila Pa 1976)* 2006; 31(4): 493-503.
- Park L, Delaney TF, Liebsch NJ, et al. Sacral chordomas: Impact of high-dose proton/photon-beam radiation therapy combined with or without surgery for primary versus recurrent tumor. *Int J Radiat Oncol Biol Phys* 2006;65(5):1514-21.
- Rutz HP, Weber DC, Sugahara S, Timmermann B, Lomax AJ, Bolsi A, Pedroni E, Coray A, Jermann M, Goitein G. Extracranial chordoma: Outcome in patients treated with function-preserving surgery followed by spot-scanning proton beam irradiation. *Int J Radiat Oncol Biol Phys* 2007; 67(2):512-520.
- Yasuda M, Bresson D, Chibbaro S, Cornelius JF, Polivka M, Feuvret L, Takayasu M, George B. Chordomas of the skull base and cervical spine: clinical outcomes associated with a multimodal surgical resection combined with proton-beam radiation in 40 patients. *Neurosurg Rev* 2012; 35(2):171-182; discussion 182-173.

Ewing's Sarcoma Family of Tumors

- Denbo JW, Shannon Orr W, Wu Y, et al. Timing of surgery and the role of adjuvant radiotherapy in Ewing sarcoma of the chest wall: A single-institution experience. *Ann Surg Oncol* 2012;19(12):3809-15.
- Donaldson SS. Ewing sarcoma: radiation dose and target volume. *Pediatr Blood Cancer* 2004;42(5):471-6.
- Dunst J, Schuck A. Role of radiotherapy in Ewing tumors. *Pediatr Blood Cancer* 2004;42(5):465-70.
- Indelicato DJ, Keole SR, Lagmay JP, et al. Chest wall Ewing sarcoma family of tumors: long-term outcomes. *Int J Radiat Oncol Biol Phys* 2011;81(1):158-66.
- Paulino AC, Mai WY, Teh BS. Radiotherapy in metastatic Ewing sarcoma. *Am J Clin Oncol* 2012 Apr 27. [Epub ahead of print]
- Paulino AC, Nguyen TX, Mai WY, et al. Dose response and local control using radiotherapy in non-metastatic Ewing sarcoma. *Pediatr Blood Cancer* 2007;49(2):145-8.
- Rombi B, DeLaney TF, MacDonald SM, et al. Proton radiotherapy for pediatric Ewing's sarcoma: initial clinical outcomes. *Int J Radiat Oncol Biol Phys* 2012;82(3):1142-8.
- Schuck A, Ahrens S, von Schorlemer I, et al. Radiotherapy in Ewing tumors of the vertebrae: treatment results and local relapse analysis of the CESS 81/86 and EICESS 92 trials. *Int J Radiat Oncol Biol Phys* 2005;63(5):1562-7.
- Yock TI, Krailo M, Fryer CJ, et al. Local control in pelvic Ewing sarcoma: analysis from INT-0091--a report from the Children's Oncology Group. *J Clin Oncol* 2006 Aug 20;24(24):3838-43. Erratum in: *J Clin Oncol* 2006;24(30):4947.

Note: All recommendations are category 2A unless otherwise indicated.

Clinical Trials: NCCN believes that the best management of any cancer patient is in a clinical trial. Participation in clinical trials is especially encouraged.

[Continue](#)

BONE-C
4 OF 5



REFERENCES

Giant Cell Tumor of Bone

Caudell JJ, Ballo MT, Zagars GK, et al. Radiotherapy in the management of giant cell tumor of bone. *Int J Radiat Oncol Biol Phys* 2003;57(1):158.

Hug EB, Muenter MW, Adams JA, et al. 3-D-conformal radiation therapy for pediatric giant cell tumors of the skull base. *Strahlenther Onkol* 2002;178(5):239.

Malone S, O'Sullivan B, Catton C, et al. Long-term follow-up of efficacy and safety of megavoltage radiotherapy in high-risk giant cell tumors of bone. *Int J Radiat Oncol Biol Phys* 1995;33(3):689.

Ruka W, Rutkowski P, Morysinski T, et al. The megavoltage radiation therapy in treatment of patients with advanced or difficult giant cell tumors of bone. *Int J Radiat Oncol Biol Phys* 2010;78(2):494.

Mixed Histology Reports

DeLaney TF, Liebsch NJ, Pedlow FX, et al. Phase II study of high-dose photon/proton radiotherapy in the management of spine sarcomas. *Int J Radiat Oncol Biol Phys* 2009;74(3):732-9.

Jingu K, Tsujii H, Mizoe JE, Hasegawa A, Bessho H, Takagi R, Morikawa T, Tonogi M, Tsuji H, Kamada T, Yamada S. Organizing Committee for the Working Group for Head-and-Neck Cancer. Carbon ion radiation therapy improves the prognosis of unresectable adult bone and soft-tissue sarcoma of the head and neck. *Int J Radiat Oncol Biol Phys* 2012; 82(5): 2125-2131.

Kamada T, Tsujii H, Yanagi T, et al. Efficacy and safety of carbon ion radiotherapy in bone and soft tissue sarcomas. Working Group for the Bone and Soft Tissue Sarcomas. *J Clin Oncol* 2002;20(22):4466.

Wagner TD, Kobayashi W, Dean S, et al. Combination short-course preoperative irradiation, surgical resection, and reduced-field high-dose postoperative irradiation in the treatment of tumors involving the bone. *Int J Radiat Oncol Biol Phys* 2009;73(1):259-66.

Osteosarcoma

Anderson PM; Subbiah V; Rohren E. Bone-seeking radiopharmaceuticals as targeted agents of osteosarcoma: Samarium-153-EDTMP and Radium-223. *Adv Exp Med Biol* 2014;804:291-304.

Ciernik IF, Niemierko A, Harmon DC, Kobayashi W, Chen YL, Yock TI, Ebb DH, Choy E, Raskin KA, Liebsch N, Hornicek FJ, Delaney TF. Proton-based radiotherapy for unresectable or incompletely resected osteosarcoma. *Cancer* 2011;117(19): 4522-4530.

DeLaney, TF, Park L, Goldberg SI, Hug EB, Liebsch NJ, Munzenrider JE, Suit HD. Radiotherapy for local control of osteosarcoma. *Int J Radiat Oncol Biol Phys* 2005;61(2): 492-498.

Guadagnolo BA, Zagars GK, Raymond AK, Benjamin RS, Sturgis EM. Osteosarcoma of the jaw/craniofacial region: outcomes after multimodality treatment. *Cancer* 2009;115(14): 3262-3270.

Mahajan A, Woo SY, Kornguth DG, Hughes D, Huh E, Chang EL, Herzog CE, Pelloski CE, Anderson P. Multimodality treatment of osteosarcoma: radiation in a high-risk cohort. *Pediatr Blood Cancer* 2008;50(5): 976-982.

Subbiah V; Anderson PM; Rohren E. Alpha Emitter Radium 223 in High-Risk Osteosarcoma: First Clinical Evidence of Response and Blood-Brain Barrier Penetration. *JAMA Oncol* 2015;1(2):253-255.

Subbiah V; Rohren E; Huh WW; Kappadath CS; Anderson PM. Phase 1 dose escalation trial of intravenous radium 223 dichloride alpha-particle therapy in osteosarcoma. *J Clin Oncol* 2014;32(5s): Abstract TPS10600. Presented at the 2014 ASCO Annual Meeting, Chicago, IL, United States.

Note: All recommendations are category 2A unless otherwise indicated.

Clinical Trials: NCCN believes that the best management of any cancer patient is in a clinical trial. Participation in clinical trials is especially encouraged.



NCCN Guidelines Version 2.2016

Bone Cancer

Table 1

**American Joint Committee on Cancer (AJCC)
TNM Staging System for Bone** (Primary malignant lymphoma and multiple myeloma are not included)

(7th ed., 2010)

Primary Tumor (T)

- TX** Primary tumor cannot be assessed
- T0** No evidence of primary tumor
- T1** Tumor 8 cm or less in greatest dimension
- T2** Tumor more than 8 cm in greatest dimension
- T3** Discontinuous tumors in the primary bone site

Regional Lymph Nodes (N)

- NX** Regional lymph nodes cannot be assessed
- N0** No regional lymph node metastasis
- N1** Regional lymph node metastasis

Note: Because of the rarity of lymph node involvement in bone sarcomas, the designation **NX** may not be appropriate and cases should be considered **N0** unless clinical node involvement is clearly evident.

Distant Metastasis (M)

- M0** No distant metastasis
- M1** Distant metastasis
- M1a** Lung
- M1b** Other distant sites

Histologic Grade (G)

- GX** Grade cannot be assessed
- G1** Well differentiated — Low Grade
- G2** Moderately differentiated — Low Grade
- G3** Poorly differentiated
- G4** Undifferentiated

Note: Ewing's sarcoma is classified as G4.

Stage Grouping

Stage IA	T1	N0	M0	G1, 2 Low grade, GX
Stage IB	T2	N0	M0	G1, 2 Low grade, GX
	T3	N0	M0	G1, 2 Low grade, GX
Stage IIA	T1	N0	M0	G3, 4 High grade
Stage IIB	T2	N0	M0	G3, 4 High grade
Stage III	T3	N0	M0	G3,
Stage IVA	Any T	N0	M1a	Any G
Stage IVB	Any T	N1	Any M	Any G
	Any T	Any N	M1b	Any G

Used with the permission of the American Joint Committee on Cancer (AJCC), Chicago, Illinois. The original and primary source for this information is the AJCC Cancer Staging Manual, Seventh Edition (2010) published by Springer Science+Business Media, LLC (SBM). (For complete information and data supporting the staging tables, visit www.springer.com.) Any citation or quotation of this material must be credited to the AJCC as its primary source. The inclusion of this information herein does not authorize any reuse or further distribution without the expressed, written permission of Springer SBM, on behalf of the AJCC.

Table 2

Surgical Staging System (SSS)

Stage	Grade	Site
IA	Low (G1)	Intracompartmental (T1)
IB	Low (G1)	Extracompartmental (T2)
IIA	High (G2)	Intracompartmental (T1)
IIB	High (G2)	Extracompartmental (T2)
III	Any (G) + Regional or distant metastasis	Any (T)

From Enneking WF, Spanier SS, Goodman MA: A system for the surgical staging of musculoskeletal sarcoma. Clin Orthop 1980;153:106-120.

Note: All recommendations are category 2A unless otherwise indicated.

Clinical Trials: NCCN believes that the best management of any cancer patient is in a clinical trial. Participation in clinical trials is especially encouraged.

Discussion

NCCN Categories of Evidence and Consensus

Category 1: Based upon high-level evidence, there is uniform NCCN consensus that the intervention is appropriate.

Category 2A: Based upon lower-level evidence, there is uniform NCCN consensus that the intervention is appropriate.

Category 2B: Based upon lower-level evidence, there is NCCN consensus that the intervention is appropriate.

Category 3: Based upon any level of evidence, there is major NCCN disagreement that the intervention is appropriate.

All recommendations are category 2A unless otherwise noted.

Table of Contents

Overview	MS-2
Literature Search Criteria and Guidelines Update Methodology	MS-2
Staging	MS-3
Principles of Bone Cancer Management	MS-3
Multidisciplinary Team Involvement	MS-3
Diagnostic Workup	MS-3
Biopsy	MS-4
Surgery	MS-5
Radiation Therapy	MS-5
Chondrosarcoma	MS-5
Prognostic Factors	MS-6
Treatment	MS-6

Surveillance	MS-8
Relapsed Disease	MS-8
Chordoma	MS-8
Workup	MS-9
Treatment	MS-9
Surveillance	MS-11
Relapsed Disease	MS-11
Ewing's Sarcoma Family of Tumors	MS-11
Prognostic Factors	MS-12
Workup	MS-12
Treatment	MS-13
Surveillance	MS-16
Relapsed or Refractory Disease	MS-16
Giant Cell Tumor of Bone	MS-18
Workup	MS-18
Treatment	MS-18
Surveillance	MS-20
Osteosarcoma	MS-20
Prognostic Factors	MS-21
Workup	MS-21
Treatment	MS-22
Localized Disease	MS-23
Metastatic Disease at Presentation	MS-24
Surveillance	MS-25
Relapsed or Refractory Disease	MS-25
High-grade Undifferentiated Pleomorphic Sarcoma of Bone	MS-26
Summary	MS-26
References	MS-28



Overview

Primary bone cancers are extremely rare neoplasms accounting for less than 0.2% of all cancers, although the true incidence is difficult to determine secondary to the rarity of these tumors.¹ In 2015, an estimated 2970 people will be diagnosed in the United States and 1490 people will die from the disease.² Primary bone cancers demonstrate wide clinical heterogeneity and are often curable with proper treatment. Osteosarcoma (35%), chondrosarcoma (30%), and Ewing's sarcoma (16%) are the three most common forms of bone cancer. High-grade undifferentiated pleomorphic sarcoma (UPS) of bone, fibrosarcoma, chordoma, and giant cell tumor of bone (GCTB) are relatively rare tumors constituting up to 1% to 5% of all primary malignant bone tumors.³ GCTB has both benign and malignant forms, with the benign form being the most common subtype.

Various types of bone cancers are named based on their histologic origin: chondrosarcomas arise from cartilage, osteosarcomas arise from bone, and fibrogenic tissue is the origin of fibrosarcoma of bone, whereas vascular tissue gives rise to hemangioendothelioma and hemangiopericytoma. Notochordal tissue gives rise to chordoma. Several primary bone cancers, including Ewing's sarcoma family of tumors (ESFT), are of unknown histologic origin. Chondrosarcoma is usually found in middle-aged and older adults. Osteosarcoma and Ewing's sarcoma develop mainly in children and young adults. Chordoma is more common in males, with the peak incidence in the fifth to sixth decades of life.^{4,5}

The pathogenesis and etiology of most bone cancers remains unclear. Gene rearrangements between the *EWS* and *ETS* family of genes have been implicated in the pathogenesis of ESFT.⁶⁻⁹ Specific germline mutations have also been implicated in the pathogenesis of

osteosarcoma.^{10,11} The Li-Fraumeni syndrome characterized by a germline mutation in the *TP53* gene is associated with a high risk of developing osteosarcoma.¹²⁻¹⁴ Osteosarcoma is the most common second primary malignancy in patients with a history of retinoblastoma, characterized by a mutation in the retinoblastoma gene *RB1*.^{10,15,16} Increased incidences of osteosarcoma have also been associated with other inherited genetic predisposition syndromes characterized by mutations in the DNA helicase genes.¹⁰ Osteosarcoma is also the most common radiation-induced bone sarcoma.^{17,18}

The development of multiagent chemotherapy regimens for neoadjuvant and adjuvant treatment has considerably improved the prognosis for patients with osteosarcoma and ESFT.^{19,20} With current multimodality treatment, approximately three quarters of all patients diagnosed with osteosarcoma are cured and 90% to 95% of patients diagnosed with osteosarcoma can be successfully treated with limb-sparing approaches rather than amputation.²¹ Survival rates have improved to almost 70% in patients with localized ESFT.²⁰ In patients with ESFT and osteosarcoma, a cure is still achievable in selected patients diagnosed with metastatic disease at presentation.^{22,23} The 5-year survival across all types of primary bone cancers is 66.6%.¹

The NCCN Guidelines for Bone Cancer focus on chordoma, chondrosarcoma, ESFT, and osteosarcoma. The Guidelines also provide recommendations for treating GCTB. Although typically benign, GCTB is locally aggressive and can lead to significant bone destruction.

Literature Search Criteria and Guidelines Update Methodology

Prior to the update of this version of the NCCN Guidelines for Bone Cancer, an electronic search of the PubMed database was performed to obtain key literature in bone cancer published between 05/01/2014



and 04/29/2015, using the following search terms: bone sarcoma OR chondrosarcoma OR chordoma OR Ewing's Sarcoma OR giant cell tumor of the bone OR osteosarcoma OR primary bone cancer. The PubMed database was chosen as it remains the most widely used resource for medical literature and indexes only peer-reviewed biomedical literature.

The search results were narrowed by selecting studies in humans published in English. Results were confined to the following article types: Clinical Trial, Phase II; Clinical Trial, Phase III; Clinical Trial, Phase IV; Guideline; Randomized Controlled Trial; Meta-Analysis; Systematic Reviews; and Validation Studies.

The PubMed search resulted in 168 citations and their potential relevance was examined. The data from key PubMed articles as well as articles from additional sources deemed as relevant to these guidelines and discussed by the panel have been included in this version of the Discussion section (eg, e-publications ahead of print, meeting abstracts). Recommendations for which high-level evidence is lacking are based on the panel's review of lower-level evidence and expert opinion.

The complete details of the Development and Update of the NCCN Guidelines are available at www.NCCN.org.

Staging

The 2010 AJCC staging classification is based on the assessment of histologic grade (G), tumor size (T), and presence of regional (N) and/or distant metastases (M).²⁴ The Surgical Staging System is another staging system for bone and soft tissue sarcomas developed by the Musculoskeletal Tumor Society (Table 2).²⁵ This system stratifies both bone and soft tissue sarcomas by the assessment of the surgical

grade (G), local extent (T), and presence or absence of regional or distant metastases. It may be used in addition to the AJCC staging system.

Principles of Bone Cancer Management

Multidisciplinary Team Involvement

Primary bone tumors and selected metastatic tumors should be evaluated and treated by a multidisciplinary team of physicians with demonstrated expertise in the management of these tumors. Long-term surveillance and follow-up are necessary when considering the risk of recurrence and comorbidities associated with chemotherapy and radiation therapy (RT). Life-long follow-up is recommended for surveillance and treatment of late effects of surgery, RT, and chemotherapy in long-term survivors. Patients should be given a survivorship prescription to schedule follow-up with a multidisciplinary team. Fertility issues should be discussed with appropriate patients.²⁶ For information on disease- and survivorship-related issues for adolescent and young adult patients, please refer to the NCCN Guidelines for Adolescent and Young Adult (AYA) Oncology as clinically appropriate.

Diagnostic Workup

Suspicion of a malignant bone tumor in a patient with a symptomatic lesion often begins when a poorly marginated lesion is seen on a plain radiograph. In patients younger than 40 years, an aggressive, symptomatic bone lesion has a significant risk of being a malignant primary bone tumor, and referral to an orthopedic oncologist should be considered prior to further workup. In patients 40 years of age and older, CT scan of the chest, abdomen, and pelvis; bone scan; mammogram; and other imaging studies as clinically indicated should be performed if plain radiographs do not suggest a specific diagnosis.²⁷



All patients with suspected bone sarcoma should undergo complete staging prior to biopsy. The standard staging workup for a suspected primary bone cancer should include chest imaging (chest radiograph or chest CT to detect pulmonary metastases), appropriate imaging of the primary site (plain radiographs, MRI for local staging, and/or CT scan), and bone scan.²⁸ Whole-body MRI is a sensitive imaging technique for the detection of skeletal metastases in patients with small cell neoplasms, ESFT, and osteosarcoma.^{29,30} Imaging of painless bone lesions should be evaluated by a musculoskeletal radiologist followed by appropriate referral to a multidisciplinary treatment team if necessary. Laboratory studies, such as complete blood count (CBC), lactate dehydrogenase (LDH), and alkaline phosphatase (ALP) should be done prior to initiation of treatment.

PET or PET/CT is an alternative imaging technique that has been utilized in the pretreatment staging of soft tissue and bone sarcomas.^{31,32} Recent reports in literature have demonstrated the utility of PET scans in the evaluation of response to chemotherapy in patients with osteosarcoma, ESFT, and advanced chordoma.³³⁻³⁶ PET or PET/CT with the investigational radioactive substance ¹⁸F-fluoromisonidazole (FMISO) has been shown to identify the hypoxic component in residual chordomas prior to RT.³⁷ This approach is being evaluated in clinical trials and would be helpful in identifying tumors with low oxygen levels that are more resistant to RT.

Biopsy

Incisional (open) biopsy and percutaneous biopsy (core needle or fine-needle aspiration [FNA]) are the two techniques used historically in the diagnosis of musculoskeletal lesions.^{38,39} Open biopsy is the most accurate method because of larger sample size, which is useful for performing additional studies such as immunohistochemistry or

cytogenetics.⁴⁰ However, open biopsy requires general or regional anesthesia and an operating room, whereas core biopsy can be performed under local anesthesia, with or without sedation. Core needle biopsy has also been used as an alternative to open biopsy for the diagnosis of musculoskeletal lesions with accuracy rates ranging from 88% to 96% when adequate samples are obtained.⁴¹⁻⁴⁴ Cost savings may be realized when needle biopsy is employed in selected patients.⁴¹ Recent advances in imaging techniques have contributed to the increasing use of image-guided percutaneous biopsy for the diagnosis of primary and secondary bone tumors.⁴⁵ The method of choice for biopsy remains controversial since no randomized controlled trials have compared core needle biopsy with open biopsy.

The guidelines recommend core needle or open biopsy to confirm the diagnosis of primary bone tumor prior to any surgical procedure or fixation of primary site. Biopsy should be performed at the center that will provide definitive treatment for patients with a suspected primary malignant bone tumor. At the time of biopsy, careful consideration should be given to appropriate stabilization of the bone and/or measures to protect against impending pathologic fracture. The placement of biopsy is critical to the planning of limb-sparing surgery, and failure to follow appropriate biopsy procedures may lead to adverse patient outcomes.^{38,39} In a multicenter review of 597 patients with musculoskeletal tumors, alteration of the treatment plan (complex resection or the use of adjunctive treatment) was encountered in 19% of patients and unnecessary amputation was performed in 18 patients.⁴⁶

Both open and core needle biopsy techniques are associated with risk of local tumor recurrence either by tumor spillage or tumor seeding along the biopsy tract, if the scar is not removed en bloc during the tumor resection. The risk of tumor seeding is less with core needle



biopsy.^{47,48} Nevertheless, the same principles should be applied for core needle and open biopsy. Appropriate communication between the surgeon, musculoskeletal oncologist, and bone pathologist is critical in planning the biopsy route. It is essential to select the biopsy route in collaboration with the surgeon to ensure that the biopsy tract lies within the planned resection bed so that it can be resected with the same wide margins as the primary tumor during surgery. Although the risk of tumor seeding is not significant with FNA biopsy, it is not suitable for the diagnosis of primary lesions since the diagnostic accuracy of FNA is less than that of core needle biopsy.⁴⁹

Surgery

Surgical margins should be negative, wide enough to minimize potential local recurrence, and narrow enough to maximize function. Wide excision implies histologically negative surgical margins and it is necessary to optimize local control. Local control may be achieved either by limb-sparing surgery or amputation. In selected cases, amputation may be the most appropriate option to achieve this goal. However, limb-sparing surgery is preferred if reasonable functional outcomes can be achieved. Final pathologic evaluation should include assessment of surgical margins and size/dimensions of tumor. The response to the preoperative therapy should be evaluated utilizing pathologic mapping. Consultation with a physiatrist is recommended to evaluate for mobility training and to prescribe an appropriate rehabilitation program.

Radiation Therapy

RT is used either as an adjuvant to surgery for patients with resectable tumors or as definitive therapy in patients with tumors not amenable to surgery. Specialized techniques such as intensity-modulated RT (IMRT); particle beam RT with protons, carbon ions, or other heavy

ions; stereotactic radiosurgery (SRS); or fractionated stereotactic radiotherapy (FSRT) should be considered as clinically indicated in order to deliver high radiation doses while maximizing normal tissue sparing.^{50,51} RT should be administered at the same specialized center that is providing surgical and systemic interventions. See *Principles of Radiation Therapy* in the guidelines algorithm for treatment volumes and radiation doses specific to each subtype.

Chondrosarcoma

Chondrosarcomas characteristically produce cartilage matrices from neoplastic tissue devoid of osteoid and may occur at any age, but they are more common in older adults.^{52,53} The pelvis and the proximal femur are the most common primary sites. Conventional chondrosarcoma of the bone constitutes approximately 85% of all chondrosarcomas and is divided as follows: 1) primary or central lesions arising from previously normal-appearing bone preformed from cartilage; or 2) secondary or peripheral tumors that arise or develop from preexisting benign cartilage lesions, such as enchondromas, or from the cartilaginous portion of an osteochondroma.^{52,54} Malignant transformation has been reported in patients with Ollier's disease (enchondromatosis) and Maffucci syndrome (enchondromatosis associated with soft tissue hemangioma).⁵⁵ The peripheral or secondary tumors are usually low grade with infrequent metastasis.⁵⁶ About half of chondrosarcoma cases and nearly all cases of Ollier's Disease and Maffucci Syndrome are related to isocitrate dehydrogenase (*IDH1* or *IDH2*) mutations.⁵⁷⁻⁵⁹

In addition to conventional chondrosarcoma, there are several other rare subtypes constituting about 10% to 15% of all chondrosarcomas.⁵² These include clear cell, dedifferentiated, myxoid, and mesenchymal forms of chondrosarcoma.^{52,60} Primary skeletal myxoid chondrosarcoma (myxoid chondrosarcoma of bone) is an extremely rare neoplasm that



has not been fully characterized as a distinct clinicopathologic entity.^{61,62} It is considered to be a myxoid variant of intermediate- or high-grade chondrosarcoma and is commonly located in the bones around the hip joint.^{52,62} Research suggests that alterations in the retinoblastoma pathway are present in a significant majority of clear cell, dedifferentiated, and mesenchymal chondrosarcomas.⁶⁰

Extraskeletal myxoid chondrosarcoma, on the other hand, is a rare soft tissue sarcoma that is characterized by chromosomal translocations t(9;22)(q22;q11-12) or t(9;17)(q22;q11), generating the fusion genes, *EWS-CHN* (*EWSR1-NR4A3*) or *RBP56-CHN* (*TAF2N-NR4A3*), respectively.^{63,64} In addition, two other variant chromosomal translocations, t(9;15)(q22;q21) and t(3;9)(q12;q22), resulting in fusions genes, *TCF12-NR4A3* and *TFG-NR4A3*, respectively, have also been identified in case reports.⁶⁵ A recent retrospective study demonstrated prolonged overall survival in patients with extraskeletal myxoid chondrosarcoma despite high rates of local and distant recurrence.⁶⁶ The data also revealed a significant pattern of decreased event-free survival (EFS) with increasing tumor size. Extraskeletal myxoid chondrosarcoma is not included in the NCCN Guidelines for Bone Cancers.

Symptoms of chondrosarcoma are usually mild and depend upon tumor size and location. Patients with pelvic or axial lesions typically present later in the disease course, as the associated pain has a more insidious onset and often occurs when the tumor has reached a significant size.⁶⁷⁻⁶⁹ Central chondrosarcomas demonstrate cortical destruction and loss of medullary bone trabeculations on radiographs, as well as calcification and destruction.⁶⁸ MRI will show the intramedullary involvement as well as extraosseous extension of the tumor. Secondary lesions arise from preexisting lesions. Serial radiographs will demonstrate a slow increase in size of the osteochondroma or

enchondroma. A cartilage “cap” measuring greater than two centimeters on a pre-existing lesion or documented growth after skeletal maturity should raise the suspicion of sarcomatous transformation.⁷⁰

Prognostic Factors

Whether the lesion is primary or secondary, central or peripheral, the anatomic location, histologic grade, and size of the lesion are essential prognostic features.^{67,71-73} In an analysis of 2890 patients with chondrosarcoma from the SEER database, female sex, a low histologic grade, and local surgical stage were associated with a significant disease-specific survival benefit in the univariate analysis, whereas only grade and stage had significant association with disease-specific survival on multivariate analysis.⁷⁴

Treatment

Surgery

Wide excision with negative margins is the preferred primary treatment for patients with large tumors and pelvic localization, irrespective of the grade.^{73,75-77} Wide resection with adequate surgical margins is associated with higher EFS and overall survival (OS) rates in patients with chondrosarcoma of axial skeleton and pelvic girdle. The 10-year OS and EFS rates were 61% and 44%, respectively, for patients who underwent resection with adequate surgical margins compared to the corresponding survival rates of 17% and 0% for those who underwent resection with inadequate surgical margins.⁷⁸ Intralesional curettage with adjuvant cryosurgery has been shown to be associated with low rates of recurrence in patients with grade I intracompartmental chondrosarcomas.⁷⁹⁻⁸¹ In selected patients with low-grade and less radiographically aggressive, non-pelvic chondrosarcomas, intralesional excision can be used as an alternative to wide excision without



compromising outcomes.⁸²⁻⁸⁴ This approach should be restricted to extremity tumors.

Radiation Therapy

RT can be considered after incomplete resection or for palliation of symptoms in patients with advanced or unresectable tumors.^{52,53} In a retrospective analysis of 60 patients who underwent surgery for extracranial high-risk chondrosarcoma, the use of RT as an adjunct to surgery (preoperative or postoperative) was associated with excellent and durable local control for tumors not amenable to wide surgical resection.⁸⁵ A recent retrospective study of patients with mesenchymal chondrosarcoma suggested that adjuvant RT for local tumor control was associated with fewer recurrences.⁸⁶

Proton beam RT alone or in combination with photon beam RT has been associated with an excellent local tumor control and long-term survival in the treatment of patients with low-grade skull base and cervical spine chondrosarcomas.⁸⁷⁻⁹³ In two separate studies, proton beam RT resulted in local control rates of 92% and 94% in patients with chondrosarcoma of the skull base.^{87,91} Noel et al reported a 3-year local control rate of 92% in 26 patients with chondrosarcoma of the skull base and upper cervical spine treated with surgical resection followed by a combination of proton and photon beam RT.⁹⁰ In a larger series involving 229 patients with chondrosarcomas of the skull base, the combination of proton and photon beam RT resulted in 10-year local control rates of 94%.⁸⁸ Carbon ion RT has also been reported to result in high local control rates in patients with skull base chondrosarcomas.⁹⁴⁻⁹⁶

Chemotherapy

Chemotherapy is generally not effective in chondrosarcoma, particularly the conventional and dedifferentiated subtypes. Mitchell and colleagues

reported that adjuvant chemotherapy with cisplatin and doxorubicin was associated with improved survival in patients with dedifferentiated chondrosarcoma.⁹⁷ However, this finding could not be confirmed in other studies.⁹⁸⁻¹⁰⁰ A recent review of outcomes for 113 patients with mesenchymal chondrosarcoma reported that the addition of chemotherapy was associated with reduced risk of recurrence and death.¹⁰¹ Another report from the German study group also confirmed that the outcome was better in younger patients with mesenchymal chondrosarcoma who received chemotherapy.¹⁰² In the absence of data from prospective randomized trials, the role of chemotherapy in the treatment of chondrosarcomas remains undefined.

NCCN Recommendations

The histologic grade and tumor locations are the most important variables that determine the choice of the primary treatment.

Wide excision or intralesional excision with or without an adjuvant are the primary treatment options for patients with resectable low-grade and intracompartmental lesions.^{83,84} Wide excision is the preferred treatment option for patients with pelvic low-grade chondrosarcomas.⁷⁵ High-grade (grade II, III), clear cell, or extracompartmental lesions, if resectable, should be treated with wide excision obtaining negative surgical margins.⁷⁸ Wide excision should provide negative surgical margins and may be achieved by either limb-sparing surgery or amputation.

Postoperative treatment with proton and/or photon beam RT may be useful for patients with tumors in an unfavorable location not amenable to resection, especially in chondrosarcomas of the skull base and axial skeleton.^{52,53} RT can be considered for patients with unresectable high- and low-grade lesions. However, since there are not enough data



to support the use of RT in patients with chondrosarcoma, the panel has included this option with a category 2B recommendation.

There are no established chemotherapy regimens for conventional chondrosarcoma (grades 1–3). The guidelines suggest that patients with dedifferentiated chondrosarcomas could be treated as per osteosarcoma and those with mesenchymal chondrosarcomas could be treated as per Ewing's sarcoma. Both of these options are included with a category 2B recommendation.

Surveillance

Surveillance for low-grade lesions consists of a physical exam: imaging of the chest and primary site every 6 to 12 months for 2 years and then yearly as appropriate.

Surveillance for high-grade lesions consists of a physical exam, radiographs of the primary site, and/or cross-sectional imaging as indicated as well as chest imaging every 3 to 6 months for the first 5 years and yearly thereafter for a minimum of 10 years, as late metastases and recurrences after 5 years are more common with chondrosarcoma than with other sarcomas.⁷² Functional assessment should be performed at every visit.

Relapsed Disease

Local recurrence should be treated with wide excision if the lesions are resectable. RT or re-resection to achieve negative surgical margins should be considered following wide excision with positive surgical margins. Negative surgical margins should be observed. Unresectable recurrences are treated with RT. A recent study in 25 patients demonstrated effective local control and low acute toxicity with carbon ion RT in patients with recurrent skull base chordoma or chondrosarcoma.¹⁰³ Surgical excision or participation in a clinical trial

could be considered for patients with systemic recurrence of a high-grade chondrosarcoma. In a recent retrospective analysis of 10 patients with unresectable recurrent chondrosarcoma, the combination of sirolimus and cyclophosphamide was well tolerated resulting in a disease control rate of 70% (10% of patients had objective response and 60% of patients had stable disease).¹⁰⁴ The guidelines include the combination of sirolimus and cyclophosphamide as an option (category 2B) for patients with systemic recurrence of high-grade chondrosarcoma.

Chordoma

Chordomas arise from the embryonic remnants of the notochord and are more common in older adults. Chordomas predominantly arise in the axial skeleton, with the sacrum (50%–60%), skull base (25%–35%), and spine (15%) being the most common primary sites.^{5,105} Chordomas are classified into three histologic variants: conventional, chondroid, and dedifferentiated. Conventional chordomas are the most common histologic subtype characterized by the absence of cartilaginous or mesenchymal components. Chondroid chordomas present with histologic features of chordoma and cartilage elements, accounting for 5% to 15% of all chordomas. Dedifferentiated chordomas constitute about 2% to 8% of all chordomas and have features of high-grade pleomorphic spindle cell soft tissue sarcoma and an aggressive clinical course.¹⁰⁵

Chordomas of the spine and sacrum present with localized deep pain or radiculopathies, whereas cervical chordomas can cause airway obstruction or dysphagia and might present as an oropharyngeal mass. Neurologic deficit is more often associated with chordomas of the skull base and mobile spine than chordomas of sacrococcygeal region.⁵ A



review of 47 patients with skull base chordomas suggested that male sex was associated with worse PFS and OS.¹⁰⁶

Workup

Initial workup should include history and physical examination with adequate imaging (x-ray, CT, and MRI) of the primary site, screening MRI of spinal axis, and CT scan of the chest, abdomen, and pelvis. PET scan or bone scan (if PET scan is negative) can be considered for unusual cases. Benign notochordal cell tumors (BNCTs) are considered precursors to chordomas and do not require surgical management.^{107,108} CT scan and MRI may be useful in distinguishing BNCTs from chordomas.^{109,110}

For skull base chordomas, CT is useful to delineate bone destruction and the presence of calcifications, whereas MRI is the modality of choice to define the tumor margin from brain, characterization of the position and extension of tumors into the adjacent soft tissue structures, and visualization of blood vessels.^{111,112} For sacrococcygeal chordomas, CT and MRI are useful to assess the soft tissue involvement, calcifications, and epidural extension.¹¹³⁻¹¹⁵ MRI provides more precise and superior contrast with surrounding soft tissues compared with CT and is helpful to assess recurrent or metastatic lesions.^{113,114} CT is also of particular importance to assess bony involvement, calcifications, and soft tissue and epidural extension of spinal chordomas, whereas MRI is the best imaging modality to detect tumor extension, cord compression, local recurrence, and residual tumor in the surgical scar tissue after surgical resection.^{116,117} CT scan is also useful in planning the reconstruction of the resistant osseous defect in tumors of the proximal sacrum.

Biopsy to confirm histologic subtype should be done after imaging studies and may vary depending on the anatomic location of the tumor.

Needle biopsy is not recommended for skull base tumors. Suspected sacral chordomas should be biopsied dorsally rather than transrectally.

Treatment

Surgery

Wide excision with adequate margins is the preferred primary treatment for patients with chordoma.^{118,119} A recent retrospective analysis of 962 patients with chordoma identified in the SEER database demonstrated that surgery significantly improves OS.¹¹⁹ Several other reports have confirmed the prognostic significance of wide surgical margins, in terms of relapse-free survival (RFS) and OS, in patients with chordomas of the sacrum,¹²⁰⁻¹²² skull base,¹²³⁻¹²⁸ and spine.^{122,129}

Among patients with chordoma of the mobile spine, Boriani et al reported that only margin-free en bloc resection was associated with continuous disease-free survival (DFS) with a follow-up of longer than 5 years; 12 of 18 patients were continuously disease-free at an average of 8 years after en bloc resection, whereas all patients who were treated with intralesional excision experienced recurrences in fewer than 2 years.¹²⁹ In patients with chordomas of the sacrum and spine, Ruggieri et al reported a local recurrence rate of only 17% following wide surgical margins compared to 81% following intralesional excision or marginal surgery. Tzortzidis et al reported that aggressive microsurgical resection is associated with long-term, tumor-free survival with good functional outcome in patients with cranial base chordomas; gross total removal was achieved in 72% of patients resulting in local control rates of 50%.¹²⁴ In a recent 10-year meta-analysis that included 802 patients with skull base chordoma, Di Maio et al reported that patients with incomplete resection were 3.83 times more likely to experience a recurrence at 5 years than patients with complete resection.^{127,128}

**Radiation Therapy**

RT (preoperative, postoperative, or intraoperative) is used in combination with surgery to improve local control and DFS for patients with resectable sacral and skull base chordomas.^{93,123,130-135} In a retrospective series involving 24 patients with sacral and spine chordomas, combination of short-course preoperative RT, resection, and reduced-field, high-dose, postoperative RT resulted in 5-year DFS and local control rates of 54% and 72%, respectively.¹³² In a more recent retrospective series of 15 patients with sacrococcygeal chordoma who underwent surgical treatment, intralesional resection with postoperative RT was associated with lower local recurrence rates (20%) than extralesional resection without RT (100% with a mean time to recurrence of 2 years); the time to recurrence was also significantly longer in patients who received RT after surgery.¹³⁴ RT in combination with surgery is also associated with improved local recurrence rates in patients with conventional or chondroid chordomas of the skull base.^{131,133}

Particle beam RT (either alone or in combination with photon beam RT) with high-energy protons^{87-90,93,136-142} or carbon ions^{94,95,143-146} has resulted in local control rates ranging from 62% to 81% in patients with skull base as well as extracranial chordomas involving the spine and sacrum. In patients with sacral chordoma tumors treated with a combination of high-energy proton and photon beam RT, local control rates were higher in patients with primary compared to those with recurrent tumors.¹³⁸ A recent prospective trial of high-dose photon/proton RT in 50 patients with bone sarcomas of the spine (n=29 chordoma, 14 chondrosarcoma, 7 other histologies) resulted in 5 and 8-year actuarial local control (LC) rates of 94% and 85% for primary tumors and 81% and 74% primary and locally recurrent tumors. The 8-year actuarial risk of grades 3-4 RT toxicity was 13%.⁹³ Carbon ion RT

also resulted in preservation of urinary-anorectal function compared with surgery in patients with sacral chordomas.¹⁴⁶

Specialized techniques such as IMRT, SRS, and FSRT have also been associated with good local control rates in cranial as well as extracranial chordomas.¹⁴⁷⁻¹⁵¹

Systemic Therapy

Chordomas are not sensitive to chemotherapy except for the potentially dedifferentiated portion of high-grade dedifferentiated chordomas.¹⁵² Several signal transduction pathways including platelet-derived growth factor receptor, epidermal growth factor receptor (EGFR), and mammalian target of rapamycin (mTOR) have been implicated in the pathogenesis of chordomas, leading to the development of targeted therapies.^{153,154}

In a phase II trial of 56 patients with advanced chordoma treated with imatinib, a tyrosine kinase inhibitor, 70% of patients had stable disease. The clinical benefit rate (CBR) as determined by RECIST criteria (complete response + partial response and stable disease ≥6 months) was 64%, and the median progression-free survival (PFS) in the intention-to-treat population was 9 months.³⁶ Imatinib in combination with cisplatin or sirolimus has also been effective in a small series of patients with advanced chordoma resistant to prior imatinib therapy.^{155,156}

The efficacy of EGFR inhibitors such as erlotinib and lapatinib has also been demonstrated in patients with advanced chordoma resistant to imatinib.¹⁵⁷⁻¹⁵⁹ In a phase II study of 18 patients with locally advanced and metastatic chordoma, lapatinib induced partial response in 33% of patients and 39% of patients had stable disease, based on Choi response criteria, whereas all patients had stable disease based on

RECIST criteria.¹⁵⁹ The median PFS was 6 months and 8 months (with a CBR of 22%) based on Choi and RECIST criteria, respectively.

NCCN Recommendations

Tumor location is the most important variable that determines the choice of the primary treatment for patients with conventional or chondroid chordomas. Dedifferentiated chordomas are usually managed as described in the NCCN Guidelines for Soft Tissue Sarcoma.

Wide excision with or without RT is the primary treatment option for patients with resectable conventional or chondroid chordomas of the sacrum and mobile spine.^{118,119} Intralesional excision with or without RT (followed by MRI to assess the adequacy of resection) is the treatment of choice for patients with resectable skull base tumors of conventional or chondroid histology. Maximal safe resection is recommended when appropriate.¹²⁶ Adjuvant treatment with RT can be considered for large extracompartmental tumors or for positive surgical margins following resection. Postoperative RT has been associated with improved local control and DFS following surgery with macroscopic surgical margins or intralesional excision.^{130,133,134,160,161} Re-resection, if necessary, can be considered for skull base tumors with positive surgical margins.

RT is the primary treatment option for patients with unresectable chordomas, irrespective of the location of the tumor.

Surveillance

Surveillance consists of a physical exam, imaging (x-ray, MRI ± CT) of surgical site as clinically indicated, chest imaging (every 6 months for 5 years and annually thereafter), and annual cross-sectional abdominal imaging.

Relapsed Disease

Chordomas are characterized by a high rate of local recurrence and distant metastases to lungs, bone, soft tissue, lymph nodes, liver, and skin have been reported in up to 40% of patients with local recurrence.^{120,136,162,163} Among patients with recurrent chordomas of skull base and spine, Fagundes et al reported a higher 2-year actuarial OS rate for patients treated with subtotal resection than those who received supportive care only (63% and 21%, respectively; $P = .001$).¹³⁶ However, some studies have reported that surgery and RT are associated with lower local control rates for recurrent tumors than for primary tumors in patients with sacral chordomas.^{138,149} A recent study in 25 patients demonstrated effective local control and low acute toxicity with carbon ion RT in patients with recurrent skull base chordoma or chondrosarcoma.¹⁰³

Patients with recurrent disease can be managed with surgery and/or RT and/or systemic therapy. The guidelines have included imatinib with or without cisplatin or sirolimus, erlotinib, sunitinib, and lapatinib (for patients with EGFR-positive disease) as systemic therapy options for patients with recurrent tumors.

Ewing's Sarcoma Family of Tumors

ESFTs are a group of small round-cell neoplasms that include Ewing's sarcoma, primitive neuroectodermal tumor (PNET), Askin's tumor, PNET of bone, and extraosseous Ewing's sarcoma. Ewing's sarcoma is characterized by the fusion of the *EWS* gene (*EWSR1*) on chromosome 22q12 with various members of the *ETS* gene family (*FLI1*, *ERG*, *ETV1*, *ETV4*, and *FEV*).^{7,8} The *EWS-FLI1* fusion transcript resulting from the fusion of *EWS* and *FLI1* on chromosome 11 and the corresponding chromosomal translocation, t(11;22)(q24;q12) is identified in about 85% of patients with Ewing's sarcoma.⁷ In 5% to 10%



of cases, *EWS* is fused with other members of the *ETS* gene family. In rare cases, *FUS* can substitute for *EWS* resulting in fusion transcripts with no *EWS* rearrangement [*FUS-ERG* fusion transcript resulting from the translocation t(16;21)(p11;q24) or *FUS-FEV* fusion transcript resulting from the translocation t(2;16)(q35;p11)].^{164,165} Ewing's sarcoma is also characterized by the strong expression of cell surface glycoprotein MIC2 (CD99).^{166,167} The expression of MIC2 may be useful in the differential diagnosis of Ewing's sarcoma and PNET from other small round-cell neoplasms, although it is not exclusively specific for these tumors.¹⁶⁸

Typically, ESFT occurs in adolescents and young adults. The most common primary sites are the pelvic bones, femur, and the bones of the chest wall, although any bone may be affected.¹⁹ When arising in a long bone, the diaphysis is the most frequently affected site. On imaging, the bone appears mottled. Periosteal reaction is classic and it is referred to as "onion skin" by radiologists.

Patients with ESFT, as with most patients with bone sarcomas, seek attention because of localized pain or swelling. Unlike other bone sarcomas, constitutional symptoms such as fever, weight loss, and fatigue are occasionally noted at presentation. Abnormal laboratory studies may include elevated serum LDH and leukocytosis.

Prognostic Factors

The important indicators of favorable prognosis include a distal/peripheral site of primary disease, tumor volume <100 mL, normal LDH level at presentation, and the absence of metastatic disease at the time of presentation.¹⁶⁹⁻¹⁷⁴ ESFT in the spine and sacrum is associated with significantly worse outcome and prognosis than primary ESFT in other sites.¹⁷⁵

Metastatic disease at presentation is the most significant adverse prognostic factor in ESFT, as it is for other bone sarcomas.^{22,173,176}

Lungs, bone, and bone marrow are the most common sites of metastasis. In a retrospective analysis of 975 patients from the EICESS Study Group, 5-year RFS was 22% for patients with metastatic disease at diagnosis compared with 55% for patients without metastases at diagnosis.²² Among patients with metastases, there was a trend for better survival for those with lung metastases compared to those with bone metastases or a combination of lung and bone metastases.²² Metastases to uncommon sites (ie, brain, liver, spleen) were associated with a worse prognosis in a retrospective study of 30 patients.¹⁷⁷ Poor histologic response to chemotherapy has also been identified as an adverse prognostic factor for EFS in patients with localized non-metastatic disease.^{172,178,179}

The results of the IESS study analyzing the clinicopathologic features of 303 cases of Ewing's sarcoma showed that patients with primary tumors in pelvic bones have lower survival rates compared with patients with lesions in distal bones of the extremities.¹⁸⁰ In a recent analysis of 53 patients (24 adult and 29 pediatric) with Ewing's sarcoma treated with chemotherapy, Gupta et al identified pelvic disease and time to local therapy as significant prognostic factors associated with EFS in a multivariate analysis.¹⁸¹ In another retrospective analysis of patients with Ewing's sarcoma from a large population-based cancer registry, Lee et al determined that adult age, Hispanic race, metastatic disease, large tumor size, and low socioeconomic status are poor prognostic factors for OS.¹⁸²

Workup

If ESFT is suspected as a diagnosis, the patient should undergo complete staging prior to biopsy. This should include CT of the chest;



MRI with or without CT of the primary site; PET scan and/or bone scan; and bone marrow biopsy and/or screening MRI of the spine and pelvis. In a recent systematic review and meta-analysis, Treglia et al have reported that the combination of PET or PET/CT with conventional imaging is a valuable tool for the staging and restaging of ESFT, with 96% sensitivity and 92% specificity.¹⁸³ An ongoing diagnostic study is comparing whole-body MRI and conventional imaging for detecting distant metastases in pediatric patients with ESFT, Hodgkin's lymphoma, non-Hodgkin's lymphoma, rhabdomyosarcoma, and neuroblastoma.

Cytogenetic and/or molecular studies of the biopsy specimen should be performed to evaluate the t(11;22) translocation. Preliminary reports suggest that *EWS-FLI1* translocation is associated with a better prognosis than other variants.¹⁸⁴⁻¹⁸⁶ However, recent reports from the EURO-EWING 99 study and the Children's Oncology Group study suggest that with currently available effective therapies, patients with Ewing's sarcoma have similar outcomes, regardless of fusion subtype in contrast to previous reports.^{187,188} In addition to *EWS*, *FUS* should be considered as a fusion gene partner in the molecular diagnosis to identify the rare cases of ESFTs with *FUS-ERG* or *FUS-FEV* fusion transcripts.^{164,165} Bone marrow biopsy should be considered to complete the workup. Since serum LDH has been shown to have prognostic value as a tumor marker, the guidelines have included this test as part of initial evaluation. Fertility consultation should be considered.

Treatment

Local Control Therapy

Surgery and RT are the local control treatment modalities used for patients with localized disease. There have been no randomized studies that have compared these two treatment modalities.

In patients with localized Ewing's sarcoma treated in cooperative intergroup studies there was no significant effect of local control modality (surgery, RT, or surgery plus RT) on OS or EFS rates.^{189,190} In the CESS 86 trial, although radical surgery and resection plus RT resulted in better local control rates (100% and 95%, respectively) than definitive RT (86%), there was no improvement in RFS or OS because of higher frequency of metastases after surgery.¹⁸⁹ In the INT-0091 study, the incidences of local failure were similar for patients treated with surgery or RT alone (25%), but surgery plus RT resulted in lower incidences of local failure (10.5%).¹⁹⁰ The 5-year EFS rate was also not significantly different between the groups (42%, 52%, and 47% for patients treated with surgery, RT, and surgery plus RT, respectively). Data from other retrospective analyses suggest that surgery (with or without postoperative RT) affords better local control than RT alone in patients with localized disease.^{191,192} The combined analysis of 1058 patients treated in the CESS 81, CESS 86, and EICESS 92 trials showed that the rate of local failure was significantly lower after surgery (with or without postoperative RT) than after definitive RT (7.5% vs. 26.3%, respectively; $P = .001$), whereas the local control rate with preoperative RT was comparable to that of the surgery group (5.3%).¹⁹¹ The most recent retrospective analysis of sequential studies (INT-0091, INT-0154, or AEWS0031) performed by the Children's Oncology Group also demonstrated that definitive RT was associated with a higher risk of local failure than surgery plus RT, but there was no effect on distant failure.¹⁹²

Definitive RT could be an effective treatment option for patients with tumors in anatomical locations not amenable to achieve surgery with wider resection margins.^{193,194} In a retrospective analysis of patients with Ewing's tumors of vertebrae treated in the CESS 81/86 and EICESS 92 studies, definitive RT resulted in a local control rate of 22.6%, which



was comparable to those of other tumor sites treated with definitive RT; EFS and OS at 5 years were 47% and 58%, respectively.¹⁹³ Tumor size and RT dose have been shown to be predictive of local control rates in patients with non-metastatic Ewing's sarcoma treated with chemotherapy and definitive RT.^{195,196} Local control therapy has also been associated with improved outcomes in patients with primary metastatic disease.¹⁹⁷⁻¹⁹⁹ In the EURO-EWING 99 trial, the 3-year EFS was significantly lower in patients with primary metastatic disease who did not receive any local control therapy compared to those treated with local therapy for primary tumor.¹⁹⁷

Chemotherapy

Multiagent chemotherapy regimens including ifosfamide and/or cyclophosphamide, etoposide, doxorubicin and/or dactinomycin, and vincristine have been shown to be effective in patients with localized Ewing's sarcoma in single as well as multi-institution collaborative trials in the United States and Europe. Neoadjuvant chemotherapy prior to surgery downstages the tumor and increases the probability of achieving a complete resection with microscopically negative margins. Adjuvant chemotherapy following surgical resection improves RFS and OS in a majority of patients.²⁰⁰⁻²⁰⁴

IESS-I and IESS-II showed that RT plus adjuvant chemotherapy with VACD (vincristine, dactinomycin, cyclophosphamide, and doxorubicin) was superior to VAC (vincristine, dactinomycin, and cyclophosphamide) in patients with localized non-metastatic disease.²⁰¹ The 5-year RFS rate was 60% and 24% for VACD and VAC, respectively ($P < .001$). The corresponding OS rate was 65% and 28% ($P < .001$).

The addition of ifosfamide, alone or in combination with etoposide to standard chemotherapy, has also been evaluated in patients with newly diagnosed, non-metastatic Ewing's sarcoma.^{202,205-209} In the Pediatric

Oncology Group-Children's Cancer Group (POG-CCG) study (INT-0091), 398 patients with nonmetastatic ESFT were randomized to receive chemotherapy with either VACD alone or alternating with ifosfamide and etoposide (VACD-IE) for a total of 17 cycles.²⁰² The 5-year EFS rate was significantly higher in the VACD-IE group than the VACD alone group (69% and 54%, respectively; $P = .005$). The 5-year OS rate was also significantly better among patients in the VACD-IE group (72% and 61%, respectively; $P = .01$). VACD-IE also was associated with lower incidences of local failure (11%) compared with VACD (30%) irrespective of the type of local control therapy; 5-year cumulative incidences of local failure were 30% in the VACD arm compared with 11% in the VACD-IE arm.¹⁹⁰

While dose escalation of alkylating agents in the VAC-IE regimen did not improve the outcome for patients with localized disease,²¹⁰ chemotherapy intensification through interval compression improved outcome in patients with localized disease.²¹¹ In a randomized trial for patients younger than 50 years with localized Ewing's sarcoma ($n = 568$), Womer et al reported that VAC-IE given on an every 2-week schedule was found to be more effective than VAC-IE given on an every-3-week schedule, with no increase in toxicity; median 5-year EFS was 73% and 65%, respectively.²¹¹

The addition of ifosfamide and/or etoposide to standard chemotherapy did not improve outcomes for patients with metastatic disease at diagnosis in all of the studies.^{202,205,207,212} In the INT 0091 study, which included 120 patients with metastatic disease, there was no significant difference in the EFS and OS rates between VACD-IE and VACD regimens.²⁰² The 5-year EFS rate was 22% for both regimens and the 5-year OS rate was 34% and 35% for the VACD-IE and VACD groups, respectively. In a study of 68 patients (44 patients with locoregional disease and 24 patients with distant metastases), Kolb et al reported



4-year EFS and OS rates of 82% and 89%, respectively, for patients with locoregional disease treated with intensive chemotherapy (doxorubicin and vincristine with or without high-dose cyclophosphamide) followed by ifosfamide and etoposide.²⁰⁷ In patients with distant metastases the corresponding survival rates were 12% and 18%, respectively. Miser et al also reported similar findings in patients with Ewing's sarcoma or PNET of bone with metastases at diagnosis.²¹²

The EICESS-92 study investigated whether cyclophosphamide has a similar efficacy as ifosfamide in patients with standard-risk Ewing's sarcoma (small localized tumors) and whether the addition of etoposide to a regimen already containing ifosfamide improves survival in patients with high-risk disease (large tumors or metastatic disease at diagnosis).²¹³ Patients with standard-risk disease were randomly assigned to VAIA (vincristine, dactinomycin, ifosfamide, and doxorubicin; n = 76) followed by either VAIA or VACA (vincristine, dactinomycin, cyclophosphamide, and doxorubicin; n = 79).²¹³ The 3-year EFS rates were 73% and 74%, respectively, for VACA and VAIA, suggesting that cyclophosphamide has the same efficacy as ifosfamide in this group of patients. Patients with high-risk disease were randomly assigned to VAIA or VAIA plus etoposide (EVAIA). The 3-year EFS rate was not significantly different between the two treatment groups (52% and 47%, respectively, for EVAIA and VAIA). However, there was some evidence that the addition of etoposide was associated with a greater survival benefit in the subgroup of patients without metastases ($P = .18$) than in those with metastases ($P = .84$).²¹³

As a follow-up to the EICESS-92 study, the Euro-EWING99-R1 trial evaluated cyclophosphamide as a replacement for ifosfamide as a part of consolidation therapy that also included vincristine and dactinomycin (VAC vs. VAI) after VIDE (vincristine, ifosfamide, doxorubicin, and etoposide) induction chemotherapy in 856 patients with standard-risk

Ewing's sarcoma. VAC was statistically not inferior to VAI, but was associated with a slight increase in events (-2.8% decrease in 3-year EFS). The proportion of patients experiencing severe hematologic toxicity was slightly higher in the VAC arm, but renal tubular function impairment was more significant for patients receiving VAI.²¹⁴

High-dose Therapy Followed by Stem Cell Transplant

High-dose therapy followed by stem cell transplant (HDT/SCT) has been evaluated in patients with localized as well as metastatic disease. HDT/SCT has been associated with potential survival benefit in patients with non-metastatic disease.^{215,216} However, studies that have evaluated HDT/SCT in patients with primary metastatic disease have shown conflicting results.²¹⁷⁻²²²

The EURO-EWING 99 study is the first large randomized trial designed to evaluate the efficacy and safety of multiagent induction chemotherapy with six courses of VIDE, local treatment (surgery and/or RT), and HDT/SCT in 281 patients with Ewing's sarcoma with primary disseminated disease.²¹⁸ After a median follow-up of 3.8 years, the EFS and OS rates at 3 years for the entire study cohort were 27% and 34%, respectively.²²² The EFS rates were 57% and 25%, respectively, for patients with complete and partial response after HDT/SCT. Patient's age, tumor volume, and extent of metastatic spread were identified as relevant risk factors. The outcome of patients with and without HDT/SCT was not performed because of the bias introduced early in the non-transplant group (82% of patients without HDT/SCT died after a median time of 1 year).

NCCN Recommendations

All patients with ESFT should be treated with the following protocol: primary treatment followed by local control therapy and adjuvant treatment.

Primary treatment consists of multiagent chemotherapy along with appropriate growth factor support for at least 12 weeks. Longer duration could be considered for patients with metastatic disease based on response. VAC/IE (vincristine, doxorubicin, and cyclophosphamide alternating with ifosfamide and etoposide) is the preferred regimen for patients with localized disease, whereas VAdriaC (vincristine, doxorubicin, and cyclophosphamide) is the preferred regimen for patients with metastatic disease.^{202,207,212} See *Bone Cancer Systemic Therapy Agents* in the algorithm for a list of other chemotherapy regimens that are recommended for patients with localized and metastatic disease.

Disease should be restaged with an MRI of the lesion and chest imaging following primary treatment. PET scan and/or bone scan can be used for restaging depending on the imaging technique that was used in the initial workup. Patients with stable or improved disease after primary treatment should be treated with local control therapy.

Local control options include wide excision, definitive RT with chemotherapy, or amputation in selected cases.^{191,193,195,197} The choice of local control therapy should be individualized and is dependent on tumor location, size, response to chemotherapy, patient's age, anticipated morbidity, and patient preference.¹⁹⁰

Adjuvant chemotherapy following wide excision or amputation is recommended for all patients regardless of surgical margins. The panel strongly recommends that the duration of chemotherapy following wide excision should be between 28 and 49 weeks depending on the type of regimen and the dosing schedule (category 1).²⁰⁰⁻²⁰² The addition of postoperative RT to chemotherapy is recommended for patients with positive or very close surgical margins.¹⁹¹ Denbo et al recently reported that in patients with smaller tumor size (<8 cm) and negative margins,

postoperative RT can be omitted without any decrement in OS.²²³ The 15-year estimated OS for patients who received adjuvant RT was 80% compared to 100% for those who did not. The guidelines have included adjuvant chemotherapy alone for patients treated with wide excision and negative margins.

Progressive disease following primary treatment is best managed with RT and/or surgery to primary site followed by chemotherapy or best supportive care.

Surveillance

Surveillance of patients with ESFT should include a physical exam, CBC and other laboratory studies, and imaging of the chest and primary site every 2 to 3 months. Surveillance intervals should be increased after 2 years. Long-term surveillance should be performed annually after 5 years (category 2B).²²⁴

Relapsed or Refractory Disease

About 30% to 40% of patients with ESFT experience recurrence (local and/or distant) and have a very poor prognosis. Patients with a longer time to first recurrence have a better chance of survival following recurrence. Late relapse (2 years or more from the time of original diagnosis), lung-only metastases, local recurrence that can be treated with radical surgery, and intensive chemotherapy are the most favorable prognostic factors, whereas early relapse (less than 2 years from the time of original diagnosis) with metastases in lungs and/or other sites, recurrence at local and distant sites, elevated LDH at initial diagnosis, and initial recurrence are considered as adverse prognostic factors.²²⁵⁻²²⁸ In a recent retrospective analysis, site of first relapse and time to first relapse were significant prognostic factors for adult patients with localized Ewing's sarcoma.²²⁹ The probability of 5-year post-relapse survival was 50% and 13%, respectively, for patients with



local and distant relapse. The probability of 5-year post-relapse survival was also significantly higher for patients with late relapse than for those with early relapse.^{22,229,230}

Ifosfamide in combination with etoposide with or without carboplatin has been evaluated in clinical trials for the treatment of patients with relapsed or refractory sarcoma.^{231,232} In a phase II study, the combination of ifosfamide with mesna and etoposide was highly active with acceptable toxicity in the treatment of recurrent sarcomas in children and young adults.²³¹ In phase I/II studies conducted by the Children's Oncology Group, the overall response rate in patients with recurrent or refractory sarcoma was 51%; OS at 1 and 2 years was 49% and 28%, respectively. OS appeared significantly improved in patients whose disease had complete or partial response.²³² A recent review of 239 patients with ESFT suggested the potential risk reduction benefit of high-dose versus conventional chemotherapy for treating first relapse.²³³ High-dose ifosfamide with or without etoposide is included as a second-line therapy for relapsed, refractory, or metastatic disease.^{231,234}

Non-ifosfamide-based chemotherapy regimens have also demonstrated activity in patients with relapsed or refractory bone sarcomas. Docetaxel in combination with gemcitabine was found to be well tolerated, resulting in an overall objective response rate of 29% in children and young adults with refractory bone sarcomas; median duration of response was 4.8 months.²³⁵ Topoisomerase I inhibitors (topotecan and irinotecan) in combination with cyclophosphamide and temozolomide have also been associated with favorable response rates in patients with relapsed or refractory bone sarcomas.²³⁶⁻²⁴² In a series of 54 patients with relapsed or refractory Ewing's sarcoma, cyclophosphamide and topotecan induced responses in 44% of patients (35% of patients had complete response and 9% had partial

response).²³⁷ After a median follow-up of 23 months, 26% of patients were in continuous remission. In a retrospective analysis of patients with recurrent or progressive Ewing's sarcoma, irinotecan and temozolomide resulted in an overall objective response rate of 63%. The median time to progression (TTP) for all the evaluable patients (n = 20) was 8.3 months (16.2 months for the subset of patients with recurrent disease).²⁴⁰ Patients who were in a 2-year first remission and those with primary localized disease had better median TTP compared to those who relapsed within 2 years from diagnosis and patients with metastatic disease at diagnosis.

Combination therapy with vincristine, irinotecan, and temozolomide also appears to be active and well-tolerated in patients with relapsed or refractory Ewing's sarcoma, with an overall response rate of 68.1%.²⁴³ A review of 107 patients with relapsed or refractory Ewing's sarcoma examined the combination of etoposide with a platinum agent (ie, cisplatin or carboplatin), suggesting that further study of etoposide/carboplatin may be warranted.²⁴⁴ HDT/SCT has been associated with improved long-term survival in patients with relapsed or progressive Ewing's sarcoma in small, single institution studies.²⁴⁵⁻²⁴⁷ The role of this approach is yet to be determined in prospective randomized studies.

NCCN Recommendations

Treatment options for patients with relapsed or refractory disease include participation in a clinical trial and chemotherapy with or without RT. If a relapse is delayed, as sometimes occurs with this sarcoma, re-treatment with a previously effective regimen may be useful. See *Bone Cancer Systemic Therapy Agents* in the algorithm for a list of other chemotherapy regimens recommended for patients with relapsed or refractory disease.



All patients with recurrent and metastatic disease should be considered for clinical trials investigating new treatment approaches.

Giant Cell Tumor of Bone

GCTB is a rare benign primary tumor of the bone accounting for about 3% to 5% of all primary bone tumors, with a strong tendency for local recurrence and that may metastasize to the lungs.^{248,249} GCTB usually occurs between 20 and 40 years of age. Distal femur and proximal tibia are the most common primary sites. Malignant transformation to high-grade osteosarcoma has been observed in rare cases and is associated with a poor prognosis.^{250,251}

Workup

Initial workup should include history and physical examination with adequate imaging (x-ray, CT, and MRI) of the primary site. CT is useful to define the extent of cortical destruction, whereas MRI is the preferred imaging modality to assess the extension of tumors into the adjacent soft tissue and neurovascular structures.^{252,253} Chest imaging is essential to identify the presence of metastatic disease. Bone scan can be considered for unusual cases. Biopsy is essential to confirm the diagnosis. Brown tumor of hyperparathyroidism should be considered as a differential diagnosis, though routine evolution of serum calcium, phosphate, and parathyroid hormone levels can help exclude this diagnosis.²⁵⁴

Treatment

Surgery

Wide excision and intralesional curettage are the two surgical treatment options for patients with resectable tumors.²⁵⁵⁻²⁶¹ Wide excision is associated with a lower risk of local recurrence than intralesional curettage, with the local recurrence rates ranging from 0% to 12% for

wide excision and 12% to 65% for intralesional curettage. In some studies, the extent of intralesional excision and the tumor stage have been identified as prognostic indicators for risk of recurrence.²⁶²⁻²⁶⁴ Blackley et al reported a local recurrence rate of 12% in 59 patients who were treated with curettage with high-speed burr and bone grafting, which was similar to that observed with the use of adjuvants; the majority of the patients had grade II or III tumors.²⁶³ In another retrospective analysis of 137 patients, Prosser et al reported local recurrences in 19% of patients following curettage as a primary treatment; local recurrence rate was only 7% for patients with grade I and II tumors confined to the bone compared with 29% for those with grade III tumors with extraosseous extension.²⁶⁴

Surgical adjuvants have been used in conjunction with intralesional curettage to improve local control rates. However, the findings from studies that have evaluated intralesional curettage, with and without adjuvant in the same cohort of patients with primary or recurrent GCTB, are inconsistent, with some reporting decreased local recurrence rates with the use of adjuvants.^{259,265-268} Others, however, have reported no significant difference in local recurrence rates with and without adjuvants.^{121,269,270}

Wide excision is also associated with poor functional outcome and greater surgical complications.²⁷¹⁻²⁷⁵ Therefore, intralesional curettage is considered the treatment of choice in a majority of patients with stage I or II tumors. Wide excision is usually reserved for more aggressive stage III tumors with extraosseous extension or otherwise unresectable tumors.^{264,276-279}

Radiation Therapy

RT has been used either as a primary treatment or in combination with surgery to improve local control and DFS for patients with marginally

resected, unresectable, progressive, or recurrent disease.²⁸⁰⁻²⁹⁰ In a recent retrospective analysis of 58 patients with GCTB (45 patients with primary tumor and 13 patients with recurrent tumor) treated with RT, the 5-year local control and OS rates were 85% and 94%, respectively.²⁹⁰ Median follow-up was 8 years. In this analysis, patient age was the only prognostic factor with the local control rates (96% for younger patients vs. 73% for the older group) as well as OS (100% vs. 87%) and DFS rates (96% vs. 65%). Other studies have identified tumor size >4 cm, recurrent tumors, and RT doses of 40 Gy or less as negative prognostic factors for local control.²⁸⁶⁻²⁸⁸

Specialized techniques such as 3-D conformal RT and IMRT have also been associated with good local control rates in patients with GCTB in locations that are not amenable to complete surgical resection.^{291,292}

Systemic Therapy

Denosumab (a fully humanized monoclonal antibody against the RANK ligand) has demonstrated significant activity in patients with unresectable or recurrent GCTB.²⁹³⁻²⁹⁵ In an open-label, phase II study (n =37), denosumab induced tumor response (defined as the elimination of at least 90% of giant cells or no radiologic progression of the target lesion for up to 25 weeks) in 86% (30 of 35 evaluable patients) of patients with unresectable or recurrent GCTB.²⁹³ Chawla et al recently reported the results of an interim analysis of an open-label, parallel-group, phase II study of 282 patients with GCTB.²⁹⁵ In this study, patients were divided into 3 cohorts: those with unresectable GCTB (cohort 1), those with resectable GCTB associated with severe surgical morbidity (cohort 2), and those transferred from a previous study of denosumab for GCTB (cohort 3). Denosumab was associated with tumor responses and reduced need for morbid surgery. After median follow-up of 13 months, 96% of evaluable patients (163 of 169) in cohort 1 had no disease progression. In cohort 2, after a follow-up in

cohort 2 was 9.2 months, 74% of evaluable patients (74 of 100) had no surgery and 62% (16 of 26) of patients underwent surgery with less morbidity. Clinically significant reductions in pain were reported by over half of the study patients within 2 months.²⁹⁶ In June 2013, denosumab was approved by the FDA for the treatment of adults and skeletally mature adolescents with GCTB that is unresectable or where surgical resection is likely to result in severe morbidity.

Recent phase II trial data have suggested that sequential FDG-PET imaging appears to be a sensitive tool for early detection of tumor response to denosumab treatment.²⁹⁷

NCCN Recommendations

Localized Disease

Intralesional excision with or without an effective adjuvant is an adequate primary treatment for resectable tumors.^{121,269,270}

Serial arterial embolizations have been shown to be effective in the management of patients with giant cell tumors of the extremities, especially for tumors with large cortical defects or joint involvement and for those with large giant cell tumors of the sacrum.²⁹⁸⁻³⁰¹ A few case reports have reported the efficacy of interferon and pegylated interferon in the management of GCTB.³⁰²⁻³⁰⁵

For patients with lesions that are resectable with unacceptable morbidity or unresectable axial lesions, the guidelines have included serial embolizations, denosumab, interferon, or pegylated interferon as primary treatment options. RT has been associated with increased risk of malignant transformation and should be used in patients with tumors that are not amenable to embolization, denosumab, or interferons.



Following primary treatment, patients with stable/improved disease can be observed. For patients with stable/improved disease with incomplete healing following primary treatment, intralesional excision is recommended, if the lesion has become resectable. Patients with unresectable disease should be retreated with serial embolization, and/or denosumab, and/or interferon or pegylated interferon. The guidelines recommend continuation of treatment until disease progression.

Metastatic Disease

For patients presenting with resectable metastases, the guidelines recommend that primary tumor be managed as described above for localized disease.^{248,249,306,307} Intralesional excision is recommended for resectable metastatic sites. Denosumab, interferon or pegylated interferon, observation, and RT are included as options for patients with unresectable metastases.

Surveillance

Surveillance should include a physical exam, imaging (x-ray, MRI ± CT) of the surgical site as clinically indicated, and chest imaging every 6 months for 2 years then annually thereafter.

Recurrent disease (local or metastatic) should be managed as per primary treatment for localized disease or metastatic disease at presentation.

Osteosarcoma

Osteosarcoma is the most common primary malignant bone tumor in children and young adults. The median age for all patients with osteosarcoma is 20 years. In adults older than 65 years, osteosarcoma develops as a secondary malignancy related to Paget's disease of the

bone.¹⁵ Osteosarcoma is broadly classified into three histologic subtypes (intramedullary, surface, and extraskeletal).³⁰⁸

High-grade intramedullary osteosarcoma is the classic or conventional form comprising nearly 80% of osteosarcoma.³⁰⁸ It is a spindle cell tumor that produces osteoid or immature bone. The most frequent sites are the metaphyseal areas of the distal femur or proximal tibia, which are the sites of maximum growth. Low-grade intramedullary osteosarcoma comprises less than 2% of all osteosarcomas and the most common sites are similar to that of conventional osteosarcoma.³⁰⁹

Parosteal and periosteal osteosarcomas are juxtacortical or surface variants. Parosteal osteosarcomas are low-grade lesions accounting for up to 5% of all osteosarcomas.³⁰⁹ The most common site is the posterior distal femur. This variant tends to metastasize later than the conventional form. Transformation of low-grade parosteal osteosarcoma into high-grade sarcoma has been documented in 24% to 43% of cases.^{310,311} Periosteal osteosarcomas are intermediate-grade lesions most often involving the femur followed by the tibia.³⁰⁹ High-grade surface osteosarcomas are very rare accounting for 10% of all juxtacortical osteosarcomas.^{312,313}

Pain and swelling are the most frequent early symptoms. Pain is often intermittent in the beginning and a thorough workup sometimes is delayed because symptoms may be confused with growing pains. Osteosarcoma spreads hematogenously, with the lung being the most common metastatic site.

For treating extraskeletal osteosarcomas, please see the NCCN Guidelines for Soft Tissue Sarcoma.



Prognostic Factors

Tumor site and size, patient age, presence and location of metastases, histologic response to chemotherapy, and type of surgery and surgical margins are significant prognostic factors for patients with osteosarcoma of the extremities and trunk.³¹⁴⁻³¹⁹ In an analysis of 1702 patients with osteosarcoma of trunk or extremities treated in the COSS group protocols, patient age at diagnosis, tumor site, and primary metastases were identified as predictors of survival.³¹⁶ In patients with extremity osteosarcomas, in addition to these variables, size and location within the limb at the time of diagnosis also had significant influence on outcome.³¹⁶ All factors except age were significant in multivariate testing, with surgical remission and histologic response to chemotherapy emerging as the key prognostic factors. In a recent meta-analysis of data from prospective neoadjuvant chemotherapy trials in 4838 patients with osteosarcoma, female sex was associated with increased chemotherapy-induced tumor necrosis and greater OS, and children had better outcomes than adolescents and adults.³²⁰ In a recent report of the combined analysis of 3 European Osteosarcoma Intergroup randomized controlled trials, Whelan et al reported that good histologic response to preoperative chemotherapy, distal location (other than proximal humerus/femur), and female gender were associated with improved survival.³¹⁹ However, high body mass index (BMI) in patients with osteosarcoma was associated with lower OS compared with patients with normal BMI.³²¹

In patients with proven primary metastatic osteosarcoma, the number of metastases at diagnosis and the completeness of surgical resection of all clinically detected tumor sites are of independent prognostic value.²³ Patients with one or a few resectable pulmonary metastases have a survival rate that approaches that of patients with no metastatic disease.^{322,323}

Elevated serum ALP and LDH levels have also been identified as prognostic indicators in patients with osteosarcoma.^{315,317,318} In a cohort of 1421 patients with osteosarcoma of the extremity, Bacci et al reported significantly higher serum LDH levels in patients with metastatic disease at presentation than in patients with localized disease (36.6% vs. 18.8%; $P < .0001$).³¹⁷ The 5-year DFS correlated with serum LDH levels (39.5% for patients with high LDH levels and 60% for those with normal values). In another retrospective analysis of 789 patients with osteosarcoma of the extremity, Bacci et al reported that the serum ALP level was a significant prognostic factor of EFS in patients with osteosarcoma of extremity; the 5-year EFS rate was 24% for patients with a serum ALP value of more than 4 times higher than the normal value and 46% for patients with high values below this limit ($P < 0.001$).³¹⁸ However, in multivariate analysis, these markers did not retain their prognostic significance when compared to tumor volume, age, and histologic response to chemotherapy.^{315,317}

Workup

Osteosarcomas present both a local problem and a concern for distant metastasis. Initial workup should include imaging of the primary site (MRI, with or without CT), chest imaging, PET scan, and/or bone scan. More detailed imaging (CT or MRI) of abnormalities identified on primary imaging is required for suspected metastatic disease.

Plain radiographs of osteosarcomas show cortical destruction and irregular reactive bone formation. Bone scan, while uniformly abnormal at the lesion, may be useful to identify additional synchronous lesions. MRI provides excellent soft-tissue contrast and may be essential for operative planning. MRI is the best imaging modality to define the extent of the lesion within the bone as well as within the soft tissues, to detect “skip” metastases and to evaluate anatomic relationships with



the surrounding structures. In addition, ALP and LDH are frequently elevated in patients with osteosarcoma. Serum LDH was significantly higher in patients with metastatic disease at presentation than in patients with localized disease.³¹⁷

Treatment

Surgery

Surgery (limb-sparing surgery or amputation) remains an essential part of management of patients with osteosarcoma.³²⁴ Studies that have compared limb-sparing surgery and amputation in patients with high-grade, non-metastatic osteosarcoma have not shown any significant difference in survival and local recurrence rates between these procedures.³²⁵⁻³²⁷ However, limb-sparing surgery is associated with better functional outcomes.³²⁸ In patients with high-grade osteosarcomas with good histologic response to neoadjuvant chemotherapy, limb-sparing surgery is considered the preferred surgical modality if wide surgical margins could be achieved.^{325,329} Amputation is generally reserved for patients with tumors in unfavorable anatomical locations not amenable to limb-sparing surgery with adequate surgical margins.^{324,329}

Chemotherapy

The addition of adjuvant and neoadjuvant chemotherapy regimens to surgery has improved outcomes in patients with localized osteosarcoma. Early trials used chemotherapy regimens including at least three or more of the following drugs: doxorubicin, cisplatin, bleomycin, cyclophosphamide or ifosfamide, dactinomycin, and high-dose methotrexate.³³⁰⁻³³⁵ Subsequent clinical trials have demonstrated that short, intensive chemotherapy regimens including cisplatin and doxorubicin with or without high-dose methotrexate and ifosfamide produce excellent long-term results, similar to those achieved with multiagent chemotherapy.³³⁶⁻³⁴³

In a randomized trial conducted by the European Osteosarcoma Group, the combination of doxorubicin and cisplatin was better tolerated compared to a multi-drug regimen with no difference in survival between the groups in patients with operable, non-metastatic osteosarcoma.³³⁷ The 3-year and 5-year OS rates were 65% and 55%, respectively, in both groups. The 5-year PFS rate was 44% in both groups. In the INT-0133 study, which compared the 3-drug regimen (cisplatin, doxorubicin, and methotrexate) with the 4-drug regimen (cisplatin, doxorubicin, methotrexate, and ifosfamide) for the treatment of patients with non-metastatic resectable osteosarcoma, there was no difference in the 6-year EFS (63% and 64%, respectively) and OS (74% and 70%, respectively) between the two groups.³⁴³

Chemotherapy regimens without doxorubicin or cisplatin have also been evaluated in patients with localized osteosarcoma with the aim of minimizing long-term cardiotoxicity and ototoxicity.^{344,345} In a phase II study, the combination of cisplatin, ifosfamide, and epirubicin was active and reasonably well tolerated in patients with nonmetastatic extremity osteosarcoma.³⁴⁴ With a median follow-up of 64 months, the 5-year DFS and OS rates were 41.9% and 48.2%, respectively. In another randomized multicenter trial (SFOP-OS94), the combination of ifosfamide and etoposide resulted in a higher histologic response rate than the regimen containing high-dose methotrexate and doxorubicin (56% and 39%, respectively). However, the 5-year OS was similar in both arms and there was no significant difference in 5-year EFS rates.³⁴⁵

Good histopathologic response (greater than 90% necrosis) to neoadjuvant chemotherapy has been shown to be predictive of survival regardless of the type of chemotherapy administered after surgery.^{224,346,347} In an analysis of 881 patients with non-metastatic osteosarcoma of the extremities treated with neoadjuvant



chemotherapy and surgery at the Rizzoli Institute, Bacci et al showed that the 5-year DFS and OS correlated significantly with histologic response to chemotherapy.³⁴⁸ The 5-year DFS and OS in good and poor responders were 67.9% vs. 51.3% ($P < .0001$) and 78.4% vs. 63.7% ($P < .0001$), respectively. A report from the Children's Oncology Group also confirmed these findings; the 8-year postoperative EFS and OS rates were 81% and 87%, respectively, in good responders.³⁴⁶ The corresponding survival rates were 46% and 52%, respectively, in poor responders.

The addition of muramyl tripeptide phosphatidylethanolamine (MTP-PE) to chemotherapy has also been evaluated in patients with osteosarcoma.^{343,349} The addition of MTP-PE to chemotherapy was associated with a statistically significant improvement in 6-year OS (70% to 78%) and a trend toward better EFS in patients with non-metastatic resectable osteosarcoma.³⁴³ However, the improvement was not statistically different in patients with metastatic disease.³⁴⁹ MTP-PE is not approved by the FDA for the treatment of patients with osteosarcoma.

Localized Disease

The guidelines recommend wide excision as the primary treatment for patients with low-grade (intramedullary and surface) osteosarcomas and periosteal lesions. Chemotherapy prior to wide excision could be considered for patients with periosteal lesions. Although chemotherapy (neoadjuvant or adjuvant) has been used in the treatment of patients with periosteal osteosarcoma, there are no data to support that the addition of chemotherapy to wide excision improves outcome in patients with periosteal osteosarcoma.^{350,351} In a review of 119 patients with periosteal sarcoma published by the European Musculo-Skeletal Oncology Society, the use of neoadjuvant

chemotherapy was not a prognostic factor, although it was used in the majority of the patients.³⁵¹ More recently, Cesari and colleagues also reported similar findings; the 10-year OS rate was 86% and 83%, respectively, for patients who received adjuvant chemotherapy with surgery and for those who underwent surgery alone ($P = .73$).³⁵⁰ Long-term results (>25 years of follow-up) from patients with high-grade, localized osteosarcoma reveal significant benefits of adjuvant chemotherapy on DFS and OS.³⁴⁷

Following wide excision (of resectable lesions), the guidelines have included postoperative chemotherapy with a category 2B recommendation for patients with low-grade (intramedullary and surface) or periosteal sarcomas with pathologic findings of high-grade disease.

Preoperative chemotherapy prior to wide excision is preferred for those with high-grade osteosarcoma (category 1).^{322,336-338,341-345,352} Selected elderly patients may benefit from immediate surgery. Following wide excision, patients whose disease has a good histologic response (amount of viable tumor is less than 10% of the tumor area) should continue to receive several more cycles of the same chemotherapy. Patients whose disease has a poor response (viable tumor is $\geq 10\%$ of the tumor area) could be considered for chemotherapy with a different regimen (category 2B). However, attempts to improve the outcome of poor responders by modifying the adjuvant chemotherapy remain unsuccessful.³⁵³⁻³⁵⁷ Upon review of the evidence, this recommendation was changed from category 2A to category 2B. Surgical re-resection with or without RT can be considered for positive surgical margins. In a study of 119 patients with osteosarcoma of the head and neck, combined modality treatment with surgery and RT (versus surgery alone) improved local control and OS for patients with positive or uncertain surgical margins.³⁵⁸



An ongoing randomized trial of the European and American Osteosarcoma Study (EURAMOS) Group is evaluating treatment strategies for resectable osteosarcoma based on histologic response to preoperative chemotherapy. RT or adjuvant chemotherapy is recommended if the sarcoma remains unresectable following preoperative chemotherapy. First results from this trial showed that the addition of maintenance pegylated interferon (IFN)- α -2b therapy to MAP in the adjuvant setting did not improve outcomes for “good responders” to preoperative chemotherapy.³⁵⁹ However, the authors note that a significant portion of patients in the IFN arm did not receive the intended dose of IFN- α -2b due to failure to initiate therapy or premature termination of therapy. Combined photon/proton or proton beam RT has been shown to be effective for local control in some patients with unresectable or incompletely resected osteosarcoma.^{360,361}

Chemotherapy should include appropriate growth factor support. See the NCCN Guidelines for Myeloid Growth Factors in Cancer Treatment for growth factor support. See *Bone Cancer Systemic Therapy Agents* in the algorithm for a list of specific chemotherapy regimens.

Metastatic Disease at Presentation

Approximately 10% to 20% of patients present with metastatic disease at diagnosis.^{23,362} The number of metastases at diagnosis and complete surgical resection of all clinically detected tumor sites are of independent prognostic value in patients with primary metastatic disease at presentation.²³ Unilateral metastases and lower number of lung nodules were associated with improved outcomes with chemotherapy in patients with synchronous lung metastases.^{322,323} The 2-year DFS rate was significantly higher for patients with only one or two metastatic lesions than for patients with 3 or more lesions (78% and 28%, respectively).³²²

Although chemotherapy is associated with improved outcomes in patients with non-metastatic, high-grade, localized osteosarcoma, the results were significantly poorer in patients with metastatic disease at presentation.³⁶²⁻³⁶⁴ In a study of 57 patients with metastatic disease at presentation treated with cisplatin, doxorubicin, and high dose of methotrexate and ifosfamide, the 2-year EFS and OS rates were 21% and 55%, respectively, compared to 75% and 94% in patients with non-metastatic disease at presentation, treated with the same chemotherapy protocol.³⁶⁴ High-dose ifosfamide plus etoposide was examined in a phase II/III trial of 43 patients with newly-diagnosed metastatic osteosarcoma, revealing an overall response rate of 59% \pm 8%, but considerable toxicity.³⁶⁵

Among patients with primary metastases treated in cooperative osteosarcoma trials, long-term survival rates were higher for patients whose metastases were excised following chemotherapy and surgery of the primary tumor compared to those patients whose metastases could not be removed (48% and 5%, respectively).³⁶⁶ The combination of aggressive chemotherapy with simultaneous resection of primary and metastatic lesions has also resulted in improved outcomes in patients with osteosarcoma of the extremity with lung metastases at presentation.³⁶⁷

For patients with resectable metastases (pulmonary, visceral, or skeletal) at presentation, the guidelines recommend preoperative chemotherapy followed by wide excision of the primary tumor. Chemotherapy and metastasectomy are included as options for the management of metastatic disease. Unresectable metastatic disease should be managed with chemotherapy and/or RT followed by reassessment of the primary site for local control.

Surveillance

Once treatment is completed, surveillance should occur every 3 months for 2 years, then every 4 months for year 3, then every 6 months for years 4 and 5, and annually thereafter. Surveillance should include a complete physical, chest imaging, and imaging of the primary site. PET scan and/or bone scan (category 2B) may also be considered. Functional reassessment should be performed at every visit.

Relapsed or Refractory Disease

About 30% of patients with localized disease and 80% of the patients presenting with metastatic disease will relapse. The presence of solitary metastases, time to first relapse, and complete resectability of the disease at first recurrence have been reported to be the most important prognostic indicators for improved survival, whereas patients not amenable to surgery and those with a second or a third recurrence have a poor prognosis.³⁶⁸⁻³⁷³ In patients with primary non-metastatic osteosarcoma, a longer relapse-free interval to pulmonary metastases was significantly associated with better survival.³⁷¹ The prognostic significance of surgical clearance among patients with second and subsequent recurrences was also confirmed in a recent report of survival estimates derived from large cohorts of unselected patients treated at the COSS group trials.³⁷⁴

The combination of etoposide with cyclophosphamide or ifosfamide has been evaluated in clinical trials.^{231,375,376} In a phase II trial of the French Society of Pediatric Oncology, high-dose ifosfamide and etoposide resulted in a response rate of 48% in patients with relapsed or refractory osteosarcoma.³⁷⁶ In another phase II trial, cyclophosphamide and etoposide resulted in a 19% response rate and 35% rate of stable disease in patients with relapsed high-risk osteosarcoma.³⁷⁵ PFS at 4 months was 42%.

Single-agent gemcitabine and combination regimens such as docetaxel and gemcitabine, cyclophosphamide and topotecan, ifosfamide, carboplatin, and etoposide have also been effective in the treatment of patients with relapsed or refractory bone sarcomas.^{232,235,239,377,378}

Samarium-153 ethylene diamine tetramethylene phosphonate (Sm 153-EDTMP) is a beta particle–emitting bone-seeking radiopharmaceutical, and has been evaluated in patients with locally recurrent or metastatic osteosarcoma or skeletal metastases.^{379,380} Andersen et al have reported that Sm 153-EDTMP with peripheral blood progenitor cell support had low non-hematologic toxicity and provided pain palliation for patients with osteosarcoma local recurrences or osteoblastic bone metastases.³⁷⁹ Results of a dose finding study also demonstrated that Sm 153-EDTMP can be effective in the treatment of patients with high-risk osteosarcoma.³⁸⁰

Radium-223 dichloride (Ra 223) is a bone-seeking, alpha particle–emitting radiopharmaceutical that is under early-stage investigation for treating metastatic or recurrent osteosarcoma.^{381,382} This agent is approved in the United States for treating bone metastases associated with castration-resistant prostate cancer. Preliminary studies suggest that this agent is active in osteosarcoma and may have less marrow toxicity and greater efficacy than beta particle–emitting radiopharmaceuticals such as Sm 153-EDTMP.^{382,383}

Targeted inhibition of a variety of molecular pathways such as mTOR, SRC family of kinases, and vascular endothelial growth factor receptors (VEGFRs) are being evaluated in clinical trials to improve outcomes in patients with relapsed or refractory osteosarcoma. In a phase II trial of the Italian Sarcoma Group (n = 30), sorafenib (VEGFR inhibitor) demonstrated activity in patients with relapsed and unresectable high-grade osteosarcoma after failure of standard multimodal



therapy.³⁸⁴ The PFS at 4 months (primary endpoint) was 46%. Median PFS and OS were 4 months and 7 months, respectively. The CBR (defined as no progression at 6 months) was 29%. Partial response and stable disease were seen in 8% and 34% of patients, respectively, and were durable for 6 months or more in 17% of patients.

To extend the duration of activity, a recent study examined sorafenib combined with everolimus for patients with unresectable or relapsed high-grade osteosarcoma (n = 38).³⁸⁵ Data suggested that this regimen is active in the second line setting, but toxicity required dose reductions and/or treatment interruptions in 66% of patients.

The safety and efficacy of HDT/SCT in patients with locally advanced, metastatic, or relapsed osteosarcoma has also been evaluated.^{386,387} In the Italian Sarcoma Group study, treatment with carboplatin and etoposide was followed by stem cell rescue, combined with surgery-induced complete response in chemosensitive disease.³⁸⁷ Transplant-related mortality was 3.1%. The 3-year OS and DFS rates were 20% and 12%, respectively. The efficacy of this approach in patients with high-risk disease is yet to be determined in prospective randomized studies.

The optimal treatment strategy for patients with relapsed or refractory disease has yet to be defined. If relapse occurs, the patient should receive second-line chemotherapy and/or surgical resection. Based on the results of the recent phase II trial, the guidelines have included sorafenib as a systemic therapy option for patients with relapsed disease.³⁸⁴ See the *Bone Cancer Systemic Therapy Agents* in the guidelines for a list of other second-line chemotherapy regimens. Surveillance is recommended for patients responding to second-line therapy.

Patients with disease progression or relapse after second-line therapy could be managed with resection, palliative RT, or best supportive care. The guidelines have also included Ra 223 and Sm 153-EDTMP as options for this group of patients. Participation in a clinical trial should be strongly encouraged.

High-grade Undifferentiated Pleomorphic Sarcoma of Bone

High-grade UPS of the bone most frequently arises in the appendicular skeleton and is associated with both a high rate of local recurrence and local nodal and distal metastases.³⁸⁸ The addition of chemotherapy to surgery has been shown to improve clinical outcomes in patients with nonmetastatic malignant fibrous histiocytoma (MFH).³⁸⁹⁻³⁹¹ In the European Osteosarcoma Intergroup study, adjuvant or neoadjuvant chemotherapy with doxorubicin and cisplatin resulted in good pathologic response rates and survivals (quite comparable with those for osteosarcoma) in patients with nonmetastatic MFH.³⁹¹ Median survival time was 63 months, and the 5-year PFS and OS rates were 56% and 59%, respectively. The guidelines recommend that patients with high-grade UPS of bone should be managed with regimens listed for osteosarcoma.

Summary

Primary bone cancers are extremely rare neoplasms. Osteosarcoma, chondrosarcoma, and ESFT are the three most common forms of primary bone cancers. High-grade UPS, chordoma, and GCTB are very rare.

Chondrosarcoma is usually found in middle-aged and older adults. Wide excision is the preferred treatment for resectable low- and high-grade chondrosarcomas. Intralesional excision with or without surgical adjuvant is an alternative option for less radiographically



aggressive, non-pelvic, low-grade chondrosarcomas. Proton and/or photon beam RT may be useful for patients with chondrosarcomas of the skull base and axial skeleton with tumors in unfavorable location not amenable to resection. Chemotherapy has no role in the management of patients with chondrosarcoma, apart from the mesenchymal and dedifferentiated subtypes.

Chordomas arise from the embryonic remnants of the notochord and are more common in older adults. For patients with resectable conventional or chondroid chordomas, wide excision with or without RT is the primary treatment option for chordomas of the sacrum and mobile spine, whereas intralesional excision with or without RT is the treatment of choice for skull base tumors. Adjuvant RT can be considered for large extracompartmental tumors or for positive surgical margins following resection. RT is the primary treatment option for patients with unresectable chordomas, irrespective of the location of the tumor. Systemic therapy (alone or in combination with surgery or RT) is recommended for patients with recurrent tumors. Dedifferentiated chordomas are usually managed as described in the NCCN Guidelines for Soft Tissue Sarcoma.

ESFT develops mainly in children and young adults. *EWS-FLI1* fusion gene resulting from t(11;22) chromosomal translocation is the cytogenetic abnormality in the majority of patients. Multiagent chemotherapy is the primary treatment and patients responding to primary treatment are treated with local control therapy (wide excision, definitive RT with chemotherapy, or amputation in selected cases) followed by adjuvant chemotherapy. Adjuvant chemotherapy following wide excision or amputation is recommended for all patients regardless of surgical margins. Progressive disease is best managed with RT with or without surgery followed by chemotherapy or best supportive care.

GCTB is the most common benign bone tumor predominant in young adults. Intralesional excision with or without an effective adjuvant is an adequate primary treatment for resectable tumors. Serial embolizations, denosumab, interferon, and pegylated interferon are included as primary treatment options for patients with lesions that are resectable with acceptable morbidity or unresectable axial lesions. The guidelines recommend continuation of denosumab until disease progression in responding disease.

Osteosarcoma occurs mainly in children and young adults. Wide excision is the primary treatment for patients with low-grade osteosarcomas, whereas preoperative chemotherapy followed by wide excision is the preferred option for patients with high-grade osteosarcoma. Chemotherapy prior to wide excision can be considered for patients with periosteal lesions. Following wide excision, postoperative chemotherapy is recommended for patients with low-grade or periosteal sarcomas with pathologic findings of high-grade disease and those with high-grade sarcoma. RT followed by adjuvant chemotherapy is recommended if the sarcoma remains unresectable after preoperative chemotherapy. Patients with relapsed or refractory disease should be treated with second-line therapy. Progressive disease is managed with surgery, palliative RT, or best supportive care. Preoperative chemotherapy followed by wide excision of the primary and metastatic tumors is recommended for patients with resectable metastases. Chemotherapy and metastasectomy are included as options for the management of metastatic disease.

Consistent with the NCCN philosophy, the panel encourages patients to participate in well-designed clinical trials to enable further advances.



References

1. SEER Cancer Statistics Fact Sheets: Bone and Joint Cancer. Bethesda, MD: National Cancer Institute; 2014. Available at: <http://seer.cancer.gov/statfacts/html/bones.html>. Accessed July 30, 2014.
2. Siegel RL, Miller KD, Jemal A. Cancer statistics, 2015. *CA Cancer J Clin* 2015;65:5-29. Available at: <http://www.ncbi.nlm.nih.gov/pubmed/25559415>.
3. Fletcher CDM, Bridge JA, Hogendoorn P, Mertens F. WHO Classification of Tumours of Soft Tissue and Bone. Vol. 5 (ed 4). Lyon: IARC Press; 2013.
4. McMaster ML, Goldstein AM, Bromley CM, et al. Chordoma: incidence and survival patterns in the United States, 1973-1995. *Cancer Causes Control* 2001;12:1-11. Available at: <http://www.ncbi.nlm.nih.gov/pubmed/11227920>.
5. Walcott BP, Nahed BV, Mohyeldin A, et al. Chordoma: current concepts, management, and future directions. *The Lancet Oncology* 2012;13:e69-e76. Available at: <http://www.ncbi.nlm.nih.gov/pubmed/22300861>.
6. de Alava E, Gerald WL. Molecular biology of the Ewing's sarcoma/primitive neuroectodermal tumor family. *J Clin Oncol* 2000;18:204-213. Available at: <http://www.ncbi.nlm.nih.gov/pubmed/10623711>.
7. Delattre O, Zucman J, Melot T, et al. The Ewing family of tumors--a subgroup of small-round-cell tumors defined by specific chimeric transcripts. *N Engl J Med* 1994;331:294-299. Available at: <http://www.ncbi.nlm.nih.gov/pubmed/8022439>.
8. Denny CT. Gene rearrangements in Ewing's sarcoma. *Cancer Invest* 1996;14:83-88. Available at: <http://www.ncbi.nlm.nih.gov/pubmed/8597892>.
9. Burchill SA. Molecular abnormalities in Ewing's sarcoma. *Expert Rev Anticancer Ther* 2008;8:1675-1687. Available at: <http://www.ncbi.nlm.nih.gov/pubmed/18925858>.
10. Calvert GT, Randall RL, Jones KB, et al. At-risk populations for osteosarcoma: the syndromes and beyond. *Sarcoma* 2012;2012:152382. Available at: <http://www.ncbi.nlm.nih.gov/pubmed/22550413>.
11. Martin JW, Squire JA, Zielenska M. The genetics of osteosarcoma. *Sarcoma* 2012;2012:627254. Available at: <http://www.ncbi.nlm.nih.gov/pubmed/22685381>.
12. Malkin D, Li FP, Strong LC, et al. Germ line p53 mutations in a familial syndrome of breast cancer, sarcomas, and other neoplasms. *Science* 1990;250:1233-1238. Available at: <http://www.ncbi.nlm.nih.gov/pubmed/1978757>.
13. McIntyre JF, Smith-Sorensen B, Friend SH, et al. Germline mutations of the p53 tumor suppressor gene in children with osteosarcoma. *J Clin Oncol* 1994;12:925-930. Available at: <http://www.ncbi.nlm.nih.gov/pubmed/8164043>.
14. Ognjanovic S, Olivier M, Bergemann TL, Hainaut P. Sarcomas in TP53 germline mutation carriers: a review of the IARC TP53 database. *Cancer* 2012;118:1387-1396. Available at: <http://www.ncbi.nlm.nih.gov/pubmed/21837677>.
15. Ottaviani G, Jaffe N. The etiology of osteosarcoma. *Cancer Treat Res* 2009;152:15-32. Available at: <http://www.ncbi.nlm.nih.gov/pubmed/20213384>.
16. MacCarthy A, Bayne AM, Draper GJ, et al. Non-ocular tumours following retinoblastoma in Great Britain 1951 to 2004. *Br J Ophthalmol* 2009;93:1159-1162. Available at: <http://www.ncbi.nlm.nih.gov/pubmed/19704040>.



17. Kalra S, Grimer RJ, Spooner D, et al. Radiation-induced sarcomas of bone: factors that affect outcome. *J Bone Joint Surg Br* 2007;89:808-813. Available at: <http://www.ncbi.nlm.nih.gov/pubmed/17613509>.
18. Mavrogenis AF, Pala E, Guerra G, Ruggieri P. Post-radiation sarcomas. Clinical outcome of 52 Patients. *J Surg Oncol* 2012;105:570-576. Available at: <http://www.ncbi.nlm.nih.gov/pubmed/22012601>.
19. Bernstein M, Kovar H, Paulussen M, et al. Ewing's sarcoma family of tumors: current management. *Oncologist* 2006;11:503-519. Available at: <http://www.ncbi.nlm.nih.gov/pubmed/16720851>.
20. Subbiah V, Anderson P, Lazar AJ, et al. Ewing's sarcoma: standard and experimental treatment options. *Curr Treat Options Oncol* 2009;10:126-140. Available at: <http://www.ncbi.nlm.nih.gov/pubmed/19533369>.
21. Federman N, Bernthal N, Eilber FC, Tap WD. The multidisciplinary management of osteosarcoma. *Curr Treat Options Oncol* 2009;10:82-93. Available at: <http://www.ncbi.nlm.nih.gov/pubmed/19238553>.
22. Cotterill SJ, Ahrens S, Paulussen M, et al. Prognostic factors in Ewing's tumor of bone: analysis of 975 patients from the European Intergroup Cooperative Ewing's Sarcoma Study Group. *J Clin Oncol* 2000;18:3108-3114. Available at: <http://www.ncbi.nlm.nih.gov/pubmed/10963639>.
23. Kager L, Zoubek A, Potechger U, et al. Primary metastatic osteosarcoma: presentation and outcome of patients treated on neoadjuvant Cooperative Osteosarcoma Study Group protocols. *J Clin Oncol* 2003;21:2011-2018. Available at: <http://www.ncbi.nlm.nih.gov/pubmed/12743156>.
24. Edge SB, Byrd DR, Compton CC, et al. American Joint Committee on Cancer (AJCC) Cancer Staging Manual (ed 7th); 2010.
25. Enneking WF, Spanier SS, Goodman MA. A system for the surgical staging of musculoskeletal sarcoma. *Clin Orthop Relat Res* 1980;106-120. Available at: <http://www.ncbi.nlm.nih.gov/pubmed/7449206>.
26. Lee SJ, Schover LR, Partridge AH, et al. American Society of Clinical Oncology recommendations on fertility preservation in cancer patients. *J Clin Oncol* 2006;24:2917-2931. Available at: <http://www.ncbi.nlm.nih.gov/pubmed/16651642>.
27. Rougraff BT, Kneisl JS, Simon MA. Skeletal metastases of unknown origin. A prospective study of a diagnostic strategy. *J Bone Joint Surg Am* 1993;75:1276-1281. Available at: <http://www.ncbi.nlm.nih.gov/pubmed/8408149>.
28. Heck RK, Peabody TD, Simon MA. Staging of primary malignancies of bone. *CA Cancer J Clin* 2006;56:366-375. Available at: <http://www.ncbi.nlm.nih.gov/pubmed/17135693>.
29. Kumar J, Seith A, Kumar A, et al. Whole-body MR imaging with the use of parallel imaging for detection of skeletal metastases in pediatric patients with small-cell neoplasms: comparison with skeletal scintigraphy and FDG PET/CT. *Pediatr Radiol* 2008;38:953-962. Available at: <http://www.ncbi.nlm.nih.gov/pubmed/18636251>.
30. Daldrup-Link HE, Franzius C, Link TM, et al. Whole-body MR imaging for detection of bone metastases in children and young adults: comparison with skeletal scintigraphy and FDG PET. *AJR Am J Roentgenol* 2001;177:229-236. Available at: <http://www.ncbi.nlm.nih.gov/pubmed/11418435>.
31. Schuetze SM. Utility of positron emission tomography in sarcomas. *Curr Opin Oncol* 2006;18:369-373. Available at: <http://www.ncbi.nlm.nih.gov/pubmed/16721133>.
32. Volker T, Denecke T, Steffen I, et al. Positron emission tomography for staging of pediatric sarcoma patients: results of a prospective multicenter trial. *J Clin Oncol* 2007;25:5435-5441. Available at: <http://www.ncbi.nlm.nih.gov/pubmed/18048826>.



33. Hawkins DS, Rajendran JG, Conrad EU, et al. Evaluation of chemotherapy response in pediatric bone sarcomas by [F-18]-fluorodeoxy-D-glucose positron emission tomography. *Cancer* 2002;94:3277-3284. Available at: <http://www.ncbi.nlm.nih.gov/pubmed/12115361>.

34. Hawkins DS, Schuetze SM, Butrynski JE, et al. [18F]Fluorodeoxyglucose positron emission tomography predicts outcome for Ewing sarcoma family of tumors. *J Clin Oncol* 2005;23:8828-8834. Available at: <http://www.ncbi.nlm.nih.gov/pubmed/16314643>.

35. Hawkins DS, Conrad EU, 3rd, Butrynski JE, et al. [F-18]-fluorodeoxy-D-glucose-positron emission tomography response is associated with outcome for extremity osteosarcoma in children and young adults. *Cancer* 2009;115:3519-3525. Available at: <http://www.ncbi.nlm.nih.gov/pubmed/19517457>.

36. Stacchiotti S, Longhi A, Ferraresi V, et al. Phase II study of imatinib in advanced chordoma. *J Clin Oncol* 2012;30:914-920. Available at: <http://www.ncbi.nlm.nih.gov/pubmed/22331945>.

37. Mammari H, Kerrou K, Nataf V, et al. Positron emission tomography/computed tomography imaging of residual skull base chordoma before radiotherapy using fluoromisonidazole and fluorodeoxyglucose: potential consequences for dose painting. *Int J Radiat Oncol Biol Phys* 2012;84:681-687. Available at: <http://www.ncbi.nlm.nih.gov/pubmed/22391104>.

38. Liu PT, Valadez SD, Chivers FS, et al. Anatomically based guidelines for core needle biopsy of bone tumors: implications for limb-sparing surgery. *Radiographics* 2007;27:189-205; discussion 206. Available at: <http://www.ncbi.nlm.nih.gov/pubmed/17235007>.

39. Huang AJ, Kattapuram SV. Musculoskeletal neoplasms: biopsy and intervention. *Radiol Clin North Am* 2011;49:1287-1305. Available at: <http://www.ncbi.nlm.nih.gov/pubmed/22024299>.

40. Ashford RU, McCarthy SW, Scolyer RA, et al. Surgical biopsy with intra-operative frozen section. An accurate and cost-effective method for diagnosis of musculoskeletal sarcomas. *J Bone Joint Surg Br* 2006;88:1207-1211. Available at: <http://www.ncbi.nlm.nih.gov/pubmed/16943474>.

41. Skrzynski MC, Biermann JS, Montag A, Simon MA. Diagnostic accuracy and charge-savings of outpatient core needle biopsy compared with open biopsy of musculoskeletal tumors. *J Bone Joint Surg Am* 1996;78:644-649. Available at: <http://www.ncbi.nlm.nih.gov/pubmed/8642019>

42. Welker JA, Henshaw RM, Jelinek J, et al. The percutaneous needle biopsy is safe and recommended in the diagnosis of musculoskeletal masses. *Cancer* 2000;89:2677-2686. Available at: <http://www.ncbi.nlm.nih.gov/pubmed/11135231>

43. Mitsuyoshi G, Naito N, Kawai A, et al. Accurate diagnosis of musculoskeletal lesions by core needle biopsy. *J Surg Oncol* 2006;94:21-27. Available at: <http://www.ncbi.nlm.nih.gov/pubmed/16788939>.

44. Adams SC, Potter BK, Pitcher DJ, Temple HT. Office-based core needle biopsy of bone and soft tissue malignancies: an accurate alternative to open biopsy with infrequent complications. *Clin Orthop Relat Res* 2010;468:2774-2780. Available at: <http://www.ncbi.nlm.nih.gov/pubmed/20582496>.

45. Gogna A, Peh WC, Munk PL. Image-guided musculoskeletal biopsy. *Radiol Clin North Am* 2008;46:455-473, v. Available at: <http://www.ncbi.nlm.nih.gov/pubmed/18707957>.

46. Mankin HJ, Mankin CJ, Simon MA. The hazards of the biopsy, revisited. Members of the Musculoskeletal Tumor Society. *J Bone Joint Surg Am* 1996;78:656-663. Available at: <http://www.ncbi.nlm.nih.gov/pubmed/8642021>.

47. Davies NM, Livesley PJ, Cannon SR. Recurrence of an osteosarcoma in a needle biopsy track. *J Bone Joint Surg Br* 1993;75:977-978. Available at: <http://www.ncbi.nlm.nih.gov/pubmed/8245097>.
48. Saghieh S, Masrouha KZ, Musallam KM, et al. The risk of local recurrence along the core-needle biopsy tract in patients with bone sarcomas. *Iowa Orthop J* 2010;30:80-83. Available at: <http://www.ncbi.nlm.nih.gov/pubmed/21045976>.
49. Yang YJ, Damron TA. Comparison of needle core biopsy and fine-needle aspiration for diagnostic accuracy in musculoskeletal lesions. *Arch Pathol Lab Med* 2004;128:759-764. Available at: <http://www.ncbi.nlm.nih.gov/pubmed/15214827>.
50. Patel S, DeLaney TF. Advanced-technology radiation therapy for bone sarcomas. *Cancer Control* 2008;15:21-37. Available at: <http://www.ncbi.nlm.nih.gov/pubmed/18094658>.
51. McGovern SL, Mahajan A. Progress in radiotherapy for pediatric sarcomas. *Curr Oncol Rep* 2012;14:320-326. Available at: <http://www.ncbi.nlm.nih.gov/pubmed/22532264>.
52. Gelderblom H, Hogendoorn PCW, Dijkstra SD, et al. The clinical approach towards chondrosarcoma. *Oncologist* 2008;13:320-329. Available at: <http://www.ncbi.nlm.nih.gov/pubmed/18378543>.
53. Riedel RF, Larrier N, Dodd L, et al. The clinical management of chondrosarcoma. *Curr Treat Options Oncol* 2009;10:94-106. Available at: <http://www.ncbi.nlm.nih.gov/pubmed/19238552>.
54. Mankin HJ, Cantley KP, Schiller AL, Lippello L. The biology of human chondrosarcoma. II. Variation in chemical composition among types and subtypes of benign and malignant cartilage tumors. *J Bone Joint Surg Am* 1980;62:176-188. Available at: <http://www.ncbi.nlm.nih.gov/pubmed/7358749>.
55. Verdegaal SH, Bovee JV, Pansuriya TC, et al. Incidence, predictive factors, and prognosis of chondrosarcoma in patients with Ollier disease and Maffucci syndrome: an international multicenter study of 161 patients. *Oncologist* 2011;16:1771-1779. Available at: <http://www.ncbi.nlm.nih.gov/pubmed/22147000>.
56. Ahmed AR, Tan T-S, Unni KK, et al. Secondary chondrosarcoma in osteochondroma: report of 107 patients. *Clin Orthop Relat Res* 2003:193-206. Available at: <http://www.ncbi.nlm.nih.gov/pubmed/12782876>.
57. Amary MF, Damato S, Halai D, et al. Ollier disease and Maffucci syndrome are caused by somatic mosaic mutations of IDH1 and IDH2. *Nat Genet* 2011;43:1262-1265. Available at: <http://www.ncbi.nlm.nih.gov/pubmed/22057236>.
58. Pansuriya TC, van Eijk R, d'Adamo P, et al. Somatic mosaic IDH1 and IDH2 mutations are associated with enchondroma and spindle cell hemangioma in Ollier disease and Maffucci syndrome. *Nat Genet* 2011;43:1256-1261. Available at: <http://www.ncbi.nlm.nih.gov/pubmed/22057234>.
59. Amary MF, Bacsi K, Maggiani F, et al. IDH1 and IDH2 mutations are frequent events in central chondrosarcoma and central and periosteal chondromas but not in other mesenchymal tumours. *J Pathol* 2011;224:334-343. Available at: <http://www.ncbi.nlm.nih.gov/pubmed/21598255>.
60. Meijer D, de Jong D, Pansuriya TC, et al. Genetic characterization of mesenchymal, clear cell, and dedifferentiated chondrosarcoma. *Genes Chromosomes Cancer* 2012;51:899-909. Available at: <http://www.ncbi.nlm.nih.gov/pubmed/22674453>.
61. Kilpatrick SE, Inwards CY, Fletcher CD, et al. Myxoid chondrosarcoma (chordoid sarcoma) of bone: a report of two cases and review of the literature. *Cancer* 1997;79:1903-1910. Available at: <http://www.ncbi.nlm.nih.gov/pubmed/9149016>.

62. Antonescu CR, Argani P, Erlandson RA, et al. Skeletal and extraskeletal myxoid chondrosarcoma: a comparative clinicopathologic, ultrastructural, and molecular study. *Cancer* 1998;83:1504-1521. Available at: <http://www.ncbi.nlm.nih.gov/pubmed/9781944>.
63. Hirabayashi Y, Ishida T, Yoshida MA, et al. Translocation (9;22)(q22;q12). A recurrent chromosome abnormality in extraskeletal myxoid chondrosarcoma. *Cancer Genet Cytogenet* 1995;81:33-37. Available at: <http://www.ncbi.nlm.nih.gov/pubmed/7773957>.
64. Panagopoulos I, Mertens F, Isaksson M, et al. Molecular genetic characterization of the EWS/CHN and RBP56/CHN fusion genes in extraskeletal myxoid chondrosarcoma. *Genes Chromosomes Cancer* 2002;35:340-352. Available at: <http://www.ncbi.nlm.nih.gov/pubmed/12378528>.
65. Nishio J, Iwasaki H, Nabeshima K, Naito M. Cytogenetics and molecular genetics of myxoid soft-tissue sarcomas. *Genet Res Int* 2011;2011:497148. Available at: <http://www.ncbi.nlm.nih.gov/pubmed/22567356>.
66. Paioli A, Gronchi A, Palmerini E, et al. Extraskeletal myxoid chondrosarcoma: A retrospective analysis of 69 patients with localized disease and molecularly confirmed diagnosis [abstract]. *ASCO Meeting Abstracts* 2014;32:10589. Available at: http://meeting.ascopubs.org/cgi/content/abstract/32/15_suppl/10589.
67. Bruns J, Elbracht M, Niggemeyer O. Chondrosarcoma of bone: an oncological and functional follow-up study. *Ann Oncol* 2001;12:859-864. Available at: <http://www.ncbi.nlm.nih.gov/pubmed/11484965>.
68. Bergh P, Gunterberg B, Meis-Kindblom JM, Kindblom LG. Prognostic factors and outcome of pelvic, sacral, and spinal chondrosarcomas: a center-based study of 69 cases. *Cancer* 2001;91:1201-1212. Available at: <http://www.ncbi.nlm.nih.gov/pubmed/11283918>.
69. Enneking WF, Dunham WK. Resection and reconstruction for primary neoplasms involving the innominate bone. *J Bone Joint Surg Am* 1978;60:731-746. Available at: <http://www.ncbi.nlm.nih.gov/pubmed/701308>.
70. Norman A, Sissons HA. Radiographic hallmarks of peripheral chondrosarcoma. *Radiology* 1984;151:589-596. Available at: <http://www.ncbi.nlm.nih.gov/pubmed/6718712>.
71. Sanerkin NG. The diagnosis and grading of chondrosarcoma of bone: a combined cytologic and histologic approach. *Cancer* 1980;45:582-594. Available at: <http://www.ncbi.nlm.nih.gov/pubmed/6928110>.
72. Lee FY, Mankin HJ, Fondren G, et al. Chondrosarcoma of bone: an assessment of outcome. *J Bone Joint Surg Am* 1999;81:326-338. Available at: <http://www.ncbi.nlm.nih.gov/pubmed/10199270>.
73. Fiorenza F, Abudu A, Grimer RJ, et al. Risk factors for survival and local control in chondrosarcoma of bone. *J Bone Joint Surg Br* 2002;84:93-99. Available at: <http://www.ncbi.nlm.nih.gov/pubmed/11837841>.
74. Giuffrida AY, Burgueno JE, Koniaris LG, et al. Chondrosarcoma in the United States (1973 to 2003): an analysis of 2890 cases from the SEER database. *J Bone Joint Surg Am* 2009;91:1063-1072. Available at: <http://www.ncbi.nlm.nih.gov/pubmed/19411454>.
75. Sheth DS, Yasko AW, Johnson ME, et al. Chondrosarcoma of the pelvis. Prognostic factors for 67 patients treated with definitive surgery. *Cancer* 1996;78:745-750. Available at: <http://www.ncbi.nlm.nih.gov/pubmed/8756367>.
76. Pring ME, Weber KL, Unni KK, Sim FH. Chondrosarcoma of the pelvis. A review of sixty-four cases. *J Bone Joint Surg Am* 2001;83-A:1630-1642. Available at: <http://www.ncbi.nlm.nih.gov/pubmed/11701784>.



77. Funovics PT, Panotopoulos J, Sabeti-Aschraf M, et al. Low-grade chondrosarcoma of bone: experiences from the Vienna Bone and Soft Tissue Tumour Registry. *Int Orthop* 2011;35:1049-1056. Available at: <http://www.ncbi.nlm.nih.gov/pubmed/20803012>.
78. Andreou D, Ruppin S, Fehlberg S, et al. Survival and prognostic factors in chondrosarcoma. *Acta Orthop* 2011;82:749-755. Available at: <http://www.ncbi.nlm.nih.gov/pubmed/22066552>.
79. Veth R, Schreuder B, van Beem H, et al. Cryosurgery in aggressive, benign, and low-grade malignant bone tumours. *Lancet Oncol* 2005;6:25-34. Available at: <http://www.ncbi.nlm.nih.gov/pubmed/15629273>.
80. Ahlmann ER, Menendez LR, Fedenko AN, Learch T. Influence of cryosurgery on treatment outcome of low-grade chondrosarcoma. *Clin Orthop Relat Res* 2006;451:201-207. Available at: <http://www.ncbi.nlm.nih.gov/pubmed/16788412>.
81. Mohler DG, Chiu R, McCall DA, Avedian RS. Curettage and cryosurgery for low-grade cartilage tumors is associated with low recurrence and high function. *Clin Orthop Relat Res* 2010;468:2765-2773. Available at: <http://www.ncbi.nlm.nih.gov/pubmed/20574801>.
82. Leerapun T, Hugate RR, Inwards CY, et al. Surgical management of conventional grade I chondrosarcoma of long bones. *Clin Orthop Relat Res* 2007;463:166-172. Available at: <http://www.ncbi.nlm.nih.gov/pubmed/17632422>.
83. Donati D, Colangeli S, Colangeli M, et al. Surgical treatment of grade I central chondrosarcoma. *Clin Orthop Relat Res* 2010;468:581-589. Available at: <http://www.ncbi.nlm.nih.gov/pubmed/19727994>.
84. Hickey M, Farrokhyar F, Deheshi B, et al. A systematic review and meta-analysis of intralesional versus wide resection for intramedullary grade I chondrosarcoma of the extremities. *Ann Surg Oncol* 2011;18:1705-1709. Available at: <http://www.ncbi.nlm.nih.gov/pubmed/21258968>.
85. Goda JS, Ferguson PC, O'Sullivan B, et al. High-risk extracranial chondrosarcoma. *Cancer* 2011;117:2513-2519. Available at: <http://www.ncbi.nlm.nih.gov/pubmed/21246520>.
86. Kawaguchi S, Weiss I, Lin PP, et al. Radiation therapy is associated with fewer recurrences in mesenchymal chondrosarcoma. *Clin Orthop Relat Res* 2014;472:856-864. Available at: <http://www.ncbi.nlm.nih.gov/pubmed/23709273>.
87. Hug EB, Loredó LN, Slater JD, et al. Proton radiation therapy for chordomas and chondrosarcomas of the skull base. *J Neurosurg* 1999;91:432-439. Available at: <http://www.ncbi.nlm.nih.gov/pubmed/10470818>.
88. Munzenrider JE, Liebsch NJ. Proton therapy for tumors of the skull base. *Strahlenther Onkol* 1999;175 Suppl 2:57-63. Available at: <http://www.ncbi.nlm.nih.gov/pubmed/10394399>.
89. Noel G, Habrand JL, Mammari H, et al. Combination of photon and proton radiation therapy for chordomas and chondrosarcomas of the skull base: the Centre de Protontherapie D'Orsay experience. *Int J Radiat Oncol Biol Phys* 2001;51:392-398. Available at: <http://www.ncbi.nlm.nih.gov/pubmed/11567813>.
90. Noel G, Feuvret L, Ferrand R, et al. Radiotherapeutic factors in the management of cervical-basal chordomas and chondrosarcomas. *Neurosurgery* 2004;55:1252-1260. Available at: <http://www.ncbi.nlm.nih.gov/pubmed/15574207>.
91. Ares C, Hug EB, Lomax AJ, et al. Effectiveness and safety of spot scanning proton radiation therapy for chordomas and chondrosarcomas of the skull base: first long-term report. *Int J Radiat Oncol Biol Phys* 2009;75:1111-1118. Available at: <http://www.ncbi.nlm.nih.gov/pubmed/19386442>.
92. Amichetti M, Amelio D, Cianchetti M, et al. A systematic review of proton therapy in the treatment of chondrosarcoma of the skull base.



Neurosurg Rev 2010;33:155-165. Available at:
<http://www.ncbi.nlm.nih.gov/pubmed/19921291>.

93. DeLaney TF, Liebsch NJ, Pedlow FX, et al. Long-term results of Phase II study of high dose photon/proton radiotherapy in the management of spine chordomas, chondrosarcomas, and other sarcomas. J Surg Oncol 2014;110:115-122. Available at:
<http://www.ncbi.nlm.nih.gov/pubmed/24752878>.

94. Schulz-Ertner D, Nikoghosyan A, Thilmann C, et al. Results of carbon ion radiotherapy in 152 patients. Int J Radiat Oncol Biol Phys 2004;58:631-640. Available at:
<http://www.ncbi.nlm.nih.gov/pubmed/14751537>.

95. Schulz-Ertner D, Nikoghosyan A, Hof H, et al. Carbon ion radiotherapy of skull base chondrosarcomas. Int J Radiat Oncol Biol Phys 2007;67:171-177. Available at:
<http://www.ncbi.nlm.nih.gov/pubmed/17056193>.

96. Uhl M, Mattke M, Welzel T, et al. High control rate in patients with chondrosarcoma of the skull base after carbon ion therapy: First report of long-term results. Cancer 2014;120:1579-1585. Available at:
<http://www.ncbi.nlm.nih.gov/pubmed/24500784>.

97. Mitchell AD, Ayoub K, Mangham DC, et al. Experience in the treatment of dedifferentiated chondrosarcoma. J Bone Joint Surg Br 2000;82:55-61. Available at:
<http://www.ncbi.nlm.nih.gov/pubmed/10697315>.

98. Dickey ID, Rose PS, Fuchs B, et al. Dedifferentiated chondrosarcoma: the role of chemotherapy with updated outcomes. J Bone Joint Surg Am 2004;86-A:2412-2418. Available at:
<http://www.ncbi.nlm.nih.gov/pubmed/15523011>.

99. Grimer RJ, Gosheger G, Taminiau A, et al. Dedifferentiated chondrosarcoma: prognostic factors and outcome from a European group. Eur J Cancer 2007;43:2060-2065. Available at:
<http://www.ncbi.nlm.nih.gov/pubmed/17720491>.

100. Staals EL, Bacchini P, Bertoni F. Dedifferentiated central chondrosarcoma. Cancer 2006;106:2682-2691. Available at:
<http://www.ncbi.nlm.nih.gov/pubmed/16691621>.

101. Frezza AM, Cesari M, Baumhoer D, et al. Mesenchymal chondrosarcoma: prognostic factors and outcome in 113 patients. A European Musculoskeletal Oncology Society study. Eur J Cancer 2015;51:374-381. Available at:
<http://www.ncbi.nlm.nih.gov/pubmed/25529371>.

102. Dantonello TM, Int-Veen C, Leuschner I, et al. Mesenchymal chondrosarcoma of soft tissues and bone in children, adolescents, and young adults: experiences of the CWS and COSS study groups. Cancer 2008;112:2424-2431. Available at:
<http://www.ncbi.nlm.nih.gov/pubmed/18438777>.

103. Uhl M, Welzel T, Oelmann J, et al. Active raster scanning with carbon ions: reirradiation in patients with recurrent skull base chordomas and chondrosarcomas. Strahlenther Onkol 2014;190:686-691. Available at: <http://www.ncbi.nlm.nih.gov/pubmed/24663287>.

104. Bernstein-Molho R, Kollender Y, Issakov J, et al. Clinical activity of mTOR inhibition in combination with cyclophosphamide in the treatment of recurrent unresectable chondrosarcomas. Cancer Chemother Pharmacol 2012;70:855-860. Available at:
<http://www.ncbi.nlm.nih.gov/pubmed/23053256>.

105. Chugh R, Tawbi H, Lucas DR, et al. Chordoma: the nonsarcoma primary bone tumor. Oncologist 2007;12:1344-1350. Available at:
<http://www.ncbi.nlm.nih.gov/pubmed/18055855>.

106. Rachinger W, Eigenbrod S, Dutzmann S, et al. Male sex as a risk factor for the clinical course of skull base chordomas. J Neurosurg 2014;120:1313-1320. Available at:
<http://www.ncbi.nlm.nih.gov/pubmed/24405075>.

107. Yamaguchi T, Suzuki S, Ishiwa H, Ueda Y. Intraosseous benign notochordal cell tumours: overlooked precursors of classic chordomas?



Histopathology 2004;44:597-602. Available at:
<http://www.ncbi.nlm.nih.gov/pubmed/15186275>.

108. Deshpande V, Nielsen GP, Rosenthal DI, Rosenberg AE. Intraosseous benign notochord cell tumors (BNCT): further evidence supporting a relationship to chordoma. *Am J Surg Pathol* 2007;31:1573-1577. Available at: <http://www.ncbi.nlm.nih.gov/pubmed/17895760>.

109. Yamaguchi T, Iwata J, Sugihara S, et al. Distinguishing benign notochordal cell tumors from vertebral chordoma. *Skeletal Radiol* 2008;37:291-299. Available at: <http://www.ncbi.nlm.nih.gov/pubmed/18188556>.

110. Nishiguchi T, Mochizuki K, Ohsawa M, et al. Differentiating benign notochordal cell tumors from chordomas: radiographic features on MRI, CT, and tomography. *AJR Am J Roentgenol* 2011;196:644-650. Available at: <http://www.ncbi.nlm.nih.gov/pubmed/21343509>.

111. Meyers SP, Hirsch WL, Jr., Curtin HD, et al. Chordomas of the skull base: MR features. *AJNR Am J Neuroradiol* 1992;13:1627-1636. Available at: <http://www.ncbi.nlm.nih.gov/pubmed/1442442>.

112. Weber AL, Liebsch NJ, Sanchez R, Sweriduk ST, Jr. Chordomas of the skull base. Radiologic and clinical evaluation. *Neuroimaging Clin N Am* 1994;4:515-527. Available at: <http://www.ncbi.nlm.nih.gov/pubmed/7952953>.

113. Rosenthal DI, Scott JA, Mankin HJ, et al. Sacrococcygeal chordoma: magnetic resonance imaging and computed tomography. *AJR Am J Roentgenol* 1985;145:143-147. Available at: <http://www.ncbi.nlm.nih.gov/pubmed/3873835>.

114. Plathow C, Weber MA, Debus J, Kauczor HU. [Imaging of sacral chordoma: comparison between MRI and CT]. *Radiologe* 2005;45:63-68. Available at: <http://www.ncbi.nlm.nih.gov/pubmed/15662521>.

115. Sung MS, Lee GK, Kang HS, et al. Sacrococcygeal chordoma: MR imaging in 30 patients. *Skeletal Radiol* 2005;34:87-94. Available at: <http://www.ncbi.nlm.nih.gov/pubmed/15480648>.

116. Meyer JE, Lepke RA, Lindfors KK, et al. Chordomas: their CT appearance in the cervical, thoracic and lumbar spine. *Radiology* 1984;153:693-696. Available at: <http://www.ncbi.nlm.nih.gov/pubmed/6494465>.

117. Ducou le Pointe H, Brugieres P, Chevalier X, et al. Imaging of chordomas of the mobile spine. *J Neuroradiol* 1991;18:267-276. Available at: <http://www.ncbi.nlm.nih.gov/pubmed/1765812>.

118. Ferraresi V, Nuzzo C, Zoccali C, et al. Chordoma: clinical characteristics, management and prognosis of a case series of 25 patients. *BMC Cancer* 2010;10:22-22. Available at: <http://www.ncbi.nlm.nih.gov/pubmed/20109225>.

119. Jawad MU, Scully SP. Surgery significantly improves survival in patients with chordoma. *Spine (Phila Pa 1976)* 2010;35:117-123. Available at: <http://www.ncbi.nlm.nih.gov/pubmed/20042964>.

120. Fuchs B, Dickey ID, Yaszemski MJ, et al. Operative management of sacral chordoma. *J Bone Joint Surg Am* 2005;87:2211-2216. Available at: <http://www.ncbi.nlm.nih.gov/pubmed/16203885>.

121. Ruggieri P, Mavrogenis AF, Ussia G, et al. Recurrence after and complications associated with adjuvant treatments for sacral giant cell tumor. *Clin Orthop Relat Res* 2010;468:2954-2961. Available at: <http://www.ncbi.nlm.nih.gov/pubmed/20623262>.

122. Stacchiotti S, Casali PG, Lo Vullo S, et al. Chordoma of the mobile spine and sacrum: a retrospective analysis of a series of patients surgically treated at two referral centers. *Ann Surg Oncol* 2010;17:211-219. Available at: <http://www.ncbi.nlm.nih.gov/pubmed/19847568>.

123. Forsyth PA, Cascino TL, Shaw EG, et al. Intracranial chordomas: a clinicopathological and prognostic study of 51 cases. *J Neurosurg*

1993;78:741-747. Available at:

<http://www.ncbi.nlm.nih.gov/pubmed/8468605>.

124. Tzortzidis F, Elahi F, Wright D, et al. Patient outcome at long-term follow-up after aggressive microsurgical resection of cranial base chordomas. *Neurosurgery* 2006;59:230-237. Available at:

<http://www.ncbi.nlm.nih.gov/pubmed/16883163>.

125. Sen C, Triana AI, Berglind N, et al. Clival chordomas: clinical management, results, and complications in 71 patients. *J Neurosurg* 2010;113:1059-1071. Available at:

<http://www.ncbi.nlm.nih.gov/pubmed/19929198>.

126. Wu Z, Zhang J, Zhang L, et al. Prognostic factors for long-term outcome of patients with surgical resection of skull base chordomas-106 cases review in one institution. *Neurosurg Rev* 2010;33:451-456. Available at:

<http://www.ncbi.nlm.nih.gov/pubmed/20668904>.

127. Di Maio S, Temkin N, Ramanathan D, Sekhar LN. Current comprehensive management of cranial base chordomas: 10-year meta-analysis of observational studies. *J Neurosurg* 2011;115:1094-1105. Available at:

<http://www.ncbi.nlm.nih.gov/pubmed/21819197>.

128. Di Maio S, Rostomily R, Sekhar LN. Current surgical outcomes for cranial base chordomas: cohort study of 95 patients. *Neurosurgery* 2012;70:1355-1360. Available at:

<http://www.ncbi.nlm.nih.gov/pubmed/22157545>.

129. Boriani S, Bandiera S, Biagini R, et al. Chordoma of the mobile spine: fifty years of experience. *Spine (Phila Pa 1976)* 2006;31:493-503. Available at:

<http://www.ncbi.nlm.nih.gov/pubmed/16481964>.

130. Catton C, O'Sullivan B, Bell R, et al. Chordoma: long-term follow-up after radical photon irradiation. *Radiother Oncol* 1996;41:67-72. Available at:

<http://www.ncbi.nlm.nih.gov/pubmed/8961370>.

131. Foweraker KL, Burton KE, Maynard SE, et al. High-dose radiotherapy in the management of chordoma and chondrosarcoma of

the skull base and cervical spine: Part 1--Clinical outcomes. *Clin Oncol (R Coll Radiol)* 2007;19:509-516. Available at:

<http://www.ncbi.nlm.nih.gov/pubmed/17524633>.

132. Wagner TD, Kobayashi W, Dean S, et al. Combination short-course preoperative irradiation, surgical resection, and reduced-field high-dose postoperative irradiation in the treatment of tumors involving the bone. *Int J Radiat Oncol Biol Phys* 2009;73:259-266. Available at:

<http://www.ncbi.nlm.nih.gov/pubmed/19100921>.

133. Jian BJ, Bloch OG, Yang I, et al. Adjuvant radiation therapy and chondroid chordoma subtype are associated with a lower tumor recurrence rate of cranial chordoma. *J Neurooncol* 2010;98:101-108. Available at:

<http://www.ncbi.nlm.nih.gov/pubmed/19953297>.

134. Moojen WA, Vleggeert-Lankamp CL, Krol AD, Dijkstra SP. Long-term results: adjuvant radiotherapy in en bloc resection of sacrococcygeal chordoma is advisable. *Spine (Phila Pa 1976)* 2011;36:E656-661. Available at:

<http://www.ncbi.nlm.nih.gov/pubmed/21217422>.

135. Potluri S, Jefferies SJ, Jena R, et al. Residual postoperative tumour volume predicts outcome after high-dose radiotherapy for chordoma and chondrosarcoma of the skull base and spine. *Clin Oncol (R Coll Radiol)* 2011;23:199-208. Available at:

<http://www.ncbi.nlm.nih.gov/pubmed/20980136>.

136. Fagundes MA, Hug EB, Liebsch NJ, et al. Radiation therapy for chordomas of the base of skull and cervical spine: patterns of failure and outcome after relapse. *Int J Radiat Oncol Biol Phys* 1995;33:579-584. Available at:

<http://www.ncbi.nlm.nih.gov/pubmed/7558946>.

137. Noel G, Feuvret L, Calugaru V, et al. Chordomas of the base of the skull and upper cervical spine. One hundred patients irradiated by a 3D conformal technique combining photon and proton beams. *Acta Oncol* 2005;44:700-708. Available at:

<http://www.ncbi.nlm.nih.gov/pubmed/16227160>.



138. Park L, Delaney TF, Liebsch NJ, et al. Sacral chordomas: Impact of high-dose proton/photon-beam radiation therapy combined with or without surgery for primary versus recurrent tumor. *Int J Radiat Oncol Biol Phys* 2006;65:1514-1521. Available at: <http://www.ncbi.nlm.nih.gov/pubmed/16757128>.

139. Amichetti M, Cianchetti M, Amelio D, et al. Proton therapy in chordoma of the base of the skull: a systematic review. *Neurosurg Rev* 2009;32:403-416. Available at: <http://www.ncbi.nlm.nih.gov/pubmed/19319583>.

140. Staab A, Rutz HP, Ares C, et al. Spot-scanning-based proton therapy for extracranial chordoma. *Int J Radiat Oncol Biol Phys* 2011;81:489-496. Available at: <http://www.ncbi.nlm.nih.gov/pubmed/21497457>.

141. Yasuda M, Bresson D, Chibbaro S, et al. Chordomas of the skull base and cervical spine: clinical outcomes associated with a multimodal surgical resection combined with proton-beam radiation in 40 patients. *Neurosurg Rev* 2012;35:171-182. Available at: <http://www.ncbi.nlm.nih.gov/pubmed/21863225>.

142. Rutz HP, Weber DC, Sugahara S, et al. Extracranial chordoma: Outcome in patients treated with function-preserving surgery followed by spot-scanning proton beam irradiation. *Int J Radiat Oncol Biol Phys* 2007;67:512-520. Available at: <http://www.ncbi.nlm.nih.gov/pubmed/17084540>.

143. Schulz-Ertner D, Karger CP, Feuerhake A, et al. Effectiveness of carbon ion radiotherapy in the treatment of skull-base chordomas. *Int J Radiat Oncol Biol Phys* 2007;68:449-457. Available at: <http://www.ncbi.nlm.nih.gov/pubmed/17363188>.

144. Takahashi S, Kawase T, Yoshida K, et al. Skull base chordomas: efficacy of surgery followed by carbon ion radiotherapy. *Acta Neurochir (Wien)* 2009;151:759-769. Available at: <http://www.ncbi.nlm.nih.gov/pubmed/19434365>.

145. Imai R, Kamada T, Sugahara S, et al. Carbon ion radiotherapy for sacral chordoma. *Br J Radiol* 2011;84 Spec No 1:48-54. Available at: <http://www.ncbi.nlm.nih.gov/pubmed/21427182>.

146. Nishida Y, Kamada T, Imai R, et al. Clinical outcome of sacral chordoma with carbon ion radiotherapy compared with surgery. *Int J Radiat Oncol Biol Phys* 2011;79:110-116. Available at: <http://www.ncbi.nlm.nih.gov/pubmed/20400242>.

147. Gabriele P, Macias V, Stasi M, et al. Feasibility of intensity-modulated radiation therapy in the treatment of advanced cervical chordoma. *Tumori* 2003;89:298-304. Available at: <http://www.ncbi.nlm.nih.gov/pubmed/12908787>.

148. Yoneoka Y, Tsumanuma I, Fukuda M, et al. Cranial base chordoma--long term outcome and review of the literature. *Acta Neurochir (Wien)* 2008;150:773-778. Available at: <http://www.ncbi.nlm.nih.gov/pubmed/18548191>.

149. Zabel-du Bois A, Nikoghosyan A, Schwahofer A, et al. Intensity modulated radiotherapy in the management of sacral chordoma in primary versus recurrent disease. *Radiother Oncol* 2010;97:408-412. Available at: <http://www.ncbi.nlm.nih.gov/pubmed/21056488>.

150. Kano H, Iqbal FO, Sheehan J, et al. Stereotactic radiosurgery for chordoma: a report from the North American Gamma Knife Consortium. *Neurosurgery* 2011;68:379-389. Available at: <http://www.ncbi.nlm.nih.gov/pubmed/21135744>.

151. Bugoci DM, Girvigian MR, Chen JCT, et al. Photon-based Fractionated Stereotactic Radiotherapy for Postoperative Treatment of Skull Base Chordomas. *Am J Clin Oncol* 2012. Available at: <http://www.ncbi.nlm.nih.gov/pubmed/22772429>.

152. Fleming GF, Heimann PS, Stephens JK, et al. Dedifferentiated chordoma. Response to aggressive chemotherapy in two cases. *Cancer* 1993;72:714-718. Available at: <http://www.ncbi.nlm.nih.gov/pubmed/8334623>.

153. Tamborini E, Miselli F, Negri T, et al. Molecular and biochemical analyses of platelet-derived growth factor receptor (PDGFR) B, PDGFRA, and KIT receptors in chordomas. *Clin Cancer Res* 2006;12:6920-6928. Available at:

<http://www.ncbi.nlm.nih.gov/pubmed/17145809>.

154. Tamborini E, Virdis E, Negri T, et al. Analysis of receptor tyrosine kinases (RTKs) and downstream pathways in chordomas. *Neuro Oncol* 2010;12:776-789. Available at:

<http://www.ncbi.nlm.nih.gov/pubmed/20164240>.

155. Casali PG, Stacchiotti S, Grosso F, et al. Adding cisplatin (CDDP) to imatinib (IM) re-establishes tumor response following secondary resistance to IM in advanced chordoma [abstract]. *J Clin Oncol* 2007;25:Abstract 10038. Available at:

http://meeting.ascopubs.org/cgi/content/abstract/25/18_suppl/10038.

156. Stacchiotti S, Marrari A, Tamborini E, et al. Response to imatinib plus sirolimus in advanced chordoma. *Ann Oncol* 2009;20:1886-1894.

Available at: <http://www.ncbi.nlm.nih.gov/pubmed/19570961>.

157. Singhal N, Kotasek D, Parnis FX. Response to erlotinib in a patient with treatment refractory chordoma. *Anticancer Drugs* 2009;20:953-955.

Available at: <http://www.ncbi.nlm.nih.gov/pubmed/19730087>.

158. Launay SG, Chetaille B, Medina F, et al. Efficacy of epidermal growth factor receptor targeting in advanced chordoma: case report and literature review. *BMC Cancer* 2011;11:423-423. Available at:

<http://www.ncbi.nlm.nih.gov/pubmed/21970335>.

159. Stacchiotti S, Tamborini E, Lo Vullo S, et al. Phase II study on lapatinib in advanced EGFR-positive chordoma. *Ann Oncol* 2013;24:1931-1936. Available at:

<http://www.ncbi.nlm.nih.gov/pubmed/23559153>.

160. Thieblemont C, Biron P, Rocher F, et al. Prognostic factors in chordoma: role of postoperative radiotherapy. *Eur J Cancer*

1995;31A:2255-2259. Available at:

<http://www.ncbi.nlm.nih.gov/pubmed/8652252>.

161. Boriani S, Saravanja D, Yamada Y, et al. Challenges of local recurrence and cure in low grade malignant tumors of the spine. *Spine (Phila Pa 1976)* 2009;34:S48-57. Available at:

<http://www.ncbi.nlm.nih.gov/pubmed/19829277>.

162. Chambers PW, Schwinn CP. Chordoma. A clinicopathologic study of metastasis. *Am J Clin Pathol* 1979;72:765-776. Available at:

<http://www.ncbi.nlm.nih.gov/pubmed/389031>.

163. McPherson CM, Suki D, McCutcheon IE, et al. Metastatic disease from spinal chordoma: a 10-year experience. *J Neurosurg Spine* 2006;5:277-280. Available at:

<http://www.ncbi.nlm.nih.gov/pubmed/17048762>.

164. Shing DC, McMullan DJ, Roberts P, et al. FUS/ERG gene fusions in Ewing's tumors. *Cancer Res* 2003;63:4568-4576. Available at:

<http://www.ncbi.nlm.nih.gov/pubmed/12907633>.

165. Ng TL, O'Sullivan MJ, Pallen CJ, et al. Ewing sarcoma with novel translocation t(2;16) producing an in-frame fusion of FUS and FEV. *J Mol Diagn* 2007;9:459-463. Available at:

<http://www.ncbi.nlm.nih.gov/pubmed/17620387>.

166. Ambros IM, Ambros PF, Strehl S, et al. MIC2 is a specific marker for Ewing's sarcoma and peripheral primitive neuroectodermal tumors. Evidence for a common histogenesis of Ewing's sarcoma and peripheral primitive neuroectodermal tumors from MIC2 expression and specific chromosome aberration. *Cancer* 1991;67:1886-1893. Available at:

<http://www.ncbi.nlm.nih.gov/pubmed/1848471>.

167. Perlman EJ, Dickman PS, Askin FB, et al. Ewing's sarcoma--routine diagnostic utilization of MIC2 analysis: a Pediatric Oncology Group/Children's Cancer Group Intergroup Study. *Hum Pathol* 1994;25:304-307. Available at:

<http://www.ncbi.nlm.nih.gov/pubmed/8150461>.



168. Olsen SH, Thomas DG, Lucas DR. Cluster analysis of immunohistochemical profiles in synovial sarcoma, malignant peripheral nerve sheath tumor, and Ewing sarcoma. *Mod Pathol* 2006;19:659-668. Available at: <http://www.ncbi.nlm.nih.gov/pubmed/16528378>.

169. Glaubiger DL, Makuch R, Schwarz J, et al. Determination of prognostic factors and their influence on therapeutic results in patients with Ewing's sarcoma. *Cancer* 1980;45:2213-2219. Available at: <http://www.ncbi.nlm.nih.gov/pubmed/7370962>.

170. Gobel V, Jurgens H, Etspuler G, et al. Prognostic significance of tumor volume in localized Ewing's sarcoma of bone in children and adolescents. *J Cancer Res Clin Oncol* 1987;113:187-191. Available at: <http://www.ncbi.nlm.nih.gov/pubmed/3558454>.

171. Ahrens S, Hoffmann C, Jabar S, et al. Evaluation of prognostic factors in a tumor volume-adapted treatment strategy for localized Ewing sarcoma of bone: the CESS 86 experience. *Cooperative Ewing Sarcoma Study. Med Pediatr Oncol* 1999;32:186-195. Available at: <http://www.ncbi.nlm.nih.gov/pubmed/10064186>.

172. Bacci G, Longhi A, Ferrari S, et al. Prognostic factors in non-metastatic Ewing's sarcoma tumor of bone: an analysis of 579 patients treated at a single institution with adjuvant or neoadjuvant chemotherapy between 1972 and 1998. *Acta Oncol* 2006;45:469-475. Available at: <http://www.ncbi.nlm.nih.gov/pubmed/16760184>.

173. Rodriguez-Galindo C, Liu T, Krasin MJ, et al. Analysis of prognostic factors in ewing sarcoma family of tumors: review of St. Jude Children's Research Hospital studies. *Cancer* 2007;110:375-384. Available at: <http://www.ncbi.nlm.nih.gov/pubmed17569105>.

174. Serlo J, Helenius I, Vettenranta K, et al. Surgically treated patients with axial and peripheral Ewing's sarcoma family of tumours: A population based study in Finland during 1990-2009. *Eur J Surg Oncol* 2015;41:893-898. Available at: <http://www.ncbi.nlm.nih.gov/pubmed/25817983>.

175. Bacci G, Boriani S, Balladelli A, et al. Treatment of nonmetastatic Ewing's sarcoma family tumors of the spine and sacrum: the experience from a single institution. *Eur Spine J* 2009;18:1091-1095. Available at: <http://www.ncbi.nlm.nih.gov/pubmed19277725>.

176. Cangir A, Vietti TJ, Gehan EA, et al. Ewing's sarcoma metastatic at diagnosis. Results and comparisons of two intergroup Ewing's sarcoma studies. *Cancer* 1990;66:887-893. Available at: <http://www.ncbi.nlm.nih.gov/pubmed/2201433>.

177. Paulino AC, Mai WY, Teh BS. Radiotherapy in metastatic ewing sarcoma. *Am J Clin Oncol* 2013;36:283-286. Available at: <http://www.ncbi.nlm.nih.gov/pubmed/22547005>.

178. Oberlin O, Deley MC, Bui BN, et al. Prognostic factors in localized Ewing's tumours and peripheral neuroectodermal tumours: the third study of the French Society of Paediatric Oncology (EW88 study). *Br J Cancer* 2001;85:1646-1654. Available at: <http://www.ncbi.nlm.nih.gov/pubmed/11742482>.

179. Paulussen M, Ahrens S, Dunst J, et al. Localized Ewing tumor of bone: final results of the cooperative Ewing's Sarcoma Study CESS 86. *J Clin Oncol* 2001;19:1818-1829. Available at: <http://www.ncbi.nlm.nih.gov/pubmed/11251014>.

180. Kissane JM, Askin FB, Foulkes M, et al. Ewing's sarcoma of bone: clinicopathologic aspects of 303 cases from the Intergroup Ewing's Sarcoma Study. *Hum Pathol* 1983;14:773-779. Available at: <http://www.ncbi.nlm.nih.gov/pubmed/6885037>.

181. Gupta AA, Pappo A, Saunders N, et al. Clinical outcome of children and adults with localized Ewing sarcoma: impact of chemotherapy dose and timing of local therapy. *Cancer* 2010;116:3189-3194. Available at: <http://www.ncbi.nlm.nih.gov/pubmed/20564643>.

182. Lee J, Hoang BH, Ziogas A, Zell JA. Analysis of prognostic factors in Ewing sarcoma using a population-based cancer registry. *Cancer*



2010;116:1964-1973. Available at:

<http://www.ncbi.nlm.nih.gov/pubmed/20151425>.

183. Treglia G, Salsano M, Stefanelli A, et al. Diagnostic accuracy of (1)(8)F-FDG-PET and PET/CT in patients with Ewing sarcoma family tumours: a systematic review and a meta-analysis. *Skeletal Radiol* 2012;41:249-256. Available at:

<http://www.ncbi.nlm.nih.gov/pubmed/22072239>.

184. Avigad S, Cohen IJ, Zilberstein J, et al. The predictive potential of molecular detection in the nonmetastatic Ewing family of tumors. *Cancer* 2004;100:1053-1058. Available at:

<http://www.ncbi.nlm.nih.gov/pubmed/14983502>.

185. de Alava E, Kawai A, Healey JH, et al. EWS-FLI1 fusion transcript structure is an independent determinant of prognosis in Ewing's sarcoma. *J Clin Oncol* 1998;16:1248-1255. Available at:

<http://www.ncbi.nlm.nih.gov/pubmed/9552022>.

186. Zoubek A, Dockhorn-Dworniczak B, Delattre O, et al. Does expression of different EWS chimeric transcripts define clinically distinct risk groups of Ewing tumor patients? *J Clin Oncol* 1996;14:1245-1251. Available at:

<http://www.ncbi.nlm.nih.gov/pubmed/8648380>.

187. Le Deley MC, Delattre O, Schaefer KL, et al. Impact of EWS-ETS fusion type on disease progression in Ewing's sarcoma/peripheral primitive neuroectodermal tumor: prospective results from the cooperative Euro-E.W.I.N.G. 99 trial. *J Clin Oncol* 2010;28:1982-1988. Available at:

<http://www.ncbi.nlm.nih.gov/pubmed/20308673>.

188. van Doorninck JA, Ji L, Schaub B, et al. Current treatment protocols have eliminated the prognostic advantage of type 1 fusions in Ewing sarcoma: a report from the Children's Oncology Group. *J Clin Oncol* 2010;28:1989-1994. Available at:

<http://www.ncbi.nlm.nih.gov/pubmed/20308669>.

189. Dunst J, Jurgens H, Sauer R, et al. Radiation therapy in Ewing's sarcoma: an update of the CESS 86 trial. *Int J Radiat Oncol Biol Phys*

1995;32:919-930. Available at:

<http://www.ncbi.nlm.nih.gov/pubmed/7607966>.

190. Yock TI, Krailo M, Fryer CJ, et al. Local control in pelvic Ewing sarcoma: analysis from INT-0091--a report from the Children's Oncology Group. *J Clin Oncol* 2006;24:3838-3843. Available at:

<http://www.ncbi.nlm.nih.gov/pubmed/16921035>.

191. Schuck A, Ahrens S, Paulussen M, et al. Local therapy in localized Ewing tumors: results of 1058 patients treated in the CESS 81, CESS 86, and EICESS 92 trials. *Int J Radiat Oncol Biol Phys* 2003;55:168-177. Available at:

<http://www.ncbi.nlm.nih.gov/pubmed/12504050>.

192. DuBois SG, Krailo M, Gebhardt M, et al. Local and distant failure according to mode of local control in patients with localized Ewing sarcoma of bone: a report from the Children's Oncology Group [abstract]. *CTOS Annual Meeting; 2012:Abstract 20a*. Available at:

<http://www.ctos.org/meeting/2012/2012presentations.asp>.

193. Schuck A, Ahrens S, von Schorlemer I, et al. Radiotherapy in Ewing tumors of the vertebrae: treatment results and local relapse analysis of the CESS 81/86 and EICESS 92 trials. *Int J Radiat Oncol Biol Phys* 2005;63:1562-1567. Available at:

<http://www.ncbi.nlm.nih.gov/pubmed/16137838>.

194. Indelicato DJ, Keole SR, Shahlaee AH, et al. Definitive radiotherapy for ewing tumors of extremities and pelvis: long-term disease control, limb function, and treatment toxicity. *Int J Radiat Oncol Biol Phys* 2008;72:871-877. Available at:

195. Krasin MJ, Rodriguez-Galindo C, Billups CA, et al. Definitive irradiation in multidisciplinary management of localized Ewing sarcoma family of tumors in pediatric patients: outcome and prognostic factors. *Int J Radiat Oncol Biol Phys* 2004;60:830-838. Available at:

<http://www.ncbi.nlm.nih.gov/pubmed/15465200>.



196. Paulino AC, Nguyen TX, Mai WY, et al. Dose response and local control using radiotherapy in non-metastatic Ewing sarcoma. *Pediatr Blood Cancer* 2007;49:145-148. Available at:

197. Haeusler J, Ranft A, Boelling T, et al. The value of local treatment in patients with primary, disseminated, multifocal Ewing sarcoma (PDMES). *Cancer* 2010;116:443-450. Available at: <http://www.ncbi.nlm.nih.gov/pubmed/19924786>.

198. Paulussen M, Ahrens S, Burdach S, et al. Primary metastatic (stage IV) Ewing tumor: survival analysis of 171 patients from the EICESS studies. *European Intergroup Cooperative Ewing Sarcoma Studies. Ann Oncol* 1998;9:275-281. Available at: <http://www.ncbi.nlm.nih.gov/pubmed/9602261>.

199. Casey DL, Wexler LH, Meyers PA, et al. Radiation for bone metastases in Ewing sarcoma and rhabdomyosarcoma. *Pediatr Blood Cancer* 2015;62:445-449. Available at: <http://www.ncbi.nlm.nih.gov/pubmed/25346208>.

200. Burgert EO, Nesbit ME, Garnsey LA, et al. Multimodal therapy for the management of nonpelvic, localized Ewing's sarcoma of bone: intergroup study IESS-II. *J Clin Oncol* 1990;8:1514-1524. Available at: <http://www.ncbi.nlm.nih.gov/pubmed/2099751>.

201. Nesbit ME, Gehan EA, Burgert EO, et al. Multimodal therapy for the management of primary, nonmetastatic Ewing's sarcoma of bone: a long-term follow-up of the First Intergroup study. *J Clin Oncol* 1990;8:1664-1674. Available at: <http://www.ncbi.nlm.nih.gov/pubmed/2213103>.

202. Grier HE, Krailo MD, Tarbell NJ, et al. Addition of ifosfamide and etoposide to standard chemotherapy for Ewing's sarcoma and primitive neuroectodermal tumor of bone. *N Engl J Med* 2003;348:694-701. Available at: <http://www.ncbi.nlm.nih.gov/pubmed/12594313>.

203. Shamberger RC, LaQuaglia MP, Gebhardt MC, et al. Ewing sarcoma/primitive neuroectodermal tumor of the chest wall: impact of

initial versus delayed resection on tumor margins, survival, and use of radiation therapy. *Ann Surg* 2003;238:563-567; discussion 567-568. Available at: <http://www.ncbi.nlm.nih.gov/pubmed/14530727>.

204. Krasin MJ, Davidoff AM, Rodriguez-Galindo C, et al. Definitive surgery and multiagent systemic therapy for patients with localized Ewing sarcoma family of tumors: local outcome and prognostic factors. *Cancer* 2005;104:367-373. Available at: <http://www.ncbi.nlm.nih.gov/pubmed/15948159>.

205. Wexler LH, DeLaney TF, Tsokos M, et al. Ifosfamide and etoposide plus vincristine, doxorubicin, and cyclophosphamide for newly diagnosed Ewing's sarcoma family of tumors. *Cancer* 1996;78:901-911. Available at: <http://www.ncbi.nlm.nih.gov/pubmed/8756388>.

206. Rosito P, Mancini AF, Rondelli R, et al. Italian Cooperative Study for the treatment of children and young adults with localized Ewing sarcoma of bone: a preliminary report of 6 years of experience. *Cancer* 1999;86:421-428. Available at: <http://www.ncbi.nlm.nih.gov/pubmed/10430250>.

207. Kolb EA, Kushner BH, Gorlick R, et al. Long-term event-free survival after intensive chemotherapy for Ewing's family of tumors in children and young adults. *J Clin Oncol* 2003;21:3423-3430. Available at: <http://www.ncbi.nlm.nih.gov/pubmed/12972518>.

208. Oberlin O, Habrand JL, Zucker JM, et al. No benefit of ifosfamide in Ewing's sarcoma: a nonrandomized study of the French Society of Pediatric Oncology. *J Clin Oncol* 1992;10:1407-1412. Available at: <http://www.ncbi.nlm.nih.gov/pubmed/1517783>.

209. Bacci G, Picci P, Ferrari S, et al. Neoadjuvant chemotherapy for Ewing's sarcoma of bone: no benefit observed after adding ifosfamide and etoposide to vincristine, actinomycin, cyclophosphamide, and doxorubicin in the maintenance phase--results of two sequential studies. *Cancer* 1998;82:1174-1183. Available at: <http://www.ncbi.nlm.nih.gov/pubmed/9506366>.

210. Granowetter L, Womer R, Devidas M, et al. Dose-intensified compared with standard chemotherapy for nonmetastatic Ewing sarcoma family of tumors: a Children's Oncology Group Study. *J Clin Oncol* 2009;27:2536-2541. Available at: <http://www.ncbi.nlm.nih.gov/pubmed/19349548>.

211. Womer RB, West DC, Krailo MD, et al. Randomized Controlled Trial of Interval-Compressed Chemotherapy for the Treatment of Localized Ewing Sarcoma: A Report From the Children's Oncology Group. *Journal of Clinical Oncology* 2012;30:4148-4154. Available at: <http://www.ncbi.nlm.nih.gov/pubmed/23091096>.

212. Miser JS, Krailo MD, Tarbell NJ, et al. Treatment of metastatic Ewing's sarcoma or primitive neuroectodermal tumor of bone: evaluation of combination ifosfamide and etoposide--a Children's Cancer Group and Pediatric Oncology Group study. *J Clin Oncol* 2004;22:2873-2876. Available at: <http://www.ncbi.nlm.nih.gov/pubmed/15254055>.

213. Paulussen M, Craft AW, Lewis I, et al. Results of the EICESS-92 Study: two randomized trials of Ewing's sarcoma treatment--cyclophosphamide compared with ifosfamide in standard-risk patients and assessment of benefit of etoposide added to standard treatment in high-risk patients. *J Clin Oncol* 2008;26:4385-4393. Available at: <http://www.ncbi.nlm.nih.gov/pubmed/18802150>.

214. Le Deley MC, Paulussen M, Lewis I, et al. Cyclophosphamide Compared With Ifosfamide in Consolidation Treatment of Standard-Risk Ewing Sarcoma: Results of the Randomized Noninferiority Euro-EWING99-R1 Trial. *J Clin Oncol* 2014. Available at: <http://www.ncbi.nlm.nih.gov/pubmed/24982464>.

215. Ferrari S, Sundby Hall K, Luksch R, et al. Nonmetastatic Ewing family tumors: high-dose chemotherapy with stem cell rescue in poor responder patients. Results of the Italian Sarcoma Group/Scandinavian Sarcoma Group III protocol. *Annals of Oncology* 2011;22:1221-1227. Available at: <http://www.ncbi.nlm.nih.gov/pubmed/21059639>.

216. Gaspar N, Rey A, Berard PM, et al. Risk adapted chemotherapy for localised Ewing's sarcoma of bone: The French EW93 study. *Eur J Cancer* 2012;48:1376-1385. Available at: <http://www.ncbi.nlm.nih.gov/pubmed/22516209>.

217. Kushner BH, Meyers PA. How effective is dose-intensive/myeloablative therapy against Ewing's sarcoma/primitive neuroectodermal tumor metastatic to bone or bone marrow? The Memorial Sloan-Kettering experience and a literature review. *J Clin Oncol* 2001;19:870-880. Available at: <http://www.ncbi.nlm.nih.gov/pubmed/11157041>.

218. Juergens C, Weston C, Lewis I, et al. Safety assessment of intensive induction with vincristine, ifosfamide, doxorubicin, and etoposide (VIDE) in the treatment of Ewing tumors in the EURO-E.W.I.N.G. 99 clinical trial. *Pediatr Blood Cancer* 2006;47:22-29. Available at: <http://www.ncbi.nlm.nih.gov/pubmed/16572419>.

219. Oberlin O, Rey A, Desfachelles AS, et al. Impact of high-dose busulfan plus melphalan as consolidation in metastatic Ewing tumors: a study by the Societe Francaise des Cancers de l'Enfant. *J Clin Oncol* 2006;24:3997-4002. Available at: <http://www.ncbi.nlm.nih.gov/pubmed/16921053>.

220. Rosenthal J, Bolotin E, Shakhnovits M, et al. High-dose therapy with hematopoietic stem cell rescue in patients with poor prognosis Ewing family tumors. *Bone Marrow Transplant* 2008;42:311-318. Available at: <http://www.ncbi.nlm.nih.gov/pubmed/18587438>.

221. Burdach S, Thiel U, Schoniger M, et al. Total body MRI-governed involved compartment irradiation combined with high-dose chemotherapy and stem cell rescue improves long-term survival in Ewing tumor patients with multiple primary bone metastases. *Bone Marrow Transplant* 2010;45:483-489. Available at: <http://www.ncbi.nlm.nih.gov/pubmed/19684633>.

222. Ladenstein R, Potschger U, Le Deley MC, et al. Primary disseminated multifocal Ewing sarcoma: results of the Euro-EWING 99



NCCN Guidelines Version 2.2016

Bone Cancer

trial. *J Clin Oncol* 2010;28:3284-3291. Available at:
<http://www.ncbi.nlm.nih.gov/pubmed/20547982>.

223. Denbo JW, Shannon Orr W, Wu Y, et al. Timing of surgery and the role of adjuvant radiotherapy in ewing sarcoma of the chest wall: a single-institution experience. *Ann Surg Oncol* 2012;19:3809-3815. Available at: <http://www.ncbi.nlm.nih.gov/pubmed/22752372>.

224. Bacci G, Forni C, Longhi A, et al. Long-term outcome for patients with non-metastatic Ewing's sarcoma treated with adjuvant and neoadjuvant chemotherapies. 402 patients treated at Rizzoli between 1972 and 1992. *Eur J Cancer* 2004;40:73-83. Available at: <http://www.ncbi.nlm.nih.gov/pubmed/14687792>.

225. Rodriguez-Galindo C, Billups CA, Kun LE, et al. Survival after recurrence of Ewing tumors: the St Jude Children's Research Hospital experience, 1979-1999. *Cancer* 2002;94:561-569. Available at: <http://www.ncbi.nlm.nih.gov/pubmed/11900241>.

226. Bacci G, Ferrari S, Longhi A, et al. Therapy and survival after recurrence of Ewing's tumors: the Rizzoli experience in 195 patients treated with adjuvant and neoadjuvant chemotherapy from 1979 to 1997. *Ann Oncol* 2003;14:1654-1659. Available at: <http://www.ncbi.nlm.nih.gov/pubmed/14581274>.

227. Leavey PJ, Mascarenhas L, Marina N, et al. Prognostic factors for patients with Ewing sarcoma (EWS) at first recurrence following multi-modality therapy: A report from the Children's Oncology Group. *Pediatr Blood Cancer* 2008;51:334-338. Available at: <http://www.ncbi.nlm.nih.gov/pubmed/18506764>.

228. Ferrari S, Luksch R, Hall KS, et al. Post-relapse survival in patients with Ewing sarcoma. *Pediatr Blood Cancer* 2015;62:994-999. Available at:

229. Robinson SI, Ahmed SK, Laack NN, et al. Clinical outcomes of adult patients with relapsed Ewing sarcoma: A 30-year single institution

experience. *ASCO Meeting Abstracts* 2011;29:10041. Available at: http://meeting.ascopubs.org/cgi/content/abstract/29/15_suppl/10041.

230. Stahl M, Ranft A, Paulussen M, et al. Risk of recurrence and survival after relapse in patients with Ewing sarcoma. *Pediatr Blood Cancer* 2011;57:549-553. Available at: <http://www.ncbi.nlm.nih.gov/pubmed/21442722>.

231. Miser JS, Kinsella TJ, Triche TJ, et al. Ifosfamide with mesna uroprotection and etoposide: an effective regimen in the treatment of recurrent sarcomas and other tumors of children and young adults. *J Clin Oncol* 1987;5:1191-1198. Available at: <http://www.ncbi.nlm.nih.gov/pubmed/3114435>.

232. Van Winkle P, Angiolillo A, Krailo M, et al. Ifosfamide, carboplatin, and etoposide (ICE) reinduction chemotherapy in a large cohort of children and adolescents with recurrent/refractory sarcoma: the Children's Cancer Group (CCG) experience. *Pediatr Blood Cancer* 2005;44:338-347. Available at: <http://www.ncbi.nlm.nih.gov/pubmed/15503297>.

233. Rasper M, Jabar S, Ranft A, et al. The value of high-dose chemotherapy in patients with first relapsed Ewing sarcoma. *Pediatr Blood Cancer* 2014;61:1382-1386. Available at: <http://www.ncbi.nlm.nih.gov/pubmed/24729428>.

234. Magnan H, Goodbody CM, Riedel E, et al. Ifosfamide dose-intensification for patients with metastatic Ewing sarcoma. *Pediatr Blood Cancer* 2015;62:594-597. Available at: <http://www.ncbi.nlm.nih.gov/pubmed/25630954>.

235. Navid F, Willert JR, McCarville MB, et al. Combination of gemcitabine and docetaxel in the treatment of children and young adults with refractory bone sarcoma. *Cancer* 2008;113:419-425. Available at: <http://www.ncbi.nlm.nih.gov/pubmed/18484657>.

236. Bernstein ML, Devidas M, Lafreniere D, et al. Intensive therapy with growth factor support for patients with Ewing tumor metastatic at

diagnosis: Pediatric Oncology Group/Children's Cancer Group Phase II Study 9457--a report from the Children's Oncology Group. *J Clin Oncol* 2006;24:152-159. Available at:

<http://www.ncbi.nlm.nih.gov/pubmed/16382125>.

237. Hunold A, Weddeling N, Paulussen M, et al. Topotecan and cyclophosphamide in patients with refractory or relapsed Ewing tumors. *Pediatr Blood Cancer* 2006;47:795-800. Available at:

<http://www.ncbi.nlm.nih.gov/pubmed/16411206>.

238. Kushner BH, Kramer K, Meyers PA, et al. Pilot study of topotecan and high-dose cyclophosphamide for resistant pediatric solid tumors. *Med Pediatr Oncol* 2000;35:468-474. Available at:

<http://www.ncbi.nlm.nih.gov/pubmed/11070479>.

239. Saylor RL, Stine KC, Sullivan J, et al. Cyclophosphamide plus topotecan in children with recurrent or refractory solid tumors: a Pediatric Oncology Group phase II study. *J Clin Oncol* 2001;19:3463-3469. Available at: <http://www.ncbi.nlm.nih.gov/pubmed/11481351>.

240. Casey DA, Wexler LH, Merchant MS, et al. Irinotecan and temozolomide for Ewing sarcoma: the Memorial Sloan-Kettering experience. *Pediatr Blood Cancer* 2009;53:1029-1034. Available at:

<http://www.ncbi.nlm.nih.gov/pubmed/19637327>.

241. Wagner LM, Crews KR, Iacono LC, et al. Phase I trial of temozolomide and protracted irinotecan in pediatric patients with refractory solid tumors. *Clin Cancer Res* 2004;10:840-848. Available at:

<http://www.ncbi.nlm.nih.gov/pubmed/14871959>.

242. Wagner LM, McAllister N, Goldsby RE, et al. Temozolomide and intravenous irinotecan for treatment of advanced Ewing sarcoma. *Pediatr Blood Cancer* 2007;48:132-139. Available at:

<http://www.ncbi.nlm.nih.gov/pubmed/16317751>.

243. Raciborska A, Biliska K, Drabko K, et al. Vincristine, irinotecan, and temozolomide in patients with relapsed and refractory Ewing sarcoma.

Pediatr Blood Cancer 2013;60:1621-1625. Available at:

<http://www.ncbi.nlm.nih.gov/pubmed/23776128>.

244. van Maldegem AM, Benson C, Rutkowski P, et al. Etoposide and carbo-or cisplatin combination therapy in refractory or relapsed Ewing sarcoma: a large retrospective study. *Pediatr Blood Cancer* 2015;62:40-44. Available at: <http://www.ncbi.nlm.nih.gov/pubmed/25251256>.

245. Burdach S, Jurgens H, Peters C, et al. Myeloablative radiochemotherapy and hematopoietic stem-cell rescue in poor-prognosis Ewing's sarcoma. *J Clin Oncol* 1993;11:1482-1488. Available at: <http://www.ncbi.nlm.nih.gov/pubmed/8101562>.

246. Barker LM, Pendergrass TW, Sanders JE, Hawkins DS. Survival after recurrence of Ewing's sarcoma family of tumors. *J Clin Oncol* 2005;23:4354-4362. Available at:

<http://www.ncbi.nlm.nih.gov/pubmed/15781881>.

247. McTiernan A, Driver D, Michelagnoli MP, et al. High dose chemotherapy with bone marrow or peripheral stem cell rescue is an effective treatment option for patients with relapsed or progressive Ewing's sarcoma family of tumours. *Ann Oncol* 2006;17:1301-1305. Available at: <http://www.ncbi.nlm.nih.gov/pubmed/16782749>.

248. Dominkus M, Ruggieri P, Bertoni F, et al. Histologically verified lung metastases in benign giant cell tumours--14 cases from a single institution. *Int Orthop* 2006;30:499-504. Available at:

<http://www.ncbi.nlm.nih.gov/pubmed/16909252>.

249. Viswanathan S, Jambhekar NA. Metastatic giant cell tumor of bone: are there associated factors and best treatment modalities? *Clin Orthop Relat Res* 2010;468:827-833. Available at:

<http://www.ncbi.nlm.nih.gov/pubmed/19597900>.

250. Anract P, De Pinieux G, Cottias P, et al. Malignant giant-cell tumours of bone. Clinico-pathological types and prognosis: a review of 29 cases. *Int Orthop* 1998;22:19-26. Available at:

<http://www.ncbi.nlm.nih.gov/pubmed/9549577>.



251. Bertoni F, Bacchini P, Staals EL. Malignancy in giant cell tumor of bone. *Cancer* 2003;97:2520-2529. Available at: <http://www.ncbi.nlm.nih.gov/pubmed/12733152>.

252. Purohit S, Pardiwala DN. Imaging of giant cell tumor of bone. *Indian J Orthop* 2007;41:91-96. Available at: <http://www.ncbi.nlm.nih.gov/pubmed/21139758>.

253. Thomas DM, Skubitz KM. Giant cell tumour of bone. *Curr Opin Oncol* 2009;21:338-344. Available at: <http://www.ncbi.nlm.nih.gov/pubmed/19444102>.

254. Werner M. Giant cell tumour of bone: morphological, biological and histogenetical aspects. *Int Orthop* 2006;30:484-489. Available at: <http://www.ncbi.nlm.nih.gov/pubmed/17013643>.

255. McDonald DJ, Sim FH, McLeod RA, Dahlin DC. Giant-cell tumor of bone. *J Bone Joint Surg Am* 1986;68:235-242. Available at: <http://www.ncbi.nlm.nih.gov/pubmed/3511063>.

256. Campanacci M, Baldini N, Boriani S, Sudanese A. Giant-cell tumor of bone. *J Bone Joint Surg Am* 1987;69:106-114. Available at: <http://www.ncbi.nlm.nih.gov/pubmed/3805057>.

257. Saiz P, Virkus W, Piasecki P, et al. Results of giant cell tumor of bone treated with intralesional excision. *Clin Orthop Relat Res* 2004;221-226. Available at: <http://www.ncbi.nlm.nih.gov/pubmed/15241169>.

258. Malek F, Krueger P, Hatmi ZN, et al. Local control of long bone giant cell tumour using curettage, burring and bone grafting without adjuvant therapy. *Int Orthop* 2006;30:495-498. Available at: <http://www.ncbi.nlm.nih.gov/pubmed/16896875>.

259. Kivioja AH, Blomqvist C, Hietaniemi K, et al. Cement is recommended in intralesional surgery of giant cell tumors: a Scandinavian Sarcoma Group study of 294 patients followed for a

median time of 5 years. *Acta Orthop* 2008;79:86-93. Available at: <http://www.ncbi.nlm.nih.gov/pubmed/18283578>.

260. Errani C, Ruggieri P, Asenzio MA, et al. Giant cell tumor of the extremity: A review of 349 cases from a single institution. *Cancer Treat Rev* 2010;36:1-7. Available at: <http://www.ncbi.nlm.nih.gov/pubmed/19879054>.

261. Klenke FM, Wenger DE, Inwards CY, et al. Giant cell tumor of bone: risk factors for recurrence. *Clin Orthop Relat Res* 2011;469:591-599. Available at: <http://www.ncbi.nlm.nih.gov/pubmed/20706812>.

262. O'Donnell RJ, Springfield DS, Motwani HK, et al. Recurrence of giant-cell tumors of the long bones after curettage and packing with cement. *J Bone Joint Surg Am* 1994;76:1827-1833. Available at: <http://www.ncbi.nlm.nih.gov/pubmed/7989388>.

263. Blackley HR, Wunder JS, Davis AM, et al. Treatment of giant-cell tumors of long bones with curettage and bone-grafting. *J Bone Joint Surg Am* 1999;81:811-820. Available at: <http://www.ncbi.nlm.nih.gov/pubmed/10391546>.

264. Prosser GH, Baloch KG, Tillman RM, et al. Does curettage without adjuvant therapy provide low recurrence rates in giant-cell tumors of bone? *Clin Orthop Relat Res* 2005;211-218. Available at: <http://www.ncbi.nlm.nih.gov/pubmed/15930941>.

265. Becker WT, Dohle J, Bernd L, et al. Local recurrence of giant cell tumor of bone after intralesional treatment with and without adjuvant therapy. *J Bone Joint Surg Am* 2008;90:1060-1067. Available at: <http://www.ncbi.nlm.nih.gov/pubmed/18451399>.

266. Balke M, Schremper L, Gebert C, et al. Giant cell tumor of bone: treatment and outcome of 214 cases. *J Cancer Res Clin Oncol* 2008;134:969-978. Available at: <http://www.ncbi.nlm.nih.gov/pubmed/18322700>.

267. Pietschmann MF, Dietz RA, Utschneider S, et al. The influence of adjuvants on local recurrence rate in giant cell tumour of the bone. *Acta Chir Belg* 2010;110:584-589. Available at: <http://www.ncbi.nlm.nih.gov/pubmed/21337837>.
268. Klenke FM, Wenger DE, Inwards CY, et al. Recurrent giant cell tumor of long bones: analysis of surgical management. *Clin Orthop Relat Res* 2011;469:1181-1187. Available at: <http://www.ncbi.nlm.nih.gov/pubmed/20857250>.
269. Trieb K, Bitzan P, Lang S, et al. Recurrence of curetted and bone-grafted giant-cell tumours with and without adjuvant phenol therapy. *Eur J Surg Oncol* 2001;27:200-202. Available at: <http://www.ncbi.nlm.nih.gov/pubmed/11289759>.
270. Turcotte RE, Wunder JS, Isler MH, et al. Giant cell tumor of long bone: a Canadian Sarcoma Group study. *Clin Orthop Relat Res* 2002;248-258. Available at: <http://www.ncbi.nlm.nih.gov/pubmed/11953616>.
271. Oda Y, Miura H, Tsuneyoshi M, Iwamoto Y. Giant cell tumor of bone: oncological and functional results of long-term follow-up. *Jpn J Clin Oncol* 1998;28:323-328. Available at: <http://www.ncbi.nlm.nih.gov/pubmed/9703860>.
272. Boons HW, Keijser LC, Schreuder HW, et al. Oncologic and functional results after treatment of giant cell tumors of bone. *Arch Orthop Trauma Surg* 2002;122:17-23. Available at: <http://www.ncbi.nlm.nih.gov/pubmed/11995874>.
273. Su YP, Chen WM, Chen TH. Giant-cell tumors of bone: an analysis of 87 cases. *Int Orthop* 2004;28:239-243. Available at: <http://www.ncbi.nlm.nih.gov/pubmed/15160253>.
274. Rastogi S, Prashanth I, Khan SA, et al. Giant cell tumor of bone: Is curettage the answer? *Indian J Orthop* 2007;41:109-114. Available at: <http://www.ncbi.nlm.nih.gov/pubmed/21139761>.
275. Guo W, Sun X, Zang J, Qu H. Intralesional excision versus wide resection for giant cell tumor involving the acetabulum: which is better? *Clin Orthop Relat Res* 2012;470:1213-1220. Available at: <http://www.ncbi.nlm.nih.gov/pubmed/22125245>.
276. Labs K, Perka C, Schmidt RG. Treatment of stages 2 and 3 giant-cell tumor. *Arch Orthop Trauma Surg* 2001;121:83-86. Available at: <http://www.ncbi.nlm.nih.gov/pubmed/11195127>.
277. Mankin HJ, Hornicek FJ. Treatment of giant cell tumors with allograft transplants: a 30-year study. *Clin Orthop Relat Res* 2005;439:144-150. Available at: <http://www.ncbi.nlm.nih.gov/pubmed/16205153>.
278. Mendenhall WM, Zlotecki RA, Scarborough MT, et al. Giant cell tumor of bone. *Am J Clin Oncol* 2006;29:96-99. Available at: <http://www.ncbi.nlm.nih.gov/pubmed/16462511>.
279. Saini R, Bali K, Bachhal V, et al. En bloc excision and autogenous fibular reconstruction for aggressive giant cell tumor of distal radius: a report of 12 cases and review of literature. *J Orthop Surg Res* 2011;6:14. Available at: <http://www.ncbi.nlm.nih.gov/pubmed/21385393>.
280. Dahlin DC. Caldwell Lecture. Giant cell tumor of bone: highlights of 407 cases. *AJR Am J Roentgenol* 1985;144:955-960. Available at: <http://www.ncbi.nlm.nih.gov/pubmed/3872579>.
281. Schwartz LH, Okunieff PG, Rosenberg A, Suit HD. Radiation therapy in the treatment of difficult giant cell tumors. *Int J Radiat Oncol Biol Phys* 1989;17:1085-1088. Available at: <http://www.ncbi.nlm.nih.gov/pubmed/2808042>.
282. Bennett CJ, Marcus RB, Million RR, Enneking WF. Radiation therapy for giant cell tumor of bone. *Int J Radiat Oncol Biol Phys* 1993;26:299-304. Available at: <http://www.ncbi.nlm.nih.gov/pubmed/8491687>.



283. Malone S, O'Sullivan B, Catton C, et al. Long-term follow-up of efficacy and safety of megavoltage radiotherapy in high-risk giant cell tumors of bone. *Int J Radiat Oncol Biol Phys* 1995;33:689-694. Available at: <http://www.ncbi.nlm.nih.gov/pubmed/7558960>.

284. Chakravarti A, Spiro IJ, Hug EB, et al. Megavoltage radiation therapy for axial and inoperable giant-cell tumor of bone. *J Bone Joint Surg Am* 1999;81:1566-1573. Available at: <http://www.ncbi.nlm.nih.gov/pubmed/10565648>.

285. Nair MK, Jyothirmayi R. Radiation therapy in the treatment of giant cell tumor of bone. *Int J Radiat Oncol Biol Phys* 1999;43:1065-1069. Available at: <http://www.ncbi.nlm.nih.gov/pubmed/10192357>.

286. Miszczyk L, Wydmanski J, Spindel J. Efficacy of radiotherapy for giant cell tumor of bone: given either postoperatively or as sole treatment. *Int J Radiat Oncol Biol Phys* 2001;49:1239-1242. Available at: <http://www.ncbi.nlm.nih.gov/pubmed/11286829>.

287. Caudell JJ, Ballo MT, Zagars GK, et al. Radiotherapy in the management of giant cell tumor of bone. *Int J Radiat Oncol Biol Phys* 2003;57:158-165. Available at: <http://www.ncbi.nlm.nih.gov/pubmed/12909228>.

288. Feigenberg SJ, Marcus Jr RB, Zlotecki RA, et al. Radiation therapy for giant cell tumors of bone. *Clin Orthop Relat Res* 2003;207-216. Available at: <http://www.ncbi.nlm.nih.gov/pubmed/12782877>.

289. Ruka W, Rutkowski P, Morysinski T, et al. The megavoltage radiation therapy in treatment of patients with advanced or difficult giant cell tumors of bone. *Int J Radiat Oncol Biol Phys* 2010;78:494-498. Available at: <http://www.ncbi.nlm.nih.gov/pubmed/20004531>.

290. Bhatia S, Miszczyk L, Roelandts M, et al. Radiotherapy for marginally resected, unresectable or recurrent giant cell tumor of the bone: a rare cancer network study. *Rare Tumors* 2011;3. Available at: <http://www.ncbi.nlm.nih.gov/pubmed/22355503>.

291. Hug EB, Muentner MW, Adams JA, et al. 3-D-conformal radiation therapy for pediatric giant cell tumors of the skull base. *Strahlenther Onkol* 2002;178:239-244. Available at: <http://www.ncbi.nlm.nih.gov/pubmed/12082682>.

292. Roeder F, Timke C, Zwicker F, et al. Intensity modulated radiotherapy (IMRT) in benign giant cell tumors--a single institution case series and a short review of the literature. *Radiat Oncol* 2010;5:18. Available at: <http://www.ncbi.nlm.nih.gov/pubmed/20187955>.

293. Thomas D, Henshaw R, Skubitz K, et al. Denosumab in patients with giant-cell tumour of bone: an open-label, phase 2 study. *Lancet Oncol* 2010;11:275-280. Available at: <http://www.ncbi.nlm.nih.gov/pubmed/20149736>.

294. Branstetter DG, Nelson SD, Manivel JC, et al. Denosumab induces tumor reduction and bone formation in patients with giant-cell tumor of bone. *Clin Cancer Res* 2012;18:4415-4424. Available at: <http://www.ncbi.nlm.nih.gov/pubmed/22711702>.

295. Chawla S, Henshaw R, Seeger L, et al. Safety and efficacy of denosumab for adults and skeletally mature adolescents with giant cell tumour of bone: interim analysis of an open-label, parallel-group, phase 2 study. *Lancet Oncol* 2013;14:901-908. Available at: <http://www.ncbi.nlm.nih.gov/pubmed/23867211>.

296. Martin-Broto J, Cleeland CS, Glare PA, et al. Effects of denosumab on pain and analgesic use in giant cell tumor of bone: interim results from a phase II study. *Acta Oncol* 2014;53:1173-1179. Available at:

297. Skubitz KM, Thomas DM, Chawla SP, et al. Response to treatment with denosumab in patients with giant cell tumor of bone (GCTB): FDG PET results from two phase 2 trials [abstract]. *ASCO Meeting Abstracts* 2014;32:10505. Available at: http://meeting.ascopubs.org/cgi/content/abstract/32/15_suppl/10505.



298. Lin PP, Guzel VB, Moura MF, et al. Long-term follow-up of patients with giant cell tumor of the sacrum treated with selective arterial embolization. *Cancer* 2002;95:1317-1325. Available at: <http://www.ncbi.nlm.nih.gov/pubmed/12216101>.

299. Hosalkar HS, Jones KJ, King JJ, Lackman RD. Serial arterial embolization for large sacral giant-cell tumors: mid- to long-term results. *Spine (Phila Pa 1976)* 2007;32:1107-1115. Available at: <http://www.ncbi.nlm.nih.gov/pubmed/17471094>.

300. Onishi H, Kaya M, Wada T, et al. Giant cell tumor of the sacrum treated with selective arterial embolization. *Int J Clin Oncol* 2010;15:416-419. Available at: <http://www.ncbi.nlm.nih.gov/pubmed/20198397>.

301. Emori M, Kaya M, Sasaki M, et al. Pre-operative Selective Arterial Embolization as a Neoadjuvant Therapy for Proximal Humerus Giant Cell Tumor of Bone: Radiological and Histological Evaluation. *Jpn J Clin Oncol* 2012;42:851-855. Available at: <http://www.ncbi.nlm.nih.gov/pubmed/22689917>.

302. Kaiser U, Neumann K, Havemann K. Generalised giant-cell tumour of bone: successful treatment of pulmonary metastases with interferon alpha, a case report. *J Cancer Res Clin Oncol* 1993;119:301-303. Available at: <http://www.ncbi.nlm.nih.gov/pubmed/8440744>.

303. Yasko AW. Interferon therapy for giant cell tumor of bone. *Current Opinion in Orthopaedics* 2006;17:568-572 Available at: http://journals.lww.com/ortho/Fulltext/2006/12000/Interferon_therapy_for_giant_cell_tumor_of_bone.17.aspx.

304. Kaban LB, Troulis MJ, Wilkinson MS, et al. Adjuvant antiangiogenic therapy for giant cell tumors of the jaws. *J Oral Maxillofac Surg* 2007;65:2018-2024; discussion 2024. Available at: <http://www.ncbi.nlm.nih.gov/pubmed/17884531>.

305. Wei F, Liu X, Liu Z, et al. Interferon alfa-2b for recurrent and metastatic giant cell tumor of the spine: report of two cases. *Spine (Phila Pa 1976)* 2010;35:E1418-1422. Available at: <http://www.ncbi.nlm.nih.gov/pubmed/21030898>.

306. Cheng JC, Johnston JO. Giant cell tumor of bone. Prognosis and treatment of pulmonary metastases. *Clin Orthop Relat Res* 1997;205-214. Available at: <http://www.ncbi.nlm.nih.gov/pubmed/9170381>.

307. Siebenrock KA, Unni KK, Rock MG. Giant-cell tumour of bone metastasising to the lungs. A long-term follow-up. *J Bone Joint Surg Br* 1998;80:43-47. Available at: <http://www.ncbi.nlm.nih.gov/pubmed/9460951>.

308. Klein MJ, Siegal GP. Osteosarcoma: anatomic and histologic variants. *Am J Clin Pathol* 2006;125:555-581. Available at: <http://www.ncbi.nlm.nih.gov/pubmed/16627266>.

309. Antonescu CR, Huvos AG. Low-grade osteogenic sarcoma arising in medullary and surface osseous locations. *Am J Clin Pathol* 2000;114 Suppl:S90-103. Available at: <http://www.ncbi.nlm.nih.gov/pubmed/11996175>.

310. Sheth DS, Yasko AW, Raymond AK, et al. Conventional and dedifferentiated parosteal osteosarcoma. Diagnosis, treatment, and outcome. *Cancer* 1996;78:2136-2145. Available at: <http://www.ncbi.nlm.nih.gov/pubmed/8918422>.

311. Bertoni F, Bacchini P, Staals EL, Davidovitz P. Dedifferentiated parosteal osteosarcoma: the experience of the Rizzoli Institute. *Cancer* 2005;103:2373-2382. Available at: <http://www.ncbi.nlm.nih.gov/pubmed/15852358>.

312. Okada K, Unni KK, Swee RG, Sim FH. High grade surface osteosarcoma: a clinicopathologic study of 46 cases. *Cancer* 1999;85:1044-1054. Available at: <http://www.ncbi.nlm.nih.gov/pubmed/10091787>.

313. Staals EL, Bacchini P, Bertoni F. High-grade surface osteosarcoma: a review of 25 cases from the Rizzoli Institute. *Cancer* 2008;112:1592-1599. Available at:

<http://www.ncbi.nlm.nih.gov/pubmed/18300258>.

314. Davis AM, Bell RS, Goodwin PJ. Prognostic factors in osteosarcoma: a critical review. *J Clin Oncol* 1994;12:423-431.

Available at: <http://www.ncbi.nlm.nih.gov/pubmed/8113851>.

315. Ferrari S, Bertoni F, Mercuri M, et al. Predictive factors of disease-free survival for non-metastatic osteosarcoma of the extremity: an analysis of 300 patients treated at the Rizzoli Institute. *Ann Oncol* 2001;12:1145-1150. Available at:

<http://www.ncbi.nlm.nih.gov/pubmed/11583198>.

316. Bielack SS, Kempf-Bielack B, Delling G, et al. Prognostic factors in high-grade osteosarcoma of the extremities or trunk: an analysis of 1,702 patients treated on neoadjuvant cooperative osteosarcoma study group protocols. *J Clin Oncol* 2002;20:776-790. Available at:

<http://www.ncbi.nlm.nih.gov/pubmed/11821461>.

317. Bacci G, Longhi A, Ferrari S, et al. Prognostic significance of serum lactate dehydrogenase in osteosarcoma of the extremity: experience at Rizzoli on 1421 patients treated over the last 30 years. *Tumori* 2004;90:478-484. Available at:

<http://www.ncbi.nlm.nih.gov/pubmed/15656333>.

318. Bacci G, Longhi A, Versari M, et al. Prognostic factors for osteosarcoma of the extremity treated with neoadjuvant chemotherapy: 15-year experience in 789 patients treated at a single institution. *Cancer* 2006;106:1154-1161. Available at:

<http://www.ncbi.nlm.nih.gov/pubmed/16421923>.

319. Whelan JS, Jinks RC, McTiernan A, et al. Survival from high-grade localised extremity osteosarcoma: combined results and prognostic factors from three European Osteosarcoma Intergroup randomised controlled trials. *Ann Oncol* 2012;23:1607-1616. Available at:

<http://www.ncbi.nlm.nih.gov/pubmed/22015453>.

320. Collins M, Wilhelm M, Conyers R, et al. Benefits and adverse events in younger versus older patients receiving neoadjuvant chemotherapy for osteosarcoma: findings from a meta-analysis. *J Clin Oncol* 2013;31:2303-2312. Available at:

<http://www.ncbi.nlm.nih.gov/pubmed/23669227>.

321. Altaf S, Enders F, Jeavons E, et al. High-BMI at diagnosis is associated with inferior survival in patients with osteosarcoma: a report from the Children's Oncology Group. *Pediatr Blood Cancer* 2013;60:2042-2046. Available at:

<http://www.ncbi.nlm.nih.gov/pubmed/23955975>.

322. Bacci G, Briccoli A, Ferrari S, et al. Neoadjuvant chemotherapy for osteosarcoma of the extremities with synchronous lung metastases: treatment with cisplatin, adriamycin and high dose of methotrexate and ifosfamide. *Oncol Rep* 2000;7:339-346. Available at:

<http://www.ncbi.nlm.nih.gov/pubmed/10671683>.

323. Daw NC, Billups CA, Rodriguez-Galindo C, et al. Metastatic osteosarcoma. *Cancer* 2006;106:403-412. Available at:

<http://www.ncbi.nlm.nih.gov/pubmed/16353204>.

324. Marulanda GA, Henderson ER, Johnson DA, et al. Orthopedic surgery options for the treatment of primary osteosarcoma. *Cancer Control* 2008;15:13-20. Available at:

<http://www.ncbi.nlm.nih.gov/pubmed/18094657>.

325. Bacci G, Ferrari S, Lari S, et al. Osteosarcoma of the limb. Amputation or limb salvage in patients treated by neoadjuvant chemotherapy. *J Bone Joint Surg Br* 2002;84:88-92. Available at:

<http://www.ncbi.nlm.nih.gov/pubmed/11837839>.

326. Mavrogenis AF, Abati CN, Romagnoli C, Ruggieri P. Similar survival but better function for patients after limb salvage versus amputation for distal tibia osteosarcoma. *Clin Orthop Relat Res* 2012;470:1735-1748. Available at:

<http://www.ncbi.nlm.nih.gov/pubmed/22270466>.

327. Simon MA, Aschliman MA, Thomas N, Mankin HJ. Limb-salvage treatment versus amputation for osteosarcoma of the distal end of the femur. 1986. *J Bone Joint Surg Am* 2005;87:2822-2822. Available at: <http://www.ncbi.nlm.nih.gov/pubmed16322634>.

328. Aksnes LH, Bauer HCF, Jebsen NL, et al. Limb-sparing surgery preserves more function than amputation: a Scandinavian sarcoma group study of 118 patients. *J Bone Joint Surg Br* 2008;90:786-794. Available at: <http://www.ncbi.nlm.nih.gov/pubmed18539673>.

329. Nagarajan R, Neglia JP, Clohisy DR, Robison LL. Limb salvage and amputation in survivors of pediatric lower-extremity bone tumors: what are the long-term implications? *J Clin Oncol* 2002;20:4493-4501. Available at: <http://www.ncbi.nlm.nih.gov/pubmed12431974>.

330. Winkler K, Beron G, Kotz R, et al. Neoadjuvant chemotherapy for osteogenic sarcoma: results of a Cooperative German/Austrian study. *J Clin Oncol* 1984;2:617-624. Available at: <http://www.ncbi.nlm.nih.gov/pubmed/6202851>.

331. Link MP, Goorin AM, Miser AW, et al. The effect of adjuvant chemotherapy on relapse-free survival in patients with osteosarcoma of the extremity. *N Engl J Med* 1986;314:1600-1606. Available at: <http://www.ncbi.nlm.nih.gov/pubmed/3520317>.

332. Eilber F, Giuliano A, Eckardt J, et al. Adjuvant chemotherapy for osteosarcoma: a randomized prospective trial. *J Clin Oncol* 1987;5:21-26. Available at: <http://www.ncbi.nlm.nih.gov/pubmed/3543236>.

333. Link MP, Goorin AM, Horowitz M, et al. Adjuvant chemotherapy of high-grade osteosarcoma of the extremity. Updated results of the Multi-Institutional Osteosarcoma Study. *Clin Orthop Relat Res* 1991;8-14. Available at: <http://www.ncbi.nlm.nih.gov/pubmed/1884563>.

334. Meyers PA, Heller G, Healey J, et al. Chemotherapy for nonmetastatic osteogenic sarcoma: the Memorial Sloan-Kettering experience. *J Clin Oncol* 1992;10:5-15. Available at: <http://www.ncbi.nlm.nih.gov/pubmed/1370176>.

335. Goorin AM, Schwartzentruber DJ, Devidas M, et al. Presurgical chemotherapy compared with immediate surgery and adjuvant chemotherapy for nonmetastatic osteosarcoma: Pediatric Oncology Group Study POG-8651. *J Clin Oncol* 2003;21:1574-1580. Available at: <http://www.ncbi.nlm.nih.gov/pubmed12697883>.

336. Bramwell V, Burgers M, Sneath R, et al. A comparison of two short intensive adjuvant chemotherapy regimens in operable osteosarcoma of limbs in children and young adults: the first study of the European Osteosarcoma Intergroup. *J Clin Oncol* 1992;10:1579-1591. Available at: <http://www.ncbi.nlm.nih.gov/pubmed/1403038>.

337. Souhami RL, Craft AW, Van der Eijken JW, et al. Randomised trial of two regimens of chemotherapy in operable osteosarcoma: a study of the European Osteosarcoma Intergroup. *Lancet* 1997;350:911-917. Available at: <http://www.ncbi.nlm.nih.gov/pubmed/9314869>.

338. Fuchs N, Bielack SS, Epler D, et al. Long-term results of the cooperative German-Austrian-Swiss osteosarcoma study group's protocol COSS-86 of intensive multidrug chemotherapy and surgery for osteosarcoma of the limbs. *Ann Oncol* 1998;9:893-899. Available at: <http://www.ncbi.nlm.nih.gov/pubmed/9789613>.

339. Bacci G, Ferrari S, Bertoni F, et al. Long-term outcome for patients with nonmetastatic osteosarcoma of the extremity treated at the istituto ortopedico rizzoli according to the istituto ortopedico rizzoli/osteosarcoma-2 protocol: an updated report. *J Clin Oncol* 2000;18:4016-4027. Available at: <http://www.ncbi.nlm.nih.gov/pubmed/11118462>.

340. Bacci G, Briccoli A, Ferrari S, et al. Neoadjuvant chemotherapy for osteosarcoma of the extremity: long-term results of the Rizzoli's 4th protocol. *Eur J Cancer* 2001;37:2030-2039. Available at: <http://www.ncbi.nlm.nih.gov/pubmed/11597381>.

341. Ferrari S, Smeland S, Mercuri M, et al. Neoadjuvant chemotherapy with high-dose Ifosfamide, high-dose methotrexate, cisplatin, and doxorubicin for patients with localized osteosarcoma of the extremity: a



joint study by the Italian and Scandinavian Sarcoma Groups. *J Clin Oncol* 2005;23:8845-8852. Available at: <http://www.ncbi.nlm.nih.gov/pubmed/16246977>.

342. Lewis IJ, Nooij MA, Whelan J, et al. Improvement in histologic response but not survival in osteosarcoma patients treated with intensified chemotherapy: a randomized phase III trial of the European Osteosarcoma Intergroup. *J Natl Cancer Inst* 2007;99:112-128. Available at: <http://www.ncbi.nlm.nih.gov/pubmed/17227995>.

343. Meyers PA, Schwartz CL, Krailo MD, et al. Osteosarcoma: the addition of muramyl tripeptide to chemotherapy improves overall survival--a report from the Children's Oncology Group. *J Clin Oncol* 2008;26:633-638. Available at: <http://www.ncbi.nlm.nih.gov/pubmed/18235123>.

344. Basaran M, Bavbek ES, Saglam S, et al. A phase II study of cisplatin, ifosfamide and epirubicin combination chemotherapy in adults with nonmetastatic and extremity osteosarcomas. *Oncology* 2007;72:255-260. Available at: <http://www.ncbi.nlm.nih.gov/pubmed/18185020>.

345. Le Deley MC, Guinebretiere JM, Gentet JC, et al. SFOP OS94: a randomised trial comparing preoperative high-dose methotrexate plus doxorubicin to high-dose methotrexate plus etoposide and ifosfamide in osteosarcoma patients. *Eur J Cancer* 2007;43:752-761. Available at: <http://www.ncbi.nlm.nih.gov/pubmed/17267204>.

346. Provisor AJ, Ettinger LJ, Nachman JB, et al. Treatment of nonmetastatic osteosarcoma of the extremity with preoperative and postoperative chemotherapy: a report from the Children's Cancer Group. *J Clin Oncol* 1997;15:76-84. Available at: <http://www.ncbi.nlm.nih.gov/pubmed/8996127>.

347. Bernthal NM, Federman N, Eilber FR, et al. Long-term results (>25 years) of a randomized, prospective clinical trial evaluating chemotherapy in patients with high-grade, operable osteosarcoma.

Cancer 2012;118:5888-5893. Available at: <http://www.ncbi.nlm.nih.gov/pubmed/22648705>.

348. Bacci G, Mercuri M, Longhi A, et al. Grade of chemotherapy-induced necrosis as a predictor of local and systemic control in 881 patients with non-metastatic osteosarcoma of the extremities treated with neoadjuvant chemotherapy in a single institution. *Eur J Cancer* 2005;41:2079-2085. Available at: <http://www.ncbi.nlm.nih.gov/pubmed/16115755>.

349. Chou AJ, Kleinerman ES, Krailo MD, et al. Addition of muramyl tripeptide to chemotherapy for patients with newly diagnosed metastatic osteosarcoma: a report from the Children's Oncology Group. *Cancer* 2009;115:5339-5348. Available at: <http://www.ncbi.nlm.nih.gov/pubmed/19637348>.

350. Cesari M, Alberghini M, Vanel D, et al. Periosteal osteosarcoma: a single-institution experience. *Cancer* 2011;117:1731-1735. Available at: <http://www.ncbi.nlm.nih.gov/pubmed/21472720>.

351. Grimer RJ, Bielack S, Flege S, et al. Periosteal osteosarcoma--a European review of outcome. *Eur J Cancer* 2005;41:2806-2811. Available at: <http://www.ncbi.nlm.nih.gov/pubmed/16290134>.

352. Bacci G, Ferrari S, Tienghi A, et al. A comparison of methods of loco-regional chemotherapy combined with systemic chemotherapy as neo-adjuvant treatment of osteosarcoma of the extremity. *Eur J Surg Oncol* 2001;27:98-9104. Available at: <http://www.ncbi.nlm.nih.gov/pubmed/11237499>.

353. Winkler K, Beron G, Delling G, et al. Neoadjuvant chemotherapy of osteosarcoma: results of a randomized cooperative trial (COSS-82) with salvage chemotherapy based on histological tumor response. *J Clin Oncol* 1988;6:329-337. Available at: <http://www.ncbi.nlm.nih.gov/pubmed/2448428>.

354. Smeland S, Muller C, Alvegard TA, et al. Scandinavian Sarcoma Group Osteosarcoma Study SSG VIII: prognostic factors for outcome



and the role of replacement salvage chemotherapy for poor histological responders. *Eur J Cancer* 2003;39:488-494. Available at: <http://www.ncbi.nlm.nih.gov/pubmed/12751380>.

355. Smeland S, Bruland OS, Hjorth L, et al. Results of the Scandinavian Sarcoma Group XIV protocol for classical osteosarcoma: 63 patients with a minimum follow-up of 4 years. *Acta Orthop* 2011;82:211-216. Available at: <http://www.ncbi.nlm.nih.gov/pubmed/21434784>.

356. Ferrari S, Ruggieri P, Cefalo G, et al. Neoadjuvant chemotherapy with methotrexate, cisplatin, and doxorubicin with or without ifosfamide in nonmetastatic osteosarcoma of the extremity: An Italian Sarcoma Group trial ISG/OS-1. *J Clin Oncol* 2012;30:2112-2118. Available at: <http://www.ncbi.nlm.nih.gov/pubmed/22564997>.

357. Marina N, Smeland S, Bielack SS, et al. MAPIE vs MAP as Postoperative Chemotherapy in Patients with a Poor Response to Preoperative Chemotherapy For Newly-Diagnosed Osteosarcoma: results from EURAMOS-1 [abstract] [abstract]. Presented at the CTOS 2014; Berlin. 96.

358. Guadagnolo BA, Zagars GK, Raymond AK, et al. Osteosarcoma of the jaw/craniofacial region: outcomes after multimodality treatment. *Cancer* 2009;115:3262-3270. Available at: <http://www.ncbi.nlm.nih.gov/pubmed/19382187>.

359. Bielack SS, Smeland S, Whelan JS, et al. Methotrexate, Doxorubicin, and Cisplatin (MAP) Plus Maintenance Pegylated Interferon Alfa-2b Versus MAP Alone in Patients With Resectable High-Grade Osteosarcoma and Good Histologic Response to Preoperative MAP: First Results of the EURAMOS-1 Good Response Randomized Controlled Trial. *J Clin Oncol* 2015;33:2279-2287. Available at: <http://www.ncbi.nlm.nih.gov/pubmed/26033801>.

360. Ciernik IF, Niemierko A, Harmon DC, et al. Proton-based radiotherapy for unresectable or incompletely resected osteosarcoma.

Cancer 2011;117:4522-4530. Available at: <http://www.ncbi.nlm.nih.gov/pubmed/21448934>.

361. DeLaney TF, Park L, Goldberg SI, et al. Radiotherapy for local control of osteosarcoma. *Int J Radiat Oncol Biol Phys* 2005;61:492-498. Available at: <http://www.ncbi.nlm.nih.gov/pubmed/15667972>.

362. Meyers PA, Heller G, Healey JH, et al. Osteogenic sarcoma with clinically detectable metastasis at initial presentation. *J Clin Oncol* 1993;11:449-453. Available at: <http://www.ncbi.nlm.nih.gov/pubmed/8445419>.

363. Bacci G, Briccoli A, Mercuri M, et al. Osteosarcoma of the extremities with synchronous lung metastases: long-term results in 44 patients treated with neoadjuvant chemotherapy. *J Chemother* 1998;10:69-76. Available at: <http://www.ncbi.nlm.nih.gov/pubmed/9531078>.

364. Bacci G, Briccoli A, Rocca M, et al. Neoadjuvant chemotherapy for osteosarcoma of the extremities with metastases at presentation: recent experience at the Rizzoli Institute in 57 patients treated with cisplatin, doxorubicin, and a high dose of methotrexate and ifosfamide. *Ann Oncol* 2003;14:1126-1134. Available at: <http://www.ncbi.nlm.nih.gov/pubmed/12853357>.

365. Goorin AM, Harris MB, Bernstein M, et al. Phase II/III trial of etoposide and high-dose ifosfamide in newly diagnosed metastatic osteosarcoma: a pediatric oncology group trial. *J Clin Oncol* 2002;20:426-433. Available at: <http://www.ncbi.nlm.nih.gov/pubmed/11786570>.

366. Winkler K, Torggler S, Beron G, et al. [Results of treatment in primary disseminated osteosarcoma. Analysis of the follow-up of patients in the cooperative osteosarcoma studies COSS-80 and COSS-82]. *Onkologie* 1989;12:92-96. Available at: <http://www.ncbi.nlm.nih.gov/pubmed/2660050>.



367. Bacci G, Mercuri M, Briccoli A, et al. Osteogenic sarcoma of the extremity with detectable lung metastases at presentation. Results of treatment of 23 patients with chemotherapy followed by simultaneous resection of primary and metastatic lesions. *Cancer* 1997;79:245-254. Available at: <http://www.ncbi.nlm.nih.gov/pubmed/9010097>.

368. Tabone MD, Kalifa C, Rodary C, et al. Osteosarcoma recurrences in pediatric patients previously treated with intensive chemotherapy. *J Clin Oncol* 1994;12:2614-2620. Available at: <http://www.ncbi.nlm.nih.gov/pubmed/7989936>.

369. Saeter G, Hoie J, Stenwig AE, et al. Systemic relapse of patients with osteogenic sarcoma. Prognostic factors for long term survival. *Cancer* 1995;75:1084-1093. Available at: <http://www.ncbi.nlm.nih.gov/pubmed/7850705>.

370. Ferrari S, Briccoli A, Mercuri M, et al. Postrelapse survival in osteosarcoma of the extremities: prognostic factors for long-term survival. *J Clin Oncol* 2003;21:710-715. Available at: <http://www.ncbi.nlm.nih.gov/pubmed/12586810>.

371. Buddingh EP, Anninga JK, Versteegh MIM, et al. Prognostic factors in pulmonary metastasized high-grade osteosarcoma. *Pediatr Blood Cancer* 2010;54:216-221. Available at: <http://www.ncbi.nlm.nih.gov/pubmed/19890902>.

372. Briccoli A, Rocca M, Salone M, et al. High grade osteosarcoma of the extremities metastatic to the lung: long-term results in 323 patients treated combining surgery and chemotherapy, 1985-2005. *Surg Oncol* 2010;19:193-199. Available at: <http://www.ncbi.nlm.nih.gov/pubmed/19515554>.

373. Daw NC, Chou AJ, Jaffe N, et al. Recurrent osteosarcoma with a single pulmonary metastasis: a multi-institutional review. *Br J Cancer* 2015;112:278-282. Available at: <http://www.ncbi.nlm.nih.gov/pubmed/25422914>.

374. Bielack SS, Kempf-Bielack B, Branscheid D, et al. Second and subsequent recurrences of osteosarcoma: presentation, treatment, and outcomes of 249 consecutive cooperative osteosarcoma study group patients. *J Clin Oncol* 2009;27:557-565. Available at: <http://www.ncbi.nlm.nih.gov/pubmed/19075282>.

375. Berger M, Grignani G, Ferrari S, et al. Phase 2 trial of two courses of cyclophosphamide and etoposide for relapsed high-risk osteosarcoma patients. *Cancer* 2009;115:2980-2987. Available at: <http://www.ncbi.nlm.nih.gov/pubmed/19452540>.

376. Gentet JC, Brunat-Mentigny M, Demaille MC, et al. Ifosfamide and etoposide in childhood osteosarcoma. A phase II study of the French Society of Paediatric Oncology. *Eur J Cancer* 1997;33:232-237. Available at: <http://www.ncbi.nlm.nih.gov/pubmed/9135494>.

377. Merimsky O, Meller I, Flusser G, et al. Gemcitabine in soft tissue or bone sarcoma resistant to standard chemotherapy: a phase II study. *Cancer Chemother Pharmacol* 2000;45:177-181. Available at: <http://www.ncbi.nlm.nih.gov/pubmed/10663634>.

378. Palmerini E, Jones RL, Paioli A, et al. Gemcitabine (G) and docetaxel (D) in relapsed and unresectable high-grade osteosarcoma after failure of standard multimodal therapy [abstract]. *ASCO Meeting Abstracts* 2014;32:10541. Available at: http://meeting.ascopubs.org/cgi/content/abstract/32/15_suppl/10541.

379. Anderson PM, Wiseman GA, Dispenzieri A, et al. High-dose samarium-153 ethylene diamine tetramethylene phosphonate: low toxicity of skeletal irradiation in patients with osteosarcoma and bone metastases. *J Clin Oncol* 2002;20:189-196. Available at: <http://www.ncbi.nlm.nih.gov/pubmed/11773169>.

380. Loeb DM, Garrett-Mayer E, Hobbs RF, et al. Dose-finding study of 153Sm-EDTMP in patients with poor-prognosis osteosarcoma. *Cancer* 2009;115:2514-2522. Available at: <http://www.ncbi.nlm.nih.gov/pubmed/19338063>.



381. Subbiah V, Rohren E, Huh WW, et al. Phase 1 dose escalation trial of intravenous radium 223 dichloride alpha-particle therapy in osteosarcoma. ASCO Meeting Abstracts 2014;32:TPS10600. Available at: http://meeting.ascopubs.org/cgi/content/abstract/32/15_suppl/TPS10600.

382. Subbiah V, Anderson P, Rohren E. Alpha Emitter Radium 223 in High-Risk Osteosarcoma: First Clinical Evidence of Response and Blood-Brain Barrier Penetration. JAMA Oncol 2015;1:253-255. Available at: <http://www.ncbi.nlm.nih.gov/pubmed/26181034>.

383. Anderson PM, Subbiah V, Rohren E. Bone-seeking radiopharmaceuticals as targeted agents of osteosarcoma: samarium-153-EDTMP and radium-223. Adv Exp Med Biol 2014;804:291-304. Available at: <http://www.ncbi.nlm.nih.gov/pubmed/24924181>.

384. Grignani G, Palmerini E, Dileo P, et al. A phase II trial of sorafenib in relapsed and unresectable high-grade osteosarcoma after failure of standard multimodal therapy: an Italian Sarcoma Group study. Ann Oncol 2012;23:508-516. Available at: <http://www.ncbi.nlm.nih.gov/pubmed/21527590>.

385. Grignani G, Palmerini E, Ferraresi V, et al. Sorafenib and everolimus for patients with unresectable high-grade osteosarcoma progressing after standard treatment: a non-randomised phase 2 clinical trial. Lancet Oncol 2015;16:98-107. Available at: <http://www.ncbi.nlm.nih.gov/pubmed/25498219>.

386. Lashkari A, Chow WA, Valdes F, et al. Tandem high-dose chemotherapy followed by autologous transplantation in patients with locally advanced or metastatic sarcoma. Anticancer Res 2009;29:3281-3288. Available at: <http://www.ncbi.nlm.nih.gov/pubmed/19661346>.

387. Fagioli F, Aglietta M, Tienghi A, et al. High-dose chemotherapy in the treatment of relapsed osteosarcoma: an Italian sarcoma group study. J Clin Oncol 2002;20:2150-2156. Available at: <http://www.ncbi.nlm.nih.gov/pubmed/11956277>.

388. Papagelopoulos PJ, Galanis EC, Sim FH, Unni KK. Clinicopathologic features, diagnosis, and treatment of malignant fibrous histiocytoma of bone. Orthopedics 2000;23:59-65; quiz 66-57. Available at: <http://www.ncbi.nlm.nih.gov/pubmed/10642003>.

389. Bacci G, Avella M, Picci P, et al. Primary chemotherapy and delayed surgery for malignant fibrous histiocytoma of bone in the extremity. Tumori 1990;76:537-542. Available at: <http://www.ncbi.nlm.nih.gov/pubmed/2178284>.

390. Bacci G, Picci P, Mercuri M, et al. Neoadjuvant chemotherapy for high grade malignant fibrous histiocytoma of bone. Clin Orthop Relat Res 1998:178-189. Available at: <http://www.ncbi.nlm.nih.gov/pubmed/9577426>.

391. Bramwell VH, Steward WP, Nooij M, et al. Neoadjuvant chemotherapy with doxorubicin and cisplatin in malignant fibrous histiocytoma of bone: A European Osteosarcoma Intergroup study. J Clin Oncol 1999;17:3260-3269. Available at: <http://www.ncbi.nlm.nih.gov/pubmed/10506628>.